

Eosinophilic Cellulitis in a Patient with Gastric Cancer

Hei Sung Kim, Min Ju Kang, Hyung-Ok Kim and Young Min Park*

Department of Dermatology, Seoul St Mary's Hospital, The Catholic University of Korea, #505 Banpo-dong, Seocho-gu, Seoul 137-701, Korea.

*E-mail: yymmpark6301@hotmail.com

Accepted April 30, 2009.

Sir,

Eosinophilic cellulitis (EC) is an inflammatory dermatosis characterized by marked eosinophilic infiltrates in the dermis. Thus far, few cases have been described in association with non-haematological malignancies (1–4). We report here a case of EC that developed in a patient with advanced gastric cancer.

CASE REPORT

A 34-year-old woman presented with a 2-week history of a pruritic, erythematous rash, which had developed rapidly over the abdomen. In July 2007, curative subtotal gastrectomy and lymph node dissection were performed for advanced gastric cancer (T3N1M0). One month after surgery, she underwent 6 cycles of chemotherapy with cisplatin and 5-fluorouracil.

In July 2008, she was referred to our department with a solitary eczematoid skin lesion on the right lower quadrant of the trunk, where a drain had been inserted previously. A skin biopsy of the solitary lesion revealed a poorly differentiated tubular adenocarcinoma with signet ring cell features, consistent with metastatic carcinoma from the stomach. A computerized tomography scan in September 2008 showed multiple seeding nodules along the umbilical pre-vesical fascia, both fallopian tubes and the right lateral abdominal wall.

The current rash, of 2 weeks duration, consisted of multiple annular erythematous plaques with central areas of regression and peripheral wheals (Fig. 1). To

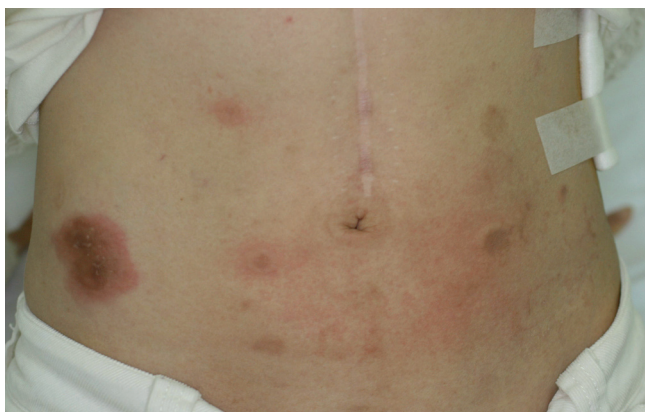

Fig. 1. Multiple pruritic annular plaques with central areas of regression. Wheals are present on the periphery. The largest plaque on the right side is a cancer metastasis confirmed from a previous biopsy.

evaluate the possibility of metastatic carcinoma, we performed a punch biopsy from a representative skin lesion. Histology showed intense eosinophil infiltration with flame figures in the dermis, findings that were suggestive of EC (Fig. 2). Haematological investigation revealed marked eosinophilia: $0.6 \times 10^9 \text{ l}^{-1}$ (normal $0.03\text{--}0.06 \times 10^9 \text{ l}^{-1}$).

While the rash was being evaluated, the patient complained of newly developed back pain. Magnetic resonance imaging revealed multiple bone metastases involving the whole lumbar spine, sacrum, and ilium. The patient received a series of palliative external radiation treatments (30 Gy/10fx, L2–S2). Steroid injections (hydrocortisone 100 mg/day for 5 days, intravenously), given as a pre-treatment regimen, dramatically improved the pruritus and skin manifestations.

DISCUSSION

EC was originally described as a distinct disease by Wells in 1971. Since then, various forms of EC with urticarial, vesiculo-bullous, nodular, papulonodular and semicircular lesions have been described (5–7).

The clinical features of our case resembled those of erythema multiforme, urticarial vasculitis, and erythema annulare centrifugum and hence required differentiation. Urticarial vasculitis is clinically similar to EC, but histologically it exhibits vasculitis, which was absent in

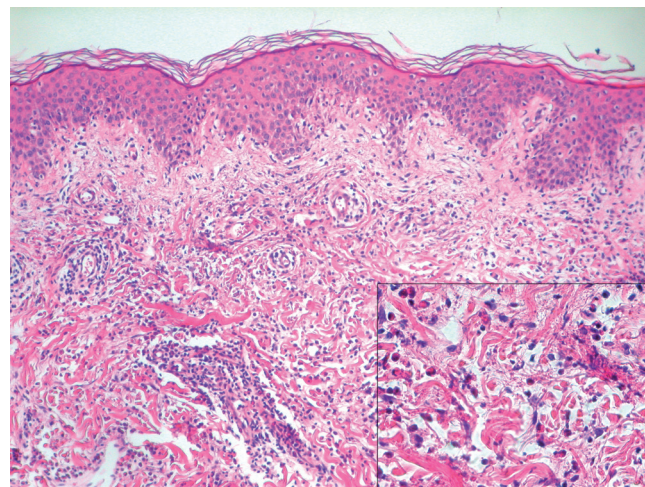


Fig. 2. Histology shows a marked eosinophil infiltration in the dermis. Flame figures are seen (haematoxylin and eosin, $\times 200$ (inset $\times 400$)).

our case. The vast majority of patients with erythema multiforme have a history of herpetic infection and oral involvement, which our patient lacked. Furthermore, heavy eosinophilic infiltrates and flame figures are not the usual findings of erythema multiforme. Erythema annulare centrifugum is another disease that must be considered, but it normally has scales at the inner border and does not show flame figures histologically.

Our case was unique in its presentation, with targetoid lesions distributed solely on the trunk. There has been one report of EC with semicircular plaques at the borders of previous post-inflammatory hyperpigmented macules (7), but to our knowledge, erythema multiforme-like EC has not been reported previously. Our patient is the second with adenocarcinoma, and the first with gastric cancer who has also been reported to have EC. We believe that gastric cancer may have been the triggering factor and suggest that an underlying malignancy should be considered in patients presenting with this condition.

REFERENCES

1. Brehmer-Andersson E, Kaaman T, Skog E, Frithz A. The histopathogenesis of the flame figure in Well's syndrome based on five cases. *Acta Derm Venereol* 1986; 66: 213–219.
2. Hirsch K, Ludwig RJ, Wolter M, Zollner TM, Hardt K, Kaufmann R, et al. Eosinophilic cellulitis (Well's syndrome) associated with colon carcinoma. *J Dtsch Dermatol Ges* 2005; 3: 530–531.
3. Farrar CW, Guerin DM, Wilson NJ. Eosinophilic cellulitis associated with squamous cell carcinoma of the bronchus. *Br J Dermatol* 2001; 145: 678–679.
4. Murray D, Eady RA. Migratory erythema and eosinophilic cellulitis associated with nasopharyngeal carcinoma. *J R Soc Med* 1981; 74: 845–847.
5. Consigny S, Courville P, Young P, Richard C, Gauthier V, Maillard V, et al. Histological and clinical forms of eosinophilic cellulitis. *Ann Dermatol Venereol* 2001; 128: 105–114.
6. Ghislain PD, Van Eeckhout P. Eosinophilic cellulitis of papulonodular presentation (Well's syndrome). *J Eur Acad Dermatol Venereol* 2005; 19: 226–227.
7. Karabudak O, Dogan B, Taskapan O, Harmanyeri Y. Eosinophilic cellulitis presented with semicircular pattern. *J Dermatol* 2006; 33: 798–801.