

Valsartan-induced Drug Eruption Followed by CD30+ Pseudolymphomatous Eruption

Yu Sawada, Ryutaro Yoshiki, Chika Kawakami, Shoko Fukamachi, Kazunari Sugita, Motonobu Nakamura and Yoshiaki Tokura

Department of Dermatology, University of Occupational and Environmental Health, 1-1 Iseigaoka, Yahatanishi-ku, 807-8555 Kitakyushu, Japan.

E-mail: long-ago@med.uoeh-u.ac.jp

Accepted May 18, 2009.

Although the causes of CD30+ pseudolymphoma are unclear in most cases, drugs are one of the causative agents for this skin eruption, as represented by amlodipine (1), carbamazepine (2) and other drugs. Here, we report a patient with a maculopapular drug eruption to valsartan, an angiotensin II receptor 1 antagonist, which was followed by the development of CD30+ pseudolymphomatous lesions.

CASE REPORT

An 80-year-old Japanese man presented with a generalized maculopapular eruption. Two months previously he had begun taking valsartan (40 mg daily) for his hypertension. Two weeks after administration of the drug, he developed a rash on the trunk and all four limbs. The patient was seen by a private dermatologist and was administered with an antihistamine with no therapeutic effect. He was referred to us for evaluation of his eruption.

On examination, multiple, pruritic, erythematous macules and papules were present on his chest, back and extremities (Fig. 1A and B). Laboratory examina-

tion revealed that leukocyte count was 7100/ μ l with eosinophilia (1590/ μ l, 22.4%; normal, 1–5%). There were no circulating atypical lymphocytes. Biochemical profiles showed renal dysfunction with high values of serum creatinine, 1.46 mg/dl (normal, 0.6–1.1 mg/dl); blood urea nitrogen, 26 mg/dl (normal, 8–22 mg/dl); and hyperkalaemia, 5.1 mEq/l (normal, 3.6–4.9 mEq/l). Other values, including hepatic enzymes, were within normal ranges. A skin biopsy specimen taken from his abdomen revealed an infiltrate of lymphocytes in the upper dermis, intermingled with eosinophils (Fig. 2A). We performed immunohistochemistry of this biopsy, but CD30+ cells were not seen. We performed lymphocyte stimulation test with valsartan, as reported previously (1, 2), and found that 3 H-thymidine incorporation was significantly increased by ≥ 5 ng/ml of the drug. Based on the clinical course and lymphocyte stimulation test, we diagnosed the rash as drug eruption due to valsartan.

The intake of valsartan was discontinued, and he was treated with oral prednisolone (30 mg daily) and topical betamethasone butyrate propionate ointment. The maculopapules were remarkably improved in a week, and prednisolone was tapered over the next 2 weeks. During the next 4 months residual faint erythematous

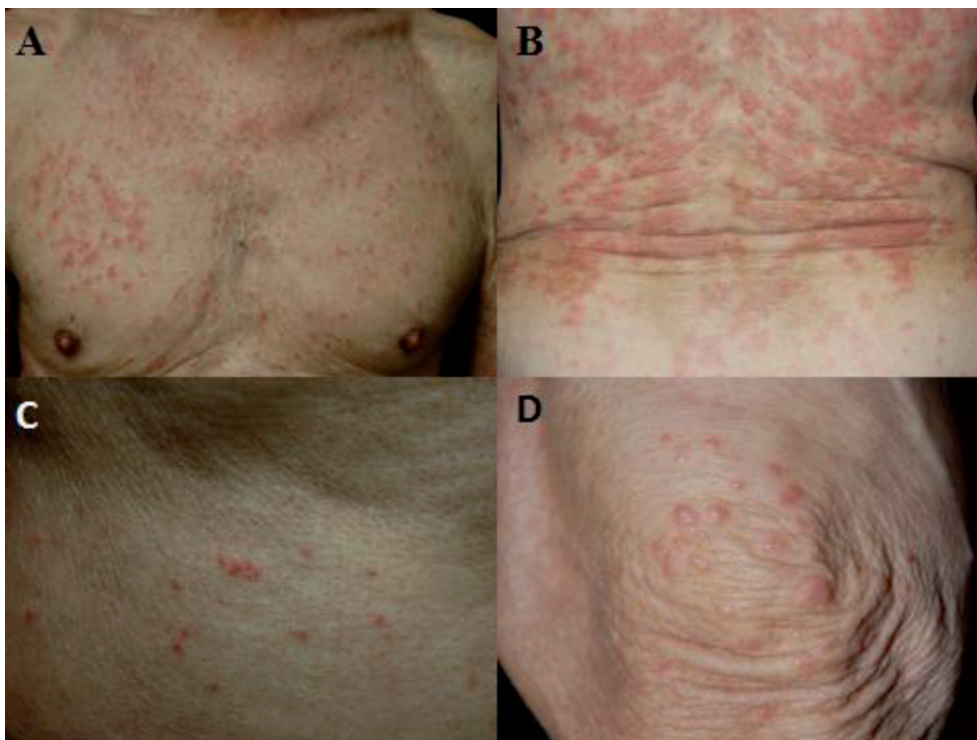


Fig. 1. Clinical features. At the initial eruption, diagnosed as toxicoderma, multiple, pruritic, erythematous macules and papules were present on his chest (A) and back (B). At the subsequent eruption, diagnosed as pseudolymphoma, erythematous solid papules occurred on the back (C) and legs (D).

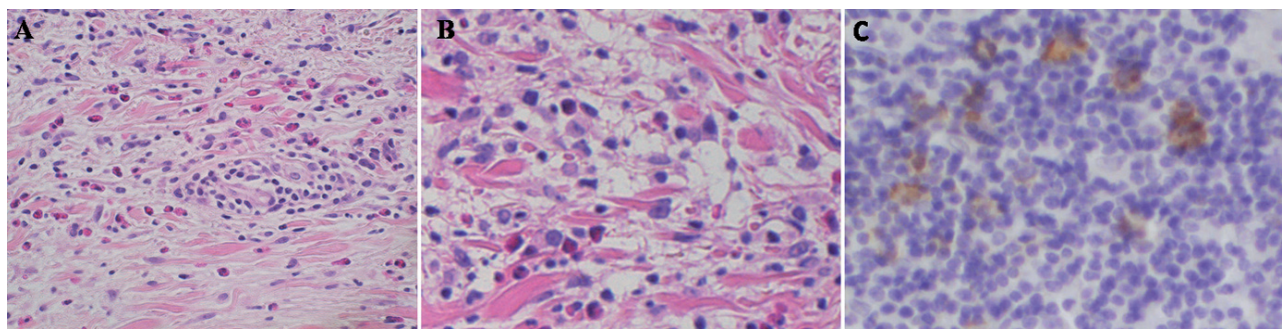


Fig. 2. Histopathological pictures. (A) Initial eruption. Skin biopsy revealed an infiltrate of lymphocytes in the upper dermis, intermingled with eosinophils (haematoxylin and eosin; original magnification, $\times 400$). (B, C) Subsequent eruption. Cell having large nuclei with prominent nucleoli infiltrate in the upper dermis (B: haematoxylin and eosin; original magnification, $\times 400$). The infiltrate consists of CD30+ cells by immunohistochemistry (C: original magnification, $\times 400$).

macules continued at a low level. However, a generalized but different type of eruption re-emerged on his abdomen, back, and extremities (Fig. 1C and D). The individual papular lesions were more solid than those of the previous eruption. A skin biopsy specimen taken from a papular lesion revealed a massive infiltrate of lymphocytes, some of which had large nuclei with prominent nucleoli in the upper and middle dermis (Fig. 2B). The infiltrate was intermingled with eosinophils. An immunohistochemical study demonstrated that CD4+ cells outnumbered CD8+ cells, and notably, large atypical cells expressed CD30 (Fig. 2C). We diagnosed the eruption as CD30+ pseudolymphoma, following valsartan drug eruption, or as lymphomatoid papulosis. The patient was treated with narrowband ultraviolet B light irradiation (800 mJ/cm², once a week for 14 weeks) without re-administration of prednisolone. The eruption subsided gradually in 4 weeks. Currently, 2 months after the cessation of therapy, no skin lesions have recurred.

DISCUSSION

The well-known adverse effects of valsartan are dizziness, abdominal pain and cough. The cutaneous reactions are less frequent, but urticaria or angioedema (3) and mucocutaneous bullous pemphigoid (4) have been reported. In our patient, a maculopapular eruption initially occurred in response to valsartan. This common type of drug eruption was improved by discontinuation of the causative drug and administration of prednisolone. After a 4-month remission of the eruption, however, he developed an eruption, which was different from the antecedent rash. The newly developed eruption had solid papular appearance and histological presence of CD30+ large atypical cells. Lymphomatoid papulosis may be a differential diagnosis, but the eruption did not recur after the successful treatment with narrowband

UVB therapy. Pseudolymphoma is one of the manifestations of drug eruptions (1, 2, 5). There have been several reports of CD30+ pseudolymphoma caused by drugs (1, 2). Only one case of valsartan-induced pseudolymphoma was documented, although CD30 positivity was not examined (6).

The relationship between the initial drug eruption and the subsequent pseudolymphomatous eruption is unclear in our case. However, considering the presence of preceding drug eruption and the apparent reactivity of patient's peripheral lymphocytes to valsartan strongly suggests that the pseudolymphomatous eruption developed as a consequence of sensitization with the drug and subsequent hyper-reaction with the drug. It is tempting to speculate that valsartan-reactive T cells were overstimulated during the clinical course and led to the pseudolymphoma after a long incubation period.

REFERENCES

1. Kabashima R, Orimo H, Hino R, Nakashima D, Kabashima K, Tokura Y. CD-30-positive T-cell pseudolymphoma induced by amlodipine. *J Eur Acad Dermatol Venereol* 2008; 22: 1522–1524.
2. Fukamachi S, Sugita K, Sawada Y, Bito T, Nakamura M, Tokura Y. Drug-induced CD 30+ T cell pseudolymphoma: case report and review of the literature. *Eur J Dermatol* 2009; 19: 292–294.
3. de la Serna Higuera C. Angio-edema and urticarial reaction induced by valsartan. *Med Clin* 2000; 114: 599.
4. Femiano F. Mucocutaneous bullous pemphigoid induced by valsartan. A clinical case. *Minerva Stomatol* 2003; 52: 187–190.
5. Kardaun SH, Scheffer E, Vermeer BJ. Drug-induced pseudolymphomatous skin reactions. *Br J Dermatol* 1988; 118: 545–552.
6. Mustasim DF. Lymphomatoid drug eruption mimicking digitate dermatosis: cross reactivity between two drugs that suppress angiotensin II function. *Am J Dermatopathol* 2003; 25: 331–334.