

Severe Rosacea in a Patient on Infliximab for Ulcerative Colitis: Pathophysiological Considerations

Maria Kosmidou¹, Georgios Gaitanis², Katon Nomikos², Aikaterini Zioga³, Konstantinos Katsanos¹, Ioannis D. Bassukas^{2*} and Epameinondas Tsianos¹

¹First Division of Internal Medicine and Hepato-Gastroenterology Unit, ²Department of Skin & Venereal Diseases, ³Department of Pathology, University of Ioannina Medical School and University Hospital, GR-45110 Ioannina, Greece. *E-mail: ibassuka@cc.uoi.gr

Accepted March 16, 2009.

Sir,

Skin is frequently involved in adverse reactions to infliximab, a safe and generally well tolerated treatment modality for patients with inflammatory bowel diseases (IBD) (1, 2). Rosacea, with a prevalence of 1.5–10% among adults over 30 years old, is a common, chronically-persistent inflammatory skin disease (3, 4), yet it has been rarely described as an adverse drug event, notably only in connection with amiodorone, nicotinic acid (niacin, vitamin B3), high doses of vitamins B6 and B12 (5) and recently with the tumour necrosis factor (TNF)- α receptor antagonist etanercept (6).

We describe here the development and management of severe rosacea in a patient being treated with infliximab for ulcerative colitis (UC).

CASE REPORT

A 61-year-old man with no history of previous skin diseases, presented with an inadequately controlled UC despite ongoing therapy with prednisone, azathioprine and mesalazine. Infliximab (Remicade, Centecor) was introduced (5 mg/kg body weight at weeks 0, 2, 6 and every 8 weeks thereafter) with parallel glucocorticoid discontinuation after tapering one month before the third infliximab dose.

During the first infliximab infusion the patient developed mild flushing, nausea and headache, corresponding to an acute TNF- α infusion reaction, which subsided on antihistamines. The second infusion was tolerated without treatment-related morbidity. However, beginning at day three after the third infusion he complained of persistent facial erythema with intermittent skin burning and stinging, which aggravated upon exposure to heat or sunlight. Clinical examination revealed erythema, disseminated small papules and occasional pustules, as well as fields of telangiectasia on the face and neck that largely spared the periocular skin (Fig. 1). A skin biopsy was suggestive of rosacea (Fig. 1). He was treated

with doxycycline (100 mg once daily) and propranolol (20 mg orally, three times per day) with concomitant subsidence of his skin symptoms and lesions. On the second day after the fourth infliximab dose he experienced an aggravation of the same symptoms, which lasted for two days and resolved without any treatment modification. Subsequent infliximab applications were all well tolerated and treatment for rosacea was discontinued 6 months after its start. Fifteen months after introduction of infliximab in combination with azathioprine (150 mg daily orally) UC remains in stable remission, and the skin symptoms have not recurred.

DISCUSSION

History, clinical and histopathological picture, and the course of the present disease set the diagnosis of infliximab-associated severe, "grade 3" papulopustular rosacea (4) with episodes of disease aggravation headed by flushing attacks that followed infliximab infusions with a time lag of 2–3 days (adverse drug reaction (ADR) of a delayed type to infliximab). Flushing attacks are a pivotal sign of all forms of rosacea (3). "Niacin-like" flushing reactions often complicate infliximab infusions (7), yet the latter differ from those seen in the present patient because they are always of immediate type. Although nightly attacks induced by vasoactive agents are a characteristic finding of cluster headache the affliction of this patient was not unilateral, the attacks were not accompanied by autonomic features except of flushing, and the episodes presently lasted for many days as opposed to minutes or a few hours in the case of cluster headaches (8).

Many facts support the linkage of rosacea to infliximab in the present case: Rosacea became manifest after the onset of the treatment and the initial flushing attacks progressed under continued infliximab use to

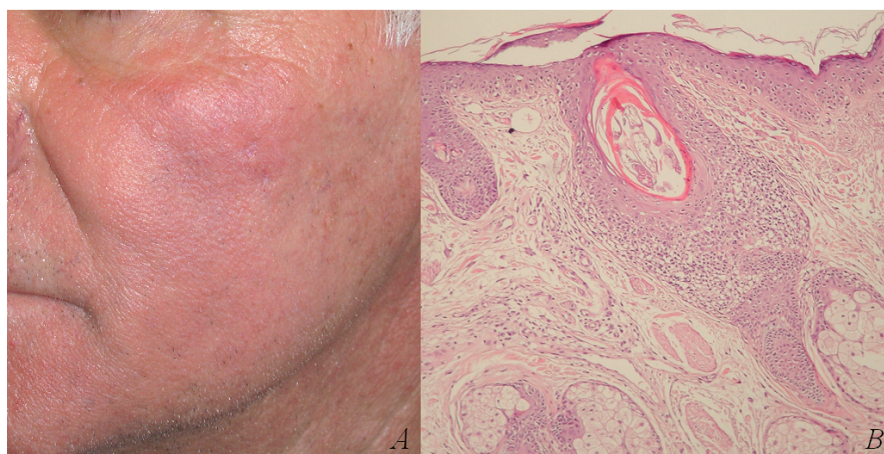


Fig. 1. (A) Clinical presentation one week after the third infliximab infusion (left cheek): Confluent inflammatory papules and isolated small pustules on disseminated erythema with prominent telangiectasias. (B) Skin biopsy one week after the third infliximab infusion (right cheek): Slight spongiosis, intrafollicular pustule, perifollicular lymphohistiocytic infiltrate, Demodex mites within an inflamed hair follicle and telangiectasias in the oedematous interfollicular dermis. Haematoxylin-eosin; original magnification $\times 100$.

develop the full picture of rosacea. The exacerbation following the fourth infusion is in accordance with a re-challenge phenomenon. The symptoms subsided under rosacea-directed therapy. Previous treatments, including corticosteroids, had been used for a long time before the onset of the skin disease. Although severe fulminating rosacea conglobata has been reported occasionally in patients with UC (9), rosacea is not a recognized cutaneous UC comorbidity. Yet a relatively high incidence of rosacea among patients under treatment for IBD (7/47 patients) was reported recently (2). Notably the course of rosacea in the present case is quite similar to that recently described in a patient with psoriasis being treated with etanercept (6). Taking the aforementioned data together, a linkage of the observed ADR to treatment with infliximab can be established at a probability level of 82–92% (total score 1.5–2.5, evidence level "likely"; Table I) (10). In conclusion, although a rather exceptional event, induction of severe rosacea seems to be a characteristic, still probably under-recognized "class" ADR of the anti-TNF- α therapy.

The mechanism by which infliximab induces rosacea may be complex. Exacerbation of innate skin immunity induced by symbiotic or commensal species-associated antigens and/or increased levels of intracutaneous cathelicidins have recently been implicated in the pathogenesis of rosacea (3, 11, 12). According to this concept treatment with infliximab may have elicited rosacea by two possibly inter-related mechanisms (i) promotion of *Demodex* colonization of the face and (ii) direct cathelicidin agonism. (ad i) Colonization of the skin by increasing numbers of follicular mites of the genus *Demodex* seems to play a crucial role in the pathogenesis of rosacea (11) and expanding commensally mite populations have been observed as a consequence of skin immune dysfunction of different aetiologies (13). (ad ii) The possibility that anti-TNF- α regimens exert direct cathelicidin agonism is also supported by experimental data that implicate cathelicidins in the regulation of TNF- α activity. Human cathelicidin LL-37 suppresses LPS-induced TNF- α production (14), whereas, in turn, TNF- α promotes LL-37 expression (15). Thus, exacerbation of rosacea by infliximab may be

interpreted as a phenocopy of the agonistic anti-TNF- α action of cathelicidins at the tissue level. Finally, the genetic background of the patients may also affect their susceptibility to develop this specific ADR (9), thus explaining why severe rosacea remains a rather infrequent adverse event despite the widespread use of anti-TNF- α regimens to treat patients with IBDs.

The authors declare no conflicts of interest.

REFERENCES

- Sandborn WJ. Current directions in IBD therapy: what goals are feasible with biological modifiers? *Gastroenterology* 2008; 135: 1442–1447.
- Passarini B, Infusimo SD, Barbieri E, Varotti E, Gionchetti P, Rizzello F, et al. Cutaneous manifestation in inflammatory bowel diseases: eight cases of psoriasis induced by anti-tumor-necrosis-factor antibody therapy. *Dermatology* 2007; 215: 295–300.
- Crowford G, Pelle MT, James W. Rosacea: I. Etiology, pathogenesis, and subtype classification. *J Am Acad Dermatol* 2004; 51: 327–341.
- Wilkin J, Dahl M, Detmar M, Drake L, Liang MH, Odom R, et al. Standard grading system for rosacea: report of the National Rosacea Society Expert Committee on the Classification and Staging of Rosacea. *J Am Acad Dermatol* 2004; 50: 907–912.
- Jansen T, Romiti R, Kreuter A, Altmeyer P. Rosacea fulminans triggered by high-dose vitamins B6 and B12. *J Eur Acad Dermatol Venereol* 2001; 15: 484–485.
- Winter UM, Treudler R, Paasch U, Sticherling M, Simon JC. Ein Fall von granulomatöser Rosazea im zeitlichen Zusammenhang mit Etanercept. *Hautarzt* 2008; 59: 724–727.
- Becker M, Rosé CD, McIlvain-Simpson G. Niacin-like reaction to infliximab in systemic juvenile rheumatoid arthritis. *J Rheumatol* 2004; 31: 2529–2530.
- May A. Cluster headache: pathogenesis, diagnosis, and management. *Lancet* 2005; 366: 843–855.
- Van Steensel MA, Badeloe S, Winnepenninckx V, Vreeburg M, Steijlen PM, Van Geel M. Granulomatous rosacea and Crohn's disease in a patient homozygous for the Crohn-associated NOD2/CARD15 polymorphism R702W. *Exp Dermatol* 2008; 17: 1057–1058.
- Arimone Y, Bégau B, Miremont-Salamé G, Fourrier-Réglat A, Molimard M, Moore N, Haramburu F. A new method for assessing drug causation provided agreement with experts' judgment. *J Clin Epidemiol* 2006; 59: 308–314.
- Yamasaki K, Di Nardo A, Bardan A, Murakami M, Ohtake T, Coda A, et al. Increase serine protease activity and cathelicidin promotes skin inflammation in rosacea. *Nat Med* 2007; 13: 975–980.
- Lacey N, Delaney S, Kavanagh K, Powell FC. Mite-related bacterial antigens stimulate inflammatory cells in rosacea. *Br J Dermatol* 2007; 157: 474–481.
- Yagdiran Düzgün O, Aytakin S. Comparison of *Demodex* folliculorum density in haemodialysis patients with a control group. *J Eur Acad Dermatol Venereol* 2007; 21: 480–483.
- Mookherjee N, Wilson HL, Doria S, Popowych Y, Falsafi R, Yu JJ, et al. Bovine and human cathelicidin cationic host defense peptides similarly suppress transcriptional responses to bacterial lipopolysaccharides. *J Leukocyt Biol* 2006; 80: 1563–1574.
- Bowdish DM, Davidson DJ, Lau YE, Lee K, Scott MG, Hancock REW. Impact of LL-37 on anti-infective immunity. *J Leukocyt Biol* 2005; 77: 451–459.

Table I. Analysis of the criteria and probability of infliximab causation of rosacea according to the system of Arimone et al. (10)

Criteria	Evidence	Score
Time to onset	Suggestive to highly suggestive	0.5–1
De-challenge	Not conclusive to suggestive	0–0.5
Re-challenge	Positive	0.5
Non-drug related causes	Possible	0
Reactions at site of application	Not available	0
Previous reports of similar drug reactions	Available (ref 2)	0.5
Total score		1.5–2.5
Probability of infliximab causation		82–92%