

Benign Symmetric Lipomatosis Associated with Atopic Dermatitis and Chronic Alcohol Abuse in a Japanese Man

Tamihiro Kawakami, Sora Takeuchi and Yoshinao Soma

Department of Dermatology, St Marianna University School of Medicine, 2-16-1 Sugao, Miyamae-ku, Kawasaki, Kanagawa 216-8511, Japan.

E-mail: tami@marianna-u.ac.jp

Accepted March 26, 2009.

Sir,

Benign symmetric lipomatosis is a rare form of multiple, symmetrical fat distribution. The disorder was first described by Brodie in 1846. It was subsequently characterized by Madelung in 1888 and Launois & Bensaude in 1898 (for review see ref 1). Histologically, cells in the abnormal lipomatous areas are indistinguishable from those in normal fat (2).

CASE REPORT

A 38-year-old Japanese man presented with a great growth of fatty accumulations in the neck, upper trunk, and upper extremities. He first noticed the accumulation 5 years earlier, but did not get it checked. He also had a 15-year history of atopic dermatitis (AD), presenting as intractable itching. The patient had common diagnostic features of AD. He had been drinking Japanese rice wine (sake) for 23 years, with an average daily intake of 540 ml. There was no history of liver disease or other systemic diseases, nor was there any family history of similar problems. Clinical examination revealed multiple, lobulated, fatty-feeling masses distributed symmetrically on the neck, shoulders, upper trunk, and proximal upper extremities. On palpation, the subcutaneous fat was firm and elastic. The overlying epidermis showed diffuse, scaly erythema and lichenification with post-inflammatory

hyperpigmentation (Fig. 1). The legs and lower part of the trunk were spared. Physical examination findings were normal, except for the abnormal distribution of fat and pruritus due to AD. Histological examination of a skin biopsy obtained from the mass in his back revealed a diffuse proliferation of normal adipose tissue in the subcutaneous fat, with a slight increase in fibrous and vascular elements. No distinct capsule was identified and no atypical cells were seen (Fig. 2).

Complete blood counts were normal. A liver function test showed isolated elevation of γ -glutamyl transpeptidase of 88 IU/l (normal, 4–36 IU/l). These changes were secondary to the chronic alcoholism. Fasting urate, blood sugar, triglyceride, and uric acid were all within normal limits. Laboratory parameters of glucose metabolism were also normal. Total serum immunoglobulin E (IgE) was 15,000 IU/ml (normal 0–170 IU/ml). Specific IgE positivity was assessed by radioallergosorbent test (RAST; UniCAP, Pharmacia Diagnostics, Uppsala, Sweden). The patient was positive for five aeroallergens according to RAST testing. His serum RAST for house dust and dust mite-specific IgE was class 6, strongly positive (more than 100 UA/ml; normal, less than 0.34 UA/ml, respectively). Chest roentgenogram was normal. Magnetic resonance imaging showed a symmetrical swelling of the well-demarcated subcutaneous fat tissue in his proximal upper extremities

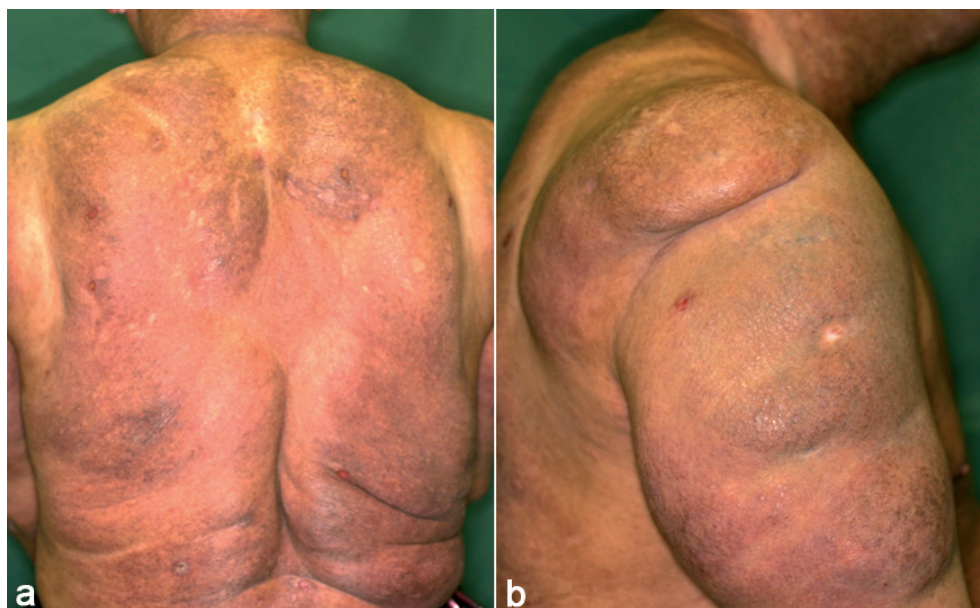

Fig. 1. Large symmetrical lipid deposits of soft and spongy consistency and diffuse scaling erythematous lesions with lichenification in: (a) the back; (b) shoulders and proximal upper extremities.

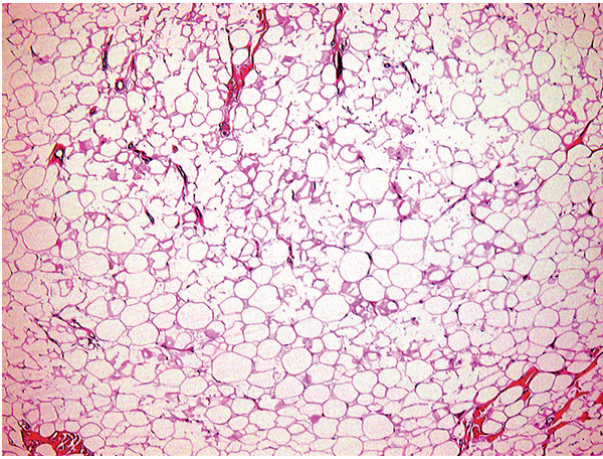


Fig. 2. Microscopic findings of skin biopsy showed diffuse proliferation of normal adipose tissue with a slight increase in fibrous and vascular elements in the subcutaneous fat (haematoxylin and eosin $\times 40$).

(Fig. 3). He was diagnosed as having benign symmetric lipomatosis associated with AD based on these findings. We proposed liposuction or lipectomies, as is the recommended approach for this kind of disease, to reduce the adipose mass.

DISCUSSION

Although several hypotheses concerning benign symmetric lipomatosis have been postulated, many have suggested that the aetiology is closely related to alcoholic abuse-induced metabolic disorder (3). Our patient presented with chronic alcohol abuse without associated metabolic disorder. He presented with chronic AD and accompanying intractable pruritus. In addition, he showed an increase in total serum IgE concentration. AD is an allergic skin disease characterized by an elevation of circulating specific IgE antibodies to environmental allergens. Multiple studies have indicated the role of IgE-reactive autoantigens in AD. Chronic alcoholism is associated with increased total serum IgE levels. Alcohol consumption above a certain threshold is associated with an increase in total serum IgE levels (4, 5). Similarly, alcohol intake may be associated with allergic (IgE-mediated) sensitization to environmental allergens. The mechanism by which alcohol can influence IgE response is not entirely known, but further developments in this area could increase understanding of both allergic diseases and alcohol-induced alterations in the immune system (6). AD is a multifactorial disease and its pathophysiology has been linked to immunological mechanisms demon-

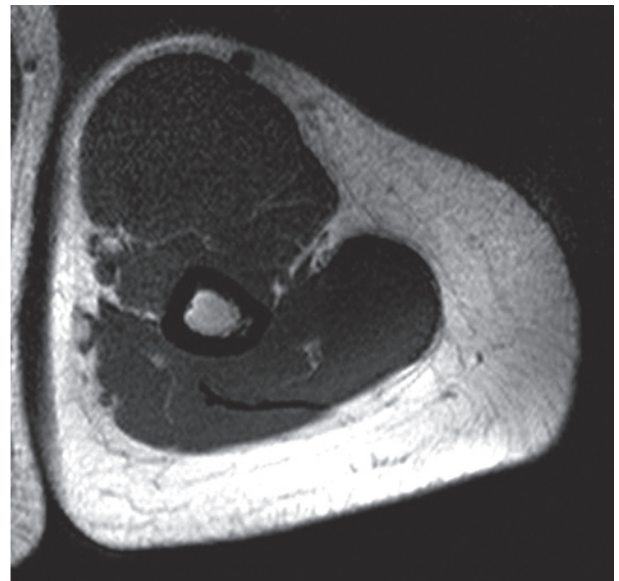


Fig. 3. Magnetic resonance imaging revealed marked, symmetrical accumulation of subcutaneous fatty masses in the left proximal upper extremity.

strated by immunoglobulin profiles. The association between AD and chronic alcoholism in the present patient could indicate a relationship between benign symmetric lipomatosis and a high titre of IgE.

The authors declare no conflicts of interest.

REFERENCES

- González-García R, Rodríguez-Campo FJ, Sastre-Pérez J, Muñoz-Guerra MF. Benign symmetric lipomatosis (Madelung's disease): case reports and current management. *Aesthetic Plast Surg* 2004; 28: 108–112.
- Lopez-Ceres A, Aguilar-Lizarralde Y, Villalobos Sánchez A, Prieto Sánchez E, Valiente Alvarez A. Benign symmetric lipomatosis of the tongue in Madelung's disease. *J Cranio-maxillofac Surg* 2006; 34: 489–493.
- Goetze S, Hommann M, Elsner P, Kaatz M. Induction of benign symmetric lipomatosis (Launois-Bensaude syndrome) in a female patient after liver transplantation. *Dermatology* 2008; 216: 337–340.
- González-Quintela A, Gude F, Boquete O, Rey J, Meijide LM, Suarez F, et al. Association of alcohol consumption with total serum immunoglobulin E levels and allergic sensitization in an adult population-based survey. *Clin Exp Allergy* 2003; 33: 199–205.
- Linneberg A, Petersen J, Nielsen NH, Madsen F, Frølund L, Dirksen A, et al. The relationship of alcohol consumption to total immunoglobulin E and the development of immunoglobulin E sensitization: the Copenhagen Allergy Study. *Clin Exp Allergy* 2003; 33: 192–198.
- Gonzalez-Quintela A, Vidal C, Gude F. Alcohol, IgE and allergy. *Addict Biol* 2004; 9: 195–204.