

## Petrified Ear – A Case of Calcinosis Cutis

Elena Vargas Laguna, Antonio Aguilar Martinez and Fernando Burgos

Department of Dermatology, Hospital Severo Ochoa, Avd/ Orellaneda s.n, Leganés, Madrid, Spain. E-mail: elena\_vargaslaguna@hotmail.com

Accepted March 4, 2009.

Sir,

Petrified ear is an uncommon cutaneous disorder, characterized clinically by marked rigidity of the ear, making it difficult to fold manually. Patients are usually asymptomatic, but some experience a degree of discomfort. The condition occurs following either calcification or, more rarely, ossification of the auricular cartilage secondary to local and environmental injury or to a range of systemic diseases with elevated serum levels of calcium and phosphorus.

### CASE REPORT

A 65-year-old Caucasian man was seen in our clinic in July 2005 with progressive and gradual stiffening of his right ear, which had developed over the past 10 years. His condition was asymptomatic except for difficulty cleaning his ear.

The patient denied any history of frostbite or trauma, but reported that the stiffening process had begun following a wasp bite 5 years previously. His family history was not contributory.

On examination, the external right ear had a normal appearance and configuration. However, the cartilage was hard and rigid and it was difficult to fold the ear manually (Fig. 1a). His left ear was clinically normal. No others cutaneous or systemic findings were observed on general examination.

The results of laboratory testing, including complete blood cell count, biochemistry, serum calcium and phosphorus levels, alkaline phosphatase, parathyroid and thyroid function tests were within normal limits. A radiograph of the external ears revealed calcification of the auricular cartilage in both ears, which was more evident in the right ear (Fig. 1b). A specimen biopsy was taken from the right ear and revealed calcification of the degenerated cartilage without foci of ossification.

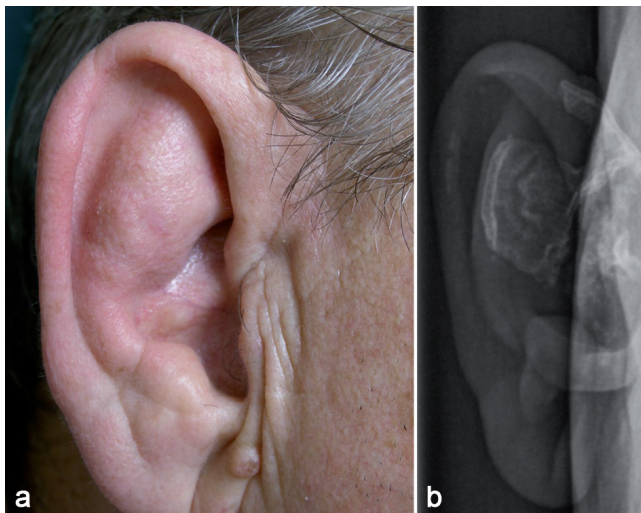


Fig. 1. (a) Petrified right ear with normal external appearance. (b) Radiograph of the external ear revealing calcification of the auricular cartilage.

### DISCUSSION

Calcinosis cutis consists of deposition of calcium salts within the skin. It is commonly classified as metastatic, dystrophic, idiopathic or iatrogenic. In the metastatic form, calcium salts are deposited in the dermis or subcutis in patients with elevated serum levels of phosphorus and calcium. The dystrophic form occurs in previously damaged tissue in which calcium salts are deposited in the absence of any variation in serum levels of calcium and phosphorus (1).

Calcification of the auricular cartilage was first recognized as early as 1866 by Bochdalek (2). Since then, for more than a century this cutaneous condition has been reported under a variety of terms. Although it seems that the disease is infrequently seen in clinical practice, the true incidence of the condition is a matter of controversy. In 1932, Scherrer (3) examined 800 apparently healthy patients and no evidence of calcification was documented. In 1963, in a randomized study of a series of 300 patients, Gordon (4) examined for inflexibility of the ears. He found radiological evidence of calcification of the ear cartilage in 11 patients (3%). More recently, in 1998, Bowers & Gould (5) reported that auricular calcification is found more frequently in older people, especially those who have worked outdoors. These authors concluded that the disease is not, in fact, rare. It is possible that many people show some degree of involvement, and that the disease may be misdiagnosed or under-reported by clinicians because few patients come to the attention of dermatologists, or because it has rarely been the subject of wide dermatological studies.

The clinical appearance of the lesions is variable, but there are no clinical differences between calcification and ossification. Some cases are characterized by small nodules, some show marked rigidity of the cartilage portion of the ears when it is pinched, and some have a normal appearance. Most patients are asymptomatic or complain of external otalgia if the ear canal is involved (6). Ulceration is rare (7). X-ray examination of the external ears revealed calcification of the cartilage of the pinna. In some cases a trabecular bone pattern, suggestive of ossification, is found (8). From a histological point of view, most cases revealed deposition of calcium, with calcification of the cartilaginous tissue leading to ossification found more rarely. In these cases, lamellar bone with Haversian canals was found (9).

The pathogenesis of petrified ears, while frequently debated, remains unclear. The calcification may occur

either after local injury or in association with metabolic or metastatic diseases in which elevated serum levels of phosphorus and calcium are detected. Local injuries include mechanical trauma, actinic damage, insect bites, frostbite, radiation therapy, chondritis and perichondritis (4, 6). These processes are the most common precipitating factors and may induce local damage or cartilage necrosis with subsequent calcification, probably because tissue damage allows increased alkalinity, with increased intracellular calcium fluxes and subsequent calcification (1, 10). Many endocrine disorders have been associated with auricular calcification, Addison's disease being the most frequent (11). In this condition, there is hypercalcaemia secondary to cortisol deficiency, but the exact mechanism by which the disease induces calcification is unknown. Other associated endocrinopathies are diabetes mellitus, hypopituitarism, hypothyroidism and acromegaly (7). Systemic diseases associated with the condition are familial cold hypersensitivity, hypertension, alkaptonuria, scleroderma and systemic chondromalacia (4, 6, 11).

Clinical evaluation of these patients should include a complete blood cell count, serum levels of calcium and phosphorus, alkaline phosphatase, glucose test, thyroid function test, and parathyroid hormone test. An extensive work-up is not necessary. Radiography of the external ear should be performed. Histological examination is not mandatory.

Because most cases are asymptomatic there are no guidelines for treatment of this condition. An impro-

vement has been reported after conchal reduction by surgery (12).

## REFERENCES

1. Touart DM, Sau P. Cutaneous deposition diseases. Part II. *J Am Acad Dermatol* 1998; 39: 527–545.
2. Bochdalek V. Verknocherung der Aurecula. *Prag Vierteljahrschr* 1866; 89: 33–46.
3. Scherrer F. Calcification and ossification of the external ears. *Ann Otol* 1932; 41: 867–885.
4. Gordon D. Calcification of auricular cartilage. *Arch Intern Med* 1964; 112: 73–77.
5. Bowers PW, Gould DJ. Petrified ears. *Clin Exp Dermatol* 1998; 23: 143.
6. Larson P, Weinstock M, Welch R. Calcification of the auricular cartilage: a case report and literature review. *Cutis* 1992; 50: 55–57.
7. Strumia R, Lombardi AR, Altieri E. The petrified ear – a manifestation of dystrophic calcification. *Dermatology* 1997; 194: 371–373.
8. Clarke JT, Clarke LE, Miller JJ. Petrified ears: calcification of the auricular cartilage. *J Am Acad Dermatol* 2004; 51: 799–800.
9. Stites PC, Boyd AS, Zic J. Auricular ossificans (ectopic ossification of the auricle). *J Am Acad Dermatol* 2003; 49: 142–144.
10. Lautenschlager S, Itin PH, Ruffi T. The petrified ear. *Dermatology* 1994; 189: 435–436.
11. Monteagudo-Sánchez B, Miranda-Fillooy JA, Labandeira J, Pereiro Jr. Calcificación de los cartílagos auriculares. *Piel* 2005; 20: 544–545.
12. González-Sixto B, García-Doval I, Conde A, Mayo E, Pardavilo R, de la Torre C. Osificación bilateral del cartílago auricular. *Actas Dermosifiliogr* 2006; 97: 134–135.