

## Mycosis Fungoides with Recurrent Hodgkin's Lymphoma and Diffuse Large B-cell Lymphoma

Tomomitsu Miyagaki<sup>1</sup>, Makoto Sugaya<sup>1</sup>, Yosaku Minatani<sup>1</sup>, Hideki Fujita<sup>1</sup>, Akira Hangaishi<sup>2</sup>, Mineo Kurokawa<sup>2</sup>, Yutaka Takazawa<sup>3</sup> and Kunihiko Tamaki<sup>1</sup>

Departments of <sup>1</sup>Dermatology, <sup>2</sup>Hematology & Oncology, and <sup>3</sup>Pathology, Faculty of Medicine, University of Tokyo, 7-3-1 Hongo, Bunkyo-ku, Tokyo 113-8655, Japan. E-mail: miyagakit-der@h.u-tokyo.ac.jp

Accepted February 16, 2009.

Sir,

Mycosis fungoides (MF), a common form of primary cutaneous T-cell lymphoma (CTCL), is a type of non-Hodgkin's lymphoma (HL). Although the coexistence of multiple distinct lymphoid neoplasms in the same individual is rare, cases of CTCL associated with HL or other types of non-Hodgkin's lymphoma have been described previously (1–3). We report here a rare case of MF associated with a composite recurrent HL and diffuse large B-cell lymphoma (DLBCL).

### CASE REPORT

A 75-year-old Japanese man was referred to our hospital with scaly erythematous plaques distributed over most of his body. The patient had a history of nodular-sclerosing subtype HL diagnosed at the age of 62 years with persistent fever and left axillary lymph node swelling. Biopsy specimens from axillary lymph nodes showed a pleomorphic cellular infiltrate with bands of fibrosis and contained numerous large atypical cells, including Reed-Sternberg cells and lacunar cells (Fig. 1a). Immunohistochemistry and *in situ* hybridization showed that the Reed-Sternberg cells were positive for CD30 and Epstein-Barr virus-encoded RNA (EBER) and negative for CD20. In addition, T-cell markers were negative. These features confirmed the diagnosis of nodular-sclerosing subtype of HL. He was treated with polychemotherapy (cyclophosphamide, vincristine, procarbazine and prednisolone) combined with radiation therapy and complete remission was achieved. His medical history was otherwise unremarkable.

At presentation, scaly erythematous patches and infiltrated plaques were distributed over most of the patient's body (Fig. 2a). The skin lesions had initially appeared at the age of 64 years on his left arm and the number of lesions increased year after year. He had no lymphadenopathy. Histological examination of a skin biopsy specimen from the left shoulder revealed infiltration of small lymphocytes with only subtle nuclear atypia in the epidermis and superficial dermis (Fig. 2b). Immunohistochemical study showed that these atypical cells were positive for CD3 and CD4, but negative for CD20 and CD30. Southern blotting analysis of

T-cell receptor gene using DNA from lesional skin detected a monoclonal rearrangement band. Further detailed examination revealed no visceral, lymph node, or blood involvement. The patient was diagnosed with MF, T2bN0M0B0, clinical stage Ib.

The skin lesions were treated with oral psoralen-ultraviolet A (PUVA) therapy and topical corticosteroid, resulting in partial improvement. The skin lesions remained stable thereafter. Three years after the diagnosis of MF, a subcutaneous mass (3.5 × 3.0 cm) appeared on the patient's left lower abdomen. He also developed swelling of multiple lymph nodes, ranging from the aortic bifurcation region to the bilateral inguinal region. Biopsy specimens from the inguinal lymph nodes showed almost the same pathological findings as those from axillary lymph nodes at the age of 62 years (Fig. 1b). In addition, there was a lesion composed of diffuse infiltration of large-sized centroblasts (Fig. 1c). Most large atypical lymphocytes were positive for CD30 and negative for CD20 and CD4. By contrast, centroblasts were CD20-positive and CD30-negative. Large cell transformation of MF was denied because both large atypical lymphocytes and centroblasts were negative for T-cell markers. These findings were compatible with a composite lymphoma with relapse of HL and DLBCL, stage IIb. We could not analyse the clonal relationship between the two lymphomas because of the lack of agreement with genetic cloning of the patient. He received six cycles of rituximab-CHOP (cyclophosphamide, doxorubicin, vincristine and prednisolone) therapy, and a complete remission of the relapsed HL and DLBCL was achieved. In addition, the skin lesions of MF improved partially during the chemotherapy. After the chemotherapy, however, his MF began to deteriorate gradually with extensive patches and plaques and the development of nodules. Although the HL and DLBCL were still in remission, the patient died of MF at the age of 81 years (3 years after the diagnosis of a composite lymphoma with the relapse of HL and DLBCL).

### DISCUSSION

Patients with CTCL are known to have an increased risk of developing second malignancy, especially lymphoid neoplasms of different lineages (1–3). On

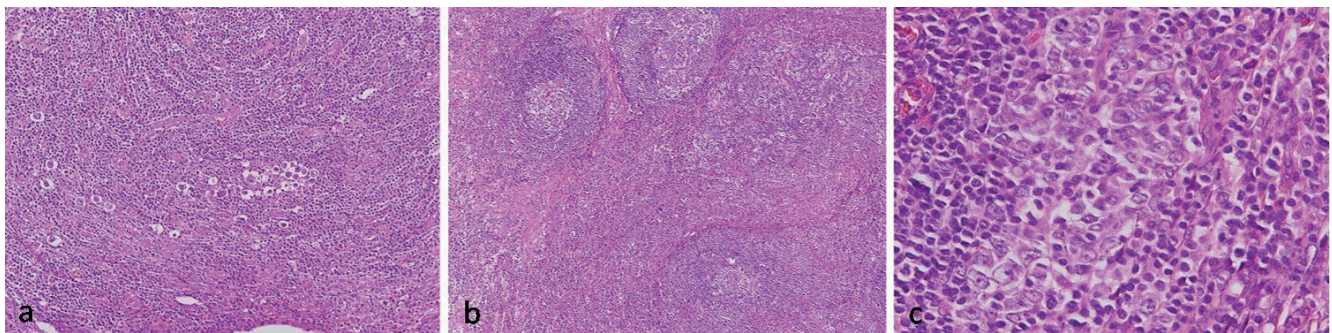


Fig. 1. (a) Hodgkin's disease, nodular sclerosing at the age of 62 years (haematoxylin-eosin stain ×200). (b) Hodgkin's disease, recurrence (×100). (c) Infiltration of large-sized centroblasts (×600).

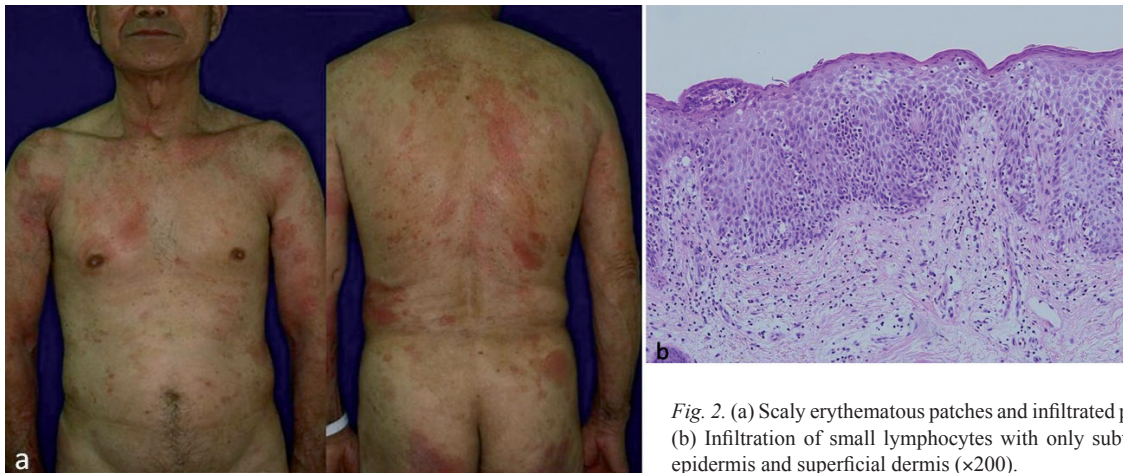


Fig. 2. (a) Scaly erythematous patches and infiltrated plaques all over the body. (b) Infiltration of small lymphocytes with only subtle nuclear atypia in the epidermis and superficial dermis ( $\times 200$ ).

the other hand, it is well known that patients with HL are at increased risk of developing second malignant neoplasms including non-Hodgkin's lymphoma (4–6). Occurrence of MF in patients with previous HL has also been reported occasionally (7).

Various explanations for the coexistence of different lymphomas in an individual have been proposed (4, 8), such as a genetic predisposition for malignancies (9). In our case, the patient's father had died of gastric cancer. It has been suggested that underlying viral infection may result in multiple lymphoproliferative disorders (10, 11). While our patient was negative for HTLV-1 and HIV antibodies, tumour cells of HL were positive for EBER. Furthermore, the mutagenic effects of cytostatic drugs have been assumed to be involved in the pathogenesis (12). In our patient, MF occurred after polychemotherapy combined with radiation therapy for HL. Patients with HL, advanced MF and Sézary syndrome are reported to have impaired immunity with an altered cytokine profile (13, 14). It was also possible that HL and CTCL were derived from the same pluripotent stem cells, which had a dual capacity for evolution of T and B cells. Although immunohistochemical staining for stem cell markers was not performed in our case, some reports have described a common clonal origin of CTCL and other types of lymphoma (15).

## REFERENCES

- Huang KP, Weinstock MA, Clarke CA, McMillan A, Hoppe RT, Kim YH. Second lymphomas and other malignant neoplasms in patients with mycosis fungoides and Sézary syndrome: evidence from population-based and clinical cohorts. *Arch Dermatol* 2007; 143: 45–50.
- Väkevää L, Pukkala E, Ranki A. Increased risk of secondary cancers in patients with primary cutaneous T cell lymphoma. *J Invest Dermatol* 2000; 115: 62–65.
- Hallermann C, Kaune KM, Tiemann M, Kunze E, Griesinger F, Mitteldorf C, et al. High frequency of primary cutaneous lymphomas associated with lymphoproliferative disorders of different lineage. *Ann Hematol* 2007; 86: 509–515.
- Mauch PM, Kalish LA, Marcus KC, Coleman CN, Shulman LN, Krill E, et al. Second malignancies after treatment for laparotomy staged IA-IIIB Hodgkin's disease: long-term analysis of risk factors and outcome. *Blood* 1996; 87: 3625–3632.
- Ng AK, Bernardo MV, Weller E, Backstrand K, Silver B, Marcus KC, et al. Second malignancy after Hodgkin disease treated with radiation therapy with or without chemotherapy: long-term risks and risk factors. *Blood* 2002; 100: 1989–1996.
- van Leeuwen FE, Klokman WJ, Hagenbeek A, Noyon R, van den Belt-Dusebout AW, van Kerkhoff EH, et al. Second cancer risk following Hodgkin's disease: a 20-year follow-up study. *J Clin Oncol* 1994; 12: 312–325.
- Beylot-Barry M, Dubus P, Vergier B, Cogrel O, Marit G, Beylot C, et al. Meningeal involvement by a transformed mycosis fungoides following Hodgkin's disease. *Br J Dermatol* 1999; 141: 909–913.
- Grange F, Avril MF, Esteve E, Joly P, Bosq J, de Muret A, et al. Coexistent cutaneous T-cell lymphoma and B-cell malignancy. French Study Group on Cutaneous Lymphomas. *J Am Acad Dermatol* 1994; 31: 724–731.
- Weiss VC, Barsky GJ, Solomon LM. Cutaneous T-lymphocyte lymphoma in association with multiple myeloma. *Arch Dermatol* 1984; 120: 499–501.
- Kikuchi A, Anzai H, Kosuge H, Naka W, Nishikawa T. Aggressive B-cell lymphoma induced by Epstein-Barr virus infection in erythrodermic cutaneous T-cell lymphoma. *Br J Dermatol* 1997; 136: 124–128.
- Peterman A, Jerdan M, Staal S, Bender B, Striecher H, Schüpbach J, et al. Evidence for HTLV-I associated with mycosis fungoides and B-cell chronic lymphocytic leukemia. *Arch Dermatol* 1986; 122: 568–571.
- Sheibani K, Forman SJ, Winberg CD, Rappaport H. Coincidence of B-cell chronic lymphocytic leukemia and cutaneous T-cell lymphoma (mycosis fungoides): immunologic characterization by monoclonal antibodies. *Blood* 1983; 62: 1176–1181.
- Bennett MH, MacLennan KA, Vaughan Hudson G, Vaughan Hudson B. Non-Hodgkin's lymphoma arising in patients treated for Hodgkin's disease in the BNLI: a 20-year experience. *British National Lymphoma Investigation. Ann Oncol* 1991; 2: 83–92.
- Lee BN, Duvic M, Tang CK, Bueso-Ramos C, Estrov Z, Reuben JM. Dysregulated synthesis of intracellular type 1 and type 2 cytokines by T cells of patients with cutaneous T-cell lymphoma. *Clin Diagn Lab Immunol* 1999; 6: 79–84.
- Gniadecki R. Neoplastic stem cells in cutaneous lymphomas: evidence and clinical implications. *Arch Dermatol* 2004; 140: 1156–1160.