

## A Case of Cutaneous Polyarteritis Nodosa in Autoimmune Hepatitis

Woo Jin Lee, Chae Hwa Kim, Sung Eun Chang, Mi Woo Lee\*, Jee Ho Choi, Kee Chan Moon and Jai Kyoung Koh

Department of Dermatology, Asan Medical Center, University of Ulsan College of Medicine, 388-1 Pungnapdong Songpaju, Seoul, 138-736 Korea.

\*E-mail: jijulee@hanmail.net

Accepted February 26, 2009.

Sir,

Cutaneous polyarteritis nodosa (CPAN) is a necrotizing vasculitis involving small- and medium-sized arteries. It has a benign and chronic course without systemic involvement. Its pathogenesis is thought to involve immune-complex-mediated reactions (1). We describe here the case of a patient with autoimmune hepatitis (AIH) who presented with CPAN.

### CASE REPORT

A 26-year-old woman presented in March 2008 with a 2-week history of recurrent painful erythematous nodules and swelling on both legs, and myalgia of the calves (Fig. 1). She had a 3-week history of general weakness and fatigue. In 2004, the patient had presented with fatigue and fever, and was subsequently diagnosed with AIH based on liver biopsy and serology results. In 2004, on admission to our hospital, several laboratory tests showed abnormal results, including aspartate transferase (AST) 601 IU/l (normal <40 IU/l), alanine transferase (ALT) 1464 IU/l (normal <40 IU/l), gamma glutamyl transferase 62 IU/l (normal 8–35 IU/l) and immunoglobulin G (IgG) 1870 mg/dl

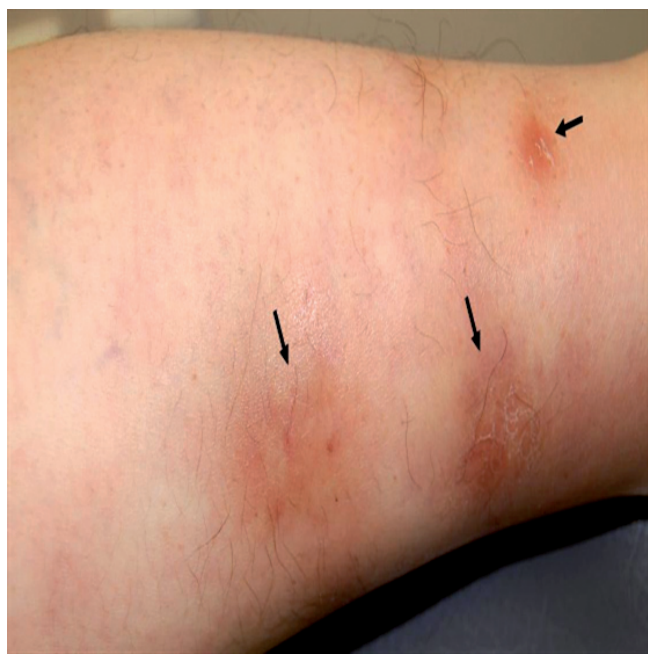

Fig. 1. Appearance of the lesion, with indurated, erythematous nodules 20 mm in diameter on the left shin.

(normal 694–1618 mg/dl). Serological tests for viral hepatitis were all negative. Her serum was positive for antinuclear antibodies and anti-smooth muscle antibodies, and a liver biopsy showed interface dermatitis with bridging fibrosis; these results were compatible with AIH. Administration of prednisolone and azathioprine achieved resolution. Her general condition had been good and liver function had been well-controlled for 4 years. Oral prednisolone could be tapered to 5 mg daily. Biopsy specimens of the erythematous nodule revealed panmural necrotizing vasculitis in the dermis and subcutis. Transmural inflammation of the arterial wall with infiltrates of mononuclear cells and neutrophils was accompanied by leukocytoclasia and fibrinoid degeneration. Involved vessels showed an almost complete occlusion of the lumen with intimal proliferation. Perivascular infiltration with mononuclear cells and neutrophils, and focal panniculitis were found within subcutis around involved vessels (Fig. 2). Direct immunofluorescence testing showed IgG and IgA deposits in the walls of the involved vessels. Several laboratory tests showed abnormal results, including haemoglobin 11.2 g/dl (normal 12–16 g/dl), erythrocyte sedimentation rate 91 mm/h (normal 0–20 mm/h), AST 520 IU/L (normal <40 IU/l) and ALT 840 IU/l (normal <40 IU/l). The patient tested positive for antinuclear antibodies (titre 1:320; normal <1:40), and

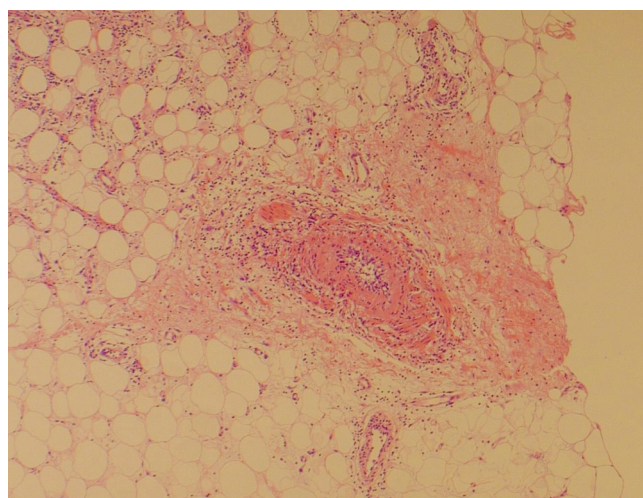


Fig. 2. Histopathological examination of the lesion. A panmural necrotizing vasculitis with infiltration of mononuclear cells and neutrophils into the subcutis was observed, together with fibrinoid degeneration, intimal proliferation and an almost complete obliteration of the lumen (haematoxylin-eosin stain  $\times 100$ ).

anti-double-strand DNA antibodies (15.4 IU/ml; normal <7 IU/ml). Her serum was negative for hepatitis B virus (HBV) surface antigen and IgM antibodies for HBV core antigen and hepatitis A virus. Hepatitis C virus (HCV) infection was ruled out by serological tests, such as reverse transcription polymerase chain reaction for HCV RNA and enzyme-linked immunoabsorbent assay. Tests for perinuclear and cytoplasmic anti-neutrophil cytoplasmic antibodies and rheumatoid factor were all negative. Based on the findings in this patient with uncontrolled AIH, the skin lesion was diagnosed as CPAN. She was treated with prednisolone 40 mg daily and showed resolution in both cutaneous lesions and her general condition.

## DISCUSSION

Although the precise aetiology of CPAN remains to be determined, it is thought to be caused by an immune-mediated pathophysiological mechanism, with deposition of IgM and C3 observed in biopsy specimens (2). Infectious agents, such as streptococci and hepatitis C virus, have been implicated in the pathogenesis of CPAN. CPAN could be a result of complement activation by immune complexes containing infectious organisms (3). By contrast, there is no evidence to indicate that HBV has a role in the pathogenesis of CPAN (3). An infectious cause was excluded in our patient based on her medical history and the results of a clinical examination and serology tests. CPAN has also been associated with Crohn's disease, ulcerative colitis, and myasthenia gravis (4, 5). The circulating immune complexes in these diseases may trigger CPAN, which could be an immunological complication of the underlying disease.

AIH is an idiopathic disorder affecting the hepatic parenchyma, caused primarily by autoimmune reactions against host antigens. AIH is characterized by the pre-

sence of interface hepatitis, hypergammaglobulinaemia, and auto-antibodies in the serum. Immunological tests essential for diagnosis include assays for antinuclear antibodies, anti-smooth muscle antibodies, and antibodies to liver/kidney microsome type 1 (6). AIH may occur in association with other immunological disorders, including inflammatory bowel disease, Graves' disease, rheumatoid arthritis, and systemic sclerosis (6). To our knowledge, this case is the first to show an association of CPAN with AIH, making an immune-complex-mediated pathogenesis of CPAN more likely. In the presenting patient, CPAN developed in the deteriorated course of AIH and the concurrent onset of these conditions suggest that they are pathogenetically related. Circulating immune complex in AIH could have triggered CPAN.

In addition, AIH and hepatitis C should be considered in the differential diagnosis of patients with CPAN and increased levels of liver enzymes.

*The authors declare no conflict of interest.*

## REFERENCES

1. Soter NA. Cutaneous necrotizing vasculitis. In: Freedberg IM, editor. Fitzpatrick's dermatology in general medicine. 6th edn, vol. 2. New York: McGraw-Hill; 2003, p. 1727–1734.
2. Diaz-Perez JL, Winklemann RK. Cutaneous periarteritis nodosa. Arch Dermatol 1974; 110: 407–414.
3. Soufir N, Descamps V, Crickx B, Thibault V, Cosnes A, Bécherel PA, et al. Hepatitis C virus infection in cutaneous polyarteritis nodosa: a retrospective study of 16 cases. Arch Dermatol 1999; 135: 1001–1002.
4. Matsumura Y, Mizuno K, Okamoto H, Imamura S. A case of cutaneous polyarteritis nodosa associated with ulcerative colitis. Br J Dermatol 2000; 142: 561–562.
5. El Sayed F, Dhaybi R, Ammourey A, Chababi M, Bazex J. Myasthenia gravis with cutaneous polyarteritis nodosa. Clin Exp Dermatol 2006; 31: 215–217.
6. Albert JC. Autoimmune hepatitis. In: Feldman M, editor. Sleisenger and Fordtran's gastrointestinal and liver disease, 7th edn. Philadelphia: Saunders; 2002, p. 1462–1471.