

## Subcutaneous Metastasis due to Primary Central Nervous System Malignant Lymphoma

Monji Koga<sup>1</sup>, Yuichi Yoshida<sup>2</sup>, Kaori Koga<sup>1</sup> and Juichiro Nakayama<sup>1</sup>

<sup>1</sup>Department of Dermatology, Fukuoka University School of Medicine, 7-45-1, Nanakuma Jonan-ku, Fukuoka 814-0180, and <sup>2</sup>Division of Dermatology, Department of Sensory and Motor Organs, Faculty of Medicine, Tottori University, Tottori, Japan. E-mail: mob3mob3@yahoo.co.jp  
Accepted January 13, 2009.

Sir,

Primary central nervous system malignant lymphoma (PCNSL) is a rare non-Hodgkin's lymphoma. Although it accounts for less than 1% of cases of non-Hodgkin's lymphoma, its incidence is increasing due to the ageing society (1). Histologically, the main type of PCNSL is diffuse large B-cell lymphoma (DLBCL). Local recurrence of PCNSL has often been observed, but skin metastasis of PCNSL is rare, only one case of skin metastasis having been reported previously (2). We report here a case of PCNSL with subcutaneous metastasis on the forearm.

### CASE REPORT

An 81-year-old Japanese woman was referred to our hospital for evaluation of a 6-month history of an asymptomatic red nodule on the left forearm. Physical examination revealed a painless, slow-growing, subcutaneous nodule, 35 × 25 mm in size (Fig. 1). The lesional lymph nodes were not palpable. Results of laboratory tests, including complete blood cell count and serum chemistry, were within normal limits, except for a slight increase in lactate dehydrogenase, to 255 IU/l. She had a medical history of PCNSL (DLBCL) and had undergone excisional biopsy, radiotherapy (whole brain irradiation total 31 Gy) and intravenous steroid treatment 2 years previously. However, there was no evidence of local recurrence in the brain. A biopsy from the nodule revealed proliferation of medium-to-large-sized atypical lymphoid cells in the deep dermis to subcutaneous tissue. Abnormal mitotic

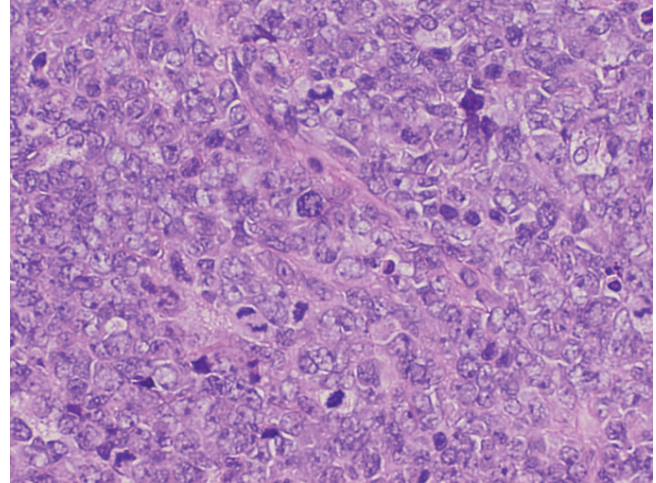


Fig. 2. Proliferation of atypical lymphoid cells in the tumour. Abnormal mitotic figures were seen (haematoxylin and eosin (H&E) ×200).

figures were frequently seen (Fig. 2). Histopathological findings of the nodule were similar to those of PCNSL (Fig. 3). Immunohistochemically, the tumour cells were positive for CD20 and CD79a, but negative for CD3, CD5 and CD10 (not shown), suggesting DLBCL. The staining results were compatible with those of PCNSL. Based on these findings, a diagnosis of subcutaneous metastasis due to PCNSL was made. We recommended excision of the tumour, but the patient and her family refused treatment and detailed examination. Ten months later, visual disturbance developed and local recur-

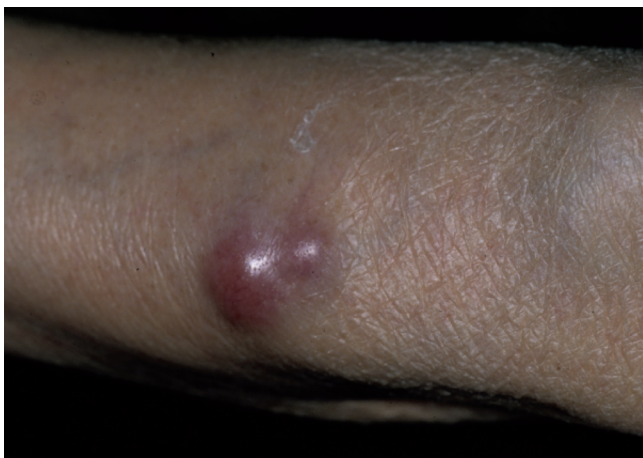

Fig. 1. A red nodule on the left forearm.

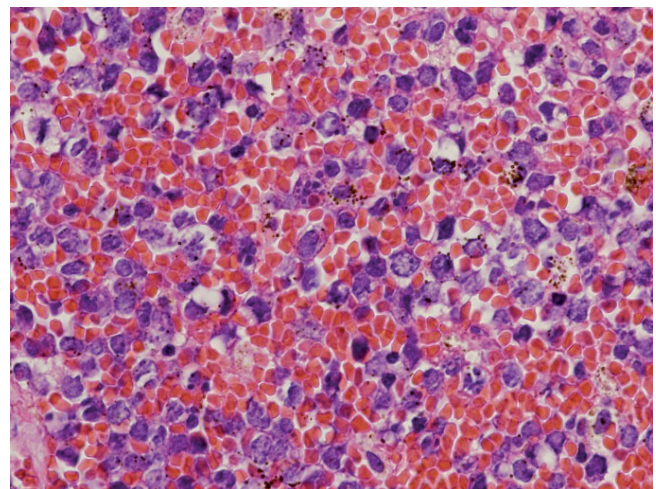


Fig. 3. Large atypical cells with irregular-shaped erythrocytes in the primary site (H&E ×200).

rence in the central nervous system was revealed by fundusoscopic examination.

## DISCUSSION

PCNSL accounts for approximately 1% of cases of intracranial malignant tumours. It is usually treated by radiation, administration of a steroid, and systemic combination chemotherapy, but the prognosis is extremely poor (3). It has been reported that the local recurrence rate after treatment is 90% and that the 5-year survival rate is 22.3% (2). Metastasis occurs in approximately 3–27% of cases (4). Although metastases of PCNSL have been found in lymph nodes, lung and kidney (4–7), only one case of subcutaneous metastasis (left leg) has been reported (2). In our case, there is a possibility that the lesion is primary cutaneous large B-cell lymphoma. However, histological features and immunohistochemical findings of the subcutaneous lesion were almost compatible with those of a primary tumour. In addition, local recurrence was observed 10 months later. Therefore, we believe that our case is a subcutaneous metastasis due to PCNSL. We speculate that the reason for the rarity of skin metastasis is related to the poor prognosis of PCNSL. PCNSL in elderly patients is fatal in most cases and it is difficult to treat the primary site. In our case, although the primary lesion had been controlled relatively well for 2 years

by radiation without systemic chemotherapy, because of the advanced age of the patient, metastasis could not be prevented. In conclusion, we emphasize that it is important for clinicians to consider the possibility of metastatic lymphoma in differential diagnosis of a cutaneous neoplasm.

## REFERENCES

1. Panageas KS, Elkin EB, DeAngelis LM, Ben-Porat L, Abrey LE. Trends in survival from primary central nervous system lymphoma 1975–1999. *Cancer* 2005; 104: 2466–2472.
2. Bahrani BA, Henderson C, Delaney G. Primary central nervous system lymphoma and subcutaneous metastases. *J Neurooncol* 2000; 47: 141–144.
3. DeAngelis LM, Yahalom J, Thaler HT, Kher U. Combined modality therapy for primary CNS lymphoma. *J Clin Oncol* 1992; 104: 635–643.
4. Brown MT, Mc Clendon RE, Gockerman JP. Primary central nervous system lymphoma with systemic metastasis: case report and review. *J Neurooncol* 1995; 23: 207–221.
5. Abrey LE, DeAngelis LM, Yahalom J. Long-term survival in primary CNS lymphoma. *J Clin Oncol* 1998; 16: 859–863.
6. Berry MP, Simpson WJ. Radiation therapy in the management of primary malignant lymphoma of the brain. *Int J Rad Oncol Biol Phys* 1981; 7: 55–59.
7. Miller DC, Hochberg H, Harris NK, Gruber ML, Louis DN, Cohen H. Pathology with clinical correlations of primary central nervous system non-Hodgkin's lymphoma. The Massachusetts General Hospital experience 1958–1989. *Cancer* 1994; 74: 1383–1397.