

## Pseudolymphomatoid Cutaneous Leishmaniasis in a Patient Treated with Adalimumab for Rheumatoid Arthritis

Susana Baltà-Cruz<sup>1</sup>, Mercé Alsina-Gibert<sup>1\*</sup>, Ana Mozos-Rocafort<sup>2</sup>, Carlos Cervera<sup>3</sup>, Lluís Colomo-Saperas<sup>2</sup>, Ana Del Río<sup>3</sup> and Teresa Estrach-Panella<sup>1</sup>

Departments of <sup>1</sup>Dermatology, <sup>2</sup>Anatomopathology and <sup>3</sup>Infectious Diseases, Hospital Clinic, IDIBAPS, Barcelona University, C/ Villarroel 170, ES-08036 Barcelona, Spain. \*E-mail: malsina@clinic.ub.es  
Accepted December 4, 2008.

Sir,

Clinical guidelines for the use of tumour necrosis factor- $\alpha$  (TNF- $\alpha$ ) blockers emphasize the increased risk of developing opportunistic infections. However, leishmaniasis is not mentioned among these infections. We report here a case of a woman with rheumatoid arthritis treated with methotrexate, prednisone and the TNF-antagonist adalimumab, who presented an aggressive form of cutaneous leishmaniasis mimicking a T-cell lymphoma.

### CASE REPORT

A 56-year-old Caucasian woman living in Girona (northeast Spain), diagnosed with rheumatoid arthritis (RA) in 1992, was treated with methotrexate (MTX) (15 mg weekly, Metotrexato Lederle<sup>®</sup>) and corticosteroids (3.75 mg prednisone daily, Dacortin<sup>®</sup>) without relevant side-effects. Due to a poor response, infliximab (Remicade<sup>®</sup>), an anti-TNF- $\alpha$  antibody drug, was added in October 2000. In May 2004, again because of poor response, infliximab was substituted by adalimumab (Humira<sup>®</sup>) without a washout period. Both drugs, infliximab and adalimumab, were administered at standard dosages. In July 2004, the patient was diagnosed with localized cutaneous leishmaniasis (CL) on her right leg. She was treated with intralesional pentavalent antimonials (Glucantime<sup>®</sup>) first and surgical excision thereafter. MTX, prednisone and adalimumab were maintained until July 2006, when she developed infiltrative mucocutaneous tumours on the upper lip, hard palate and nasal septum (Fig. 1). Oral antibiotics and antifungals were administered without clinical improvement. Because of the progression of the lesions a biopsy was taken from the lip. The haematoxylin and eosin-stained slides showed a dense atypical lymphocytic infiltrate with admixed plasma cells and epithelioid histiocytes in some areas. Mitotic figures, necrosis and mucosal ulceration were also observed.

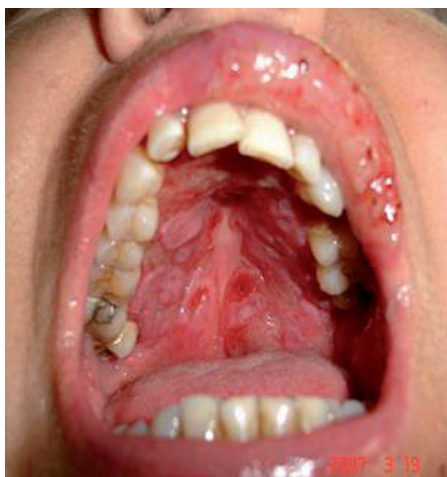

Fig. 1. Mucocutaneous tumour infiltrating the superior lip and hard palate.

The immunohistochemical studies showed a predominance of  $\beta$ F1-positive T cells without phenotypic abnormalities and a preserved proportion of CD4 and CD8 cells. CD56 and granzyme B revealed a high amount of activated natural killer (NK) cells. The B-cell component was scarce and did not show atypical features or Epstein Barr-virus infection. The IgH (FR1 and FR3 regions) and T-cell receptor- $\gamma$  rearrangements were polyclonal. A diagnosis of a peripheral T-cell lymphoma was considered and the patient was referred to our institution for staging. Laboratory tests, computed tomography chest scan and bone marrow biopsy were normal. Considering the previous history of CL on her right leg and as the diagnosis of T-cell lymphoma was unclear, skin biopsies were reviewed. Occasional *Leishmania* parasites could be identified within the histiocytes in few areas of the biopsy of the lip (Fig. 2). PCR amplification of *Leishmania* genomic sequences confirmed the diagnosis. The *Leishmania* PCR in peripheral blood and the skin culture were negative. A diagnosis of CL with severe mucous involvement was made and patient was put on intravenous liposomal amphotericin B (Amphocil<sup>®</sup> 3 mg/kg/day). Due to severe infusional adverse events it was replaced by intramuscular Glucantime<sup>®</sup> (meglumine antimonate) at a dose of 20 mg/kg per day. After 13 days Glucantime<sup>®</sup> was also withdrawn because of skin rash. However, the skin lesions improved and no evidence of new lesions were detected. Treatment with adalimumab, MTX and prednisone was reintroduced by her rheumatologist a few weeks later, because of worsening of arthritis. The patient remains asymptomatic and without evidence of new mucosal lesions after 12 months' follow-up.

### DISCUSSION

TNF- $\alpha$  is a pro-inflammatory cytokine produced by macrophages, monocytes and T lymphocytes. Physiologically, TNF- $\alpha$  plays an important role in host defence

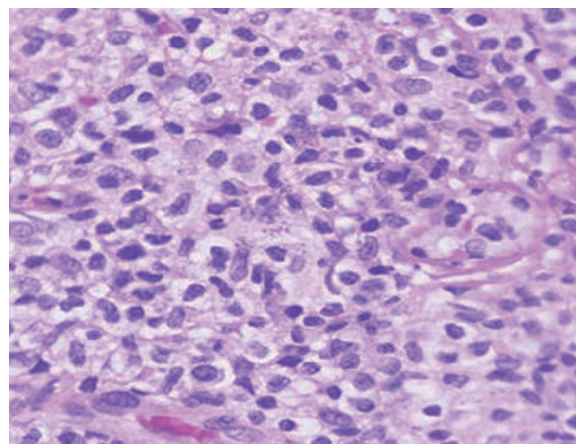


Fig. 2. Dense atypical lymphocytic infiltrate. Occasional *Leishmania* parasites are visible within the histiocytes (Haematoxylin-Eosin  $\times 40$ ).

against bacterial or viral infections and it is necessary for granuloma formation and maintenance.

Clinical guidelines recommend screening for latent tuberculosis and prophylactic anti-tuberculosis treatment before starting anti-TNF- $\alpha$  therapy. As there is also an increased risk of developing opportunistic infections such as histoplasmosis, listeriosis, coccidiomycosis, candidiasis, *Pneumocystis jiroveci* pneumonia and aspergillosis, patients should be closely monitored for signs and symptoms of these infections, which might occur atypically (1). However, current recommendations do not include *Leishmania* infection as a disease to be considered during or before starting anti-TNF- $\alpha$  therapy.

The Mediterranean area is an endemic zone for *L. infantum* infection. Our patient had not travelled abroad, so it was assumed that the infection was caused by this *Leishmania* species. Localized CL is the usual clinical presentation, but visceral leishmaniasis may occur in infants and patients with HIV. Although mucosal affectation can appear in immunocompetent subjects (2), our patient presented with an aggressive reactivation of CL with mucocutaneous tumours, which are commonly seen in immunosuppressed patients. At that time, she was being treated with MTX, prednisone and adalimumab for her RA. There are cases reported of mucosal (3) and also visceral leishmaniasis (4) in patients under MTX treatment. The addition of adalimumab can be responsible for most severe forms of mucosal affectation due to a lack of granuloma formation, and could be one of the factors implicated in the development of pseudotumoural lesions in our patient.

Histopathological findings of CL may sometimes mimic lymphoma (5). In our case, the biopsy specimen revealed a dense and atypical lymphoid infiltrate of T-cell phenotype with necrotic areas. The differential diagnosis included methotrexate or anti-TNF-associated lymphoproliferative disorders (LPDs), sporadic peripheral T-cell lymphoma or a reactive process. Thus, the diagnosis of lymphoma was seriously considered in the setting of a patient with autoimmune disease treated with multiple immunosuppressive drugs. Once the previous history of CL arose, and due to the absence of phenotypical and molecular abnormalities, the diagnostic approach was repeated to demonstrate *Leishmania* parasites.

Patients with RA have an approximately 2-fold increased risk of developing lymphoma (6). The precise role of the treatments as a factor in the pathogenesis of LPDs has not yet been established and this question is currently under debate (7). However, MTX-associated LPDs is a category included in the current WHO classification for haematological diseases (6) and cases of lymphoma in patients treated with anti-TNF have also been reported.

To our knowledge, there are four other cases described of visceral leishmaniasis infection in patients treated with TNF- $\alpha$  antagonists (9–12). Although leishmaniasis is a

rare event in patients treated with a TNF- $\alpha$  antagonist, this condition should be added to the infections that may complicate anti-TNF- $\alpha$  drug therapies, at least for patients living in endemic areas. As there is no screening test to assess the risk of leishmaniasis, before starting treatment patients should be interrogated about a past history of leishmaniasis in order to avoid reactivation of latent disease and should be closely monitored for signs and symptoms of a new infection acquired during the treatment.

#### ACKNOWLEDGEMENT

We thank Dr Gabriel Riera for assistance in providing the rheumatological clinical history.

#### REFERENCES

1. Strangfeld A, Listing J. Bacterial and opportunistic infections during anti-TNF therapy. *Best Pract Res Clin Rheumatol* 2006; 20: 1181–1195.
2. Aliaga L, Cobo F, Mediavilla JD, Bravo J, Osuna A, Amador JM, et al. Localized mucosal leishmaniasis due to *Leishmania* (*Leishmania*) *infantum*: clinical and microbiologic findings in 31 patients. *Medicine* (Baltimore) 2003; 82: 147–158.
3. Saha M, Shipley D, McBride S, Kennedy C, Vega-Lopez F. Atypical cutaneous leishmaniasis in two patients receiving low-dose methotrexate. *Br J Dermatol* 2006; 155: 830–833.
4. Gardner-Medwin JM, Powell RJ. One patient, two unusual conditions and three basic lessons. *Ann Rheum Dis* 1996; 55: 350–352.
5. Böer A, Blödorn-Schlicht N, Wiebels D, Steinkraus V, Falk TM. Unusual histopathological features of cutaneous leishmaniasis identified by polymerase chain reaction specific for *Leishmania* on paraffin-embedded skin biopsies. *Br J Dermatol* 2006; 155: 815–819.
6. Harris NL, Swerdlow SH. Methotrexate-associated lymphoproliferative disorders. In: Jaffe ES, Harris NL, Stein H, Vardimon JW, editors. *World Health Organization classification of tumours. Pathology and genetics of tumours of haematopoietic and lymphoid tissues*. Lyon: IARC Press; 2001, p. 267–268.
7. Wolfe F, Michaud K. The effect of methotrexate and anti-tumor necrosis factor therapy on the risk of lymphoma in rheumatoid arthritis in 19,562 patients during 89,710 persons-years of observation. *Arthritis Rheum* 2007; 56: 1433–1439.
8. Brown SL, Greene MH, Gershon SK, Edwards ET, Braun MM. Tumor necrosis factor antagonist therapy and lymphoma development: twenty-six cases reported to the Food and Drug Administration. *Arthritis Rheum* 2002; 46: 3151–3158.
9. Bassetti RM, Pizzorni C, Gradoni L, Del Bono V, Cutolo M, Viscoli C. Visceral leishmaniasis infection in a rheumatoid arthritis patient treated with adalimumab. *Rheumatology* 2006; 45: 1446–1448.
10. Bagalas V, Kioumis I, Argyropoulou P, Patakas D. Visceral leishmaniasis infection in a patient with rheumatoid arthritis treated with etanercept. *Clin Rheumatol* 2007; 26: 1344–1345.
11. Fabre S, Gibert C, Lechiche C, Dereure J, Jorgensen C, Sany J. Visceral leishmaniasis infection in a rheumatoid arthritis patient treated with infliximab. *Clin Exp Rheumatol* 2005; 3: 891–892.
12. Romani-Costa V, Sanchez C, Moya F, Estany C. Visceral leishmaniasis related to infliximab administration. *Enferm Infecc Microbiol Clin* 2004; 22: 310.