

## Lymphangioliomyomatosis in a Patient with Tuberous Sclerosis and Dysregulated Diabetes Mellitus

Carsten Sauer Mikkelsen<sup>1</sup>, Dorthe Bisgaard Mikkelsen<sup>1</sup>, Helle Dall Madsen<sup>2</sup>, Poul Erik Andersen<sup>3</sup>, Pernille Ravn<sup>4</sup> and Anette Bygum<sup>1</sup>

Departments of <sup>1</sup>Dermatology, <sup>2</sup>Pulmonary Medicine, <sup>3</sup>Radiology, and <sup>4</sup>Obstetrics and Gynaecology, Odense University Hospital, DK-5000 Odense, Denmark. E-mail: c.s.mikkelsen@privat.dk  
Accepted November 17, 2008.

Sir,

Patients with tuberous sclerosis may develop lymphangioliomyomatosis (LAM). Severe lung insufficiency can develop and lung transplantation may be required. LAM is an oestrogen-dependent condition and successful treatment is difficult.

### CASE REPORT

A 43-year-old woman was referred to our medical ward complaining of fatigue, frequent cough, and shortness of breath following exertion, and episodes of haemoptysis. She had tuberous sclerosis based on epilepsy, mental retardation, renal cysts and cutaneous manifestations characterized by hypomelanotic macules, facial angiofibromas, periungval fibromas and shagreen patches in the lumbar region (1). She was obese and during recent years she had developed acanthosis nigricans and skin tags (acrochordons), indicating insulin resistance (2) with increased pro-insulin C-peptide 2667 pmol/l [130–760] and insulin 217 pmol/l [12–77]. The patient had been sterilized at the age of 18 years and had never received any medication containing

oestrogen. The results of lung and heart stethoscopy, as well as chest X-ray, were normal. Renal magnetic resonance (MR) scanning showed changes consistent with angiomyolipomas. Pulmonary function tests showed normal forced vital capacity (FVC) and forced expiratory volume in one second (FEV1). However a reduced diffusion capacity, measured by carbon monoxide diffusion in the lungs (DLCO) 58% [80–120 %] and diffusion constant (TLCO) 78% was found. Supplementary high-resolution computed tomography (HRCT) imaging demonstrated multiple, irregular thin-walled cysts arranged randomly in both lungs consistent with LAM (Fig. 1).

### DISCUSSION

Pulmonary LAM is a rare progressive cystic lung disease seen in approximately 15% of female patients with tuberous sclerosis (3). The lung parenchyma changes are induced by abnormal proliferation of atypical smooth muscle-like LAM cells placed interstitially and around bronchovascular structures (4). Progressive cell growth results in a cystic destruction of the lung parenchyma and risk of haemothorax, pneumothorax and obstruction of ductus thoracicus leading to chylothorax (5). Later, severe lung insufficiency can develop and lung transplantation may be necessary (6). LAM does not usually appear on an X-ray. Tests used to confirm or rule out the existence of LAM include pulmonary function tests, blood tests, HRCT scans (including abdominal areas) and lung biopsy (7). LAM is an oestrogen-dependent condition seen predominantly in women of reproductive age (8) and is exacerbated by pregnancy (9).

Genetic analyses have demonstrated that proliferative bronchiolar smooth muscle cells in tuberous sclerosis-related LAM can be monoclonal metastases from a co-existing renal angiomyolipoma (10–11). The proliferation of LAM cells is a result of genetic (tuberous sclerosis) or somatic (sporadic occurrence) mutations in the hamartin gene (tuberous sclerosis gene TSC1) or tuberin gene (TSC2), which are both tumour suppressor genes (12). The hamartin-tuberin complex regulates cell growth and proliferation through mammalian target of rapamycin (mTOR). Since insulin can increase the activity of mTOR (13) we advised that the patient underwent weight reduction in order to minimize

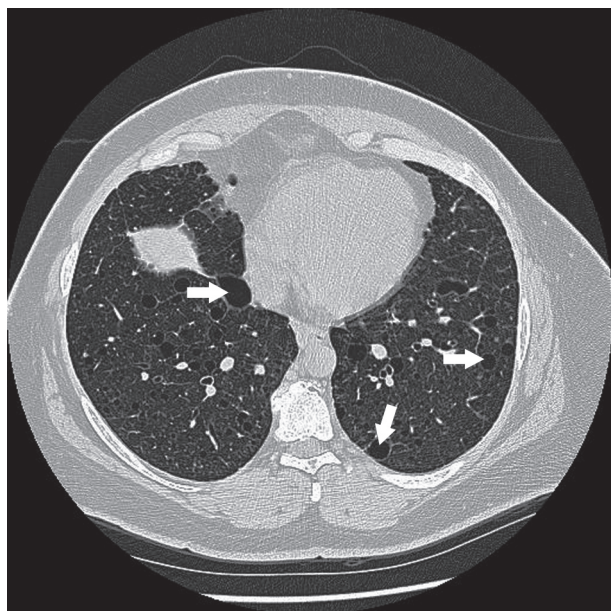


Fig. 1. High-resolution computed tomography demonstrated multiple, irregular, thin-walled cysts arranged randomly in both lungs consistent with lymphangioliomyomatosis.

her insulin resistance. In addition, we started treatment with luteinizing hormone-releasing hormone (LHRH) and have planned oophorectomy after one year in case of treatment response (14). On-going therapeutic trials with sirolimus, an inhibitor of mTOR, appear promising for future treatment (15).

## REFERENCES

1. Crino PB, Nathanson KL, Henske EP. The tuberous sclerosis complex. *N Engl J Med* 2006; 355: 1345–1356.
2. Hermanns-Lê T, Scheen A, Piérard GE. Acanthosis nigricans associated with insulin resistance: pathophysiology and management. *Am J Clin Dermatol* 2004; 5: 199–203.
3. Ryu JH, Moss J, Beck GJ, Lee JC, Brown KK, Chapmann JT, et al. The NHLBI lymphangioleiomyomatosis registry: characteristics of 230 patients at enrollment. *Am J Respir Crit Care Med* 2006; 173: 105–111.
4. McCormack FX. Lymphangioleiomyomatosis: a clinical update. *Chest* 2008; 133: 507–516.
5. Ryu JH, Doerr CH, Fischer SD, Olson EJ, Sahn EA. Chylothorax in lymphangioleiomyomatosis. *Chest* 2003; 123: 623–627.
6. Maurer JR, Ryu J, Beck G, Moss J, Lee JC, Finlay G, et al. Lung transplantation in the management of patients with lymphangioleiomyomatosis: baseline data from the NHLBI LAM Registry. *J Heart Lung Transplant* 2007; 26: 1293–1299.
7. Ferrans VJ, Yu ZX, Nelson WK, Valencia JC, Tatsuguchi A, Avila NA, et al. Lymphangioleiomyomatosis (LAM): a review of clinical and morphological features. *J Nippon Med Sch* 2000; 67: 311–329.
8. Flores-Delgado G, Anderson KD, Warburton D. Non-genomic estrogen action regulates tyrosine phosphatase activity and tuberin stability. *Mol Cell Endocrinol* 2003; 199: 143–151.
9. Goncharova EA, Krymskaya VP. Pulmonary lymphangioleiomyomatosis (LAM): progress and current challenges. *J Cell Biochem* 2008; 103: 369–382.
10. Yoshida S, Hayashi T, Ishii N, Yoshinaga A, Ohno R, Terao T, et al. Bilateral renal angiomyolipoma coexistent with pulmonary lymphangioleiomyomatosis and tuberous sclerosis. *Int Urol Nephrol* 2006; 38: 413–415.
11. Uzzo RG, Libby DM, Vaughan ED Jr, Levey SH. Coexisting lymphangioleiomyomatosis and bilateral angiomyolipomas in a patient with tuberous sclerosis. *J Urol* 1994; 151: 1612–1615.
12. Chorianopoulos D, Stratakos G. Lymphangioleiomyomatosis and tuberous sclerosis complex. *Lung* 2008; 186: 197–207.
13. Ozcan U, Ozcan L, Yilmaz E, Düvel K, Sahin M, Manning BD, et al. Loss of the tuberous sclerosis complex tumor suppressors triggers the unfolded protein response to regulate insulin signaling and apoptosis. *Mol Cell* 2008; 29: 541–551.
14. Rossi GA, Balbi B, Oddera S, Lantero S, Ravazzoni C. Response to treatment with an analog of the luteinizing-hormone-releasing hormone in a patient with pulmonary lymphangioleiomyomatosis. *Am Rev Respir Dis* 1991; 143: 174–176.
15. Paul E, Thiele E. Efficacy of sirolimus in treating tuberous sclerosis and lymphangioleiomyomatosis. *N Engl J Med* 2008; 358: 190–192.