

Multiple Accessory Tragi without Cartilage: Relationship with Hair Follicle Naevi?

Akihiko Asahina¹, Hiroyuki Mitomi², Naoki Sakurai¹, Hideki Fujita¹

Departments of ¹Dermatology and ²Pathology, Sagami-hara National Hospital, 18-1 Sakuradai, Sagami-hara, Kanagawa 228-8522, Japan.

E-mail: asahina-ky@umin.ac.jp

Accepted November 10, 2008.

Sir,

Accessory tragus is a minor congenital malformation that may be confused with a skin tag (1, 2). We describe here a rare case of multiple accessory tragi of a neonate, located simultaneously in the bilateral preauricular area and on the lateral neck. These lesions were almost identical histologically, and because of the lack of cartilage, it was necessary to consider the relationship with hair follicle naevi.

CASE REPORT

A 14-day-old girl was referred to our department after an uncomplicated prenatal course and delivery. Soft, elastic, skin-coloured papules were present bilaterally in the preauricular area, the right one of which was pedunculated (Fig. 1a, b). She also had a pedunculated, soft, elastic, skin-coloured papule on the left side of her neck (Fig. 1b, c). Her family history was non-contributory. The two polypoid lesions were surgically excised under local anaesthesia at 16 days after birth. Histopathologically, the right preauricular papule showed numerous tiny and mature hair follicles in various phases, accompanied by some sebaceous and eccrine glands (Fig. 2a). The cervical papule showed an almost identical histopathological picture (Fig. 2b, higher magnification). While fat cells were

scarce in this particular section, serial sections revealed their presence with a connective tissue framework (Fig. 2c). In both papules, cartilage could not be identified by examining serial sections, and no central keratinized cystic structure was found, excluding the possibility of trichofolliculoma (3, 4).

DISCUSSION

Accessory tragus arises typically on or near the tragus. Other less common sites include the cheek along the line of the mandible and the lateral neck anterior to the sternocleidomastoid muscle (1, 2). Although it may be multiple, the simultaneous occurrence in the preauricular region and on the neck is a very rare event that has not been previously well documented (5, 6). Such multiple occurrences could take place in some congenital disorders, including oculo-auricular-vertebral (Goldenhar) syndrome (7), but our patient had no discernible abnormalities in this regard. The tragus is the only part of the external ear developing from the first branchial arch (1, 2), and the accessory tragus located near the tragus or on the cheek represents a minor aberration of that structure. In contrast, the origin of the cervical lesion has been controversial. Because of its localization on the middle and lower thirds of the

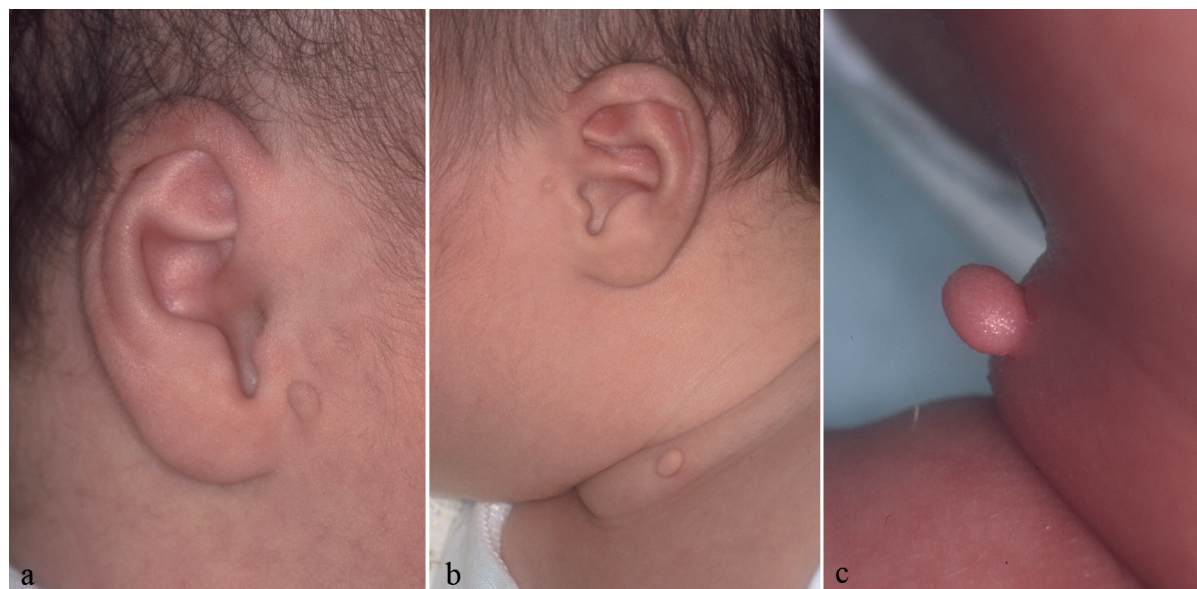


Fig. 1. (a) A pedunculated papule in the right preauricular area (3 × 3 × 5 mm). (b) A pedunculated papule on the left side of the neck (3 × 3 × 7 mm) together with a small preauricular papule. (c) A close-up view of the cervical papule.

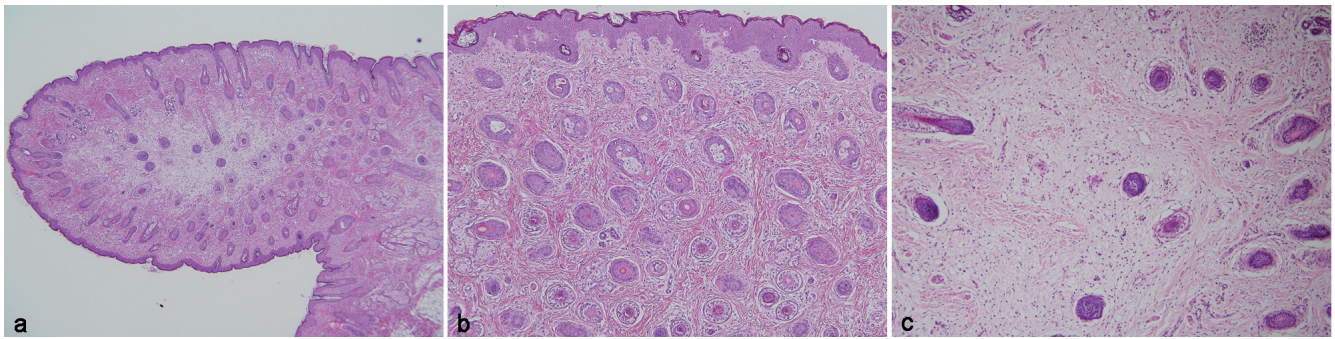


Fig. 2. (a) Light microscopic picture of the right preauricular papule showing numerous tiny but mature hair follicles in various phases, with and without vellus hair. (b) Higher-power magnification of the cervical papule. (c) Serial section of the same specimen showing abundant fat with a connective tissue framework. (H&E; original magnification: a, $\times 40$; b, c, $\times 100$).

neck, there is a hypothesis that they might be of a second branchial origin (6, 8). The clinical manifestation in our patient suggests another hypothesis, whereby the cervical lesion was also derived from the first branchial arch, and justifies calling them cervical accessory “tragus” rather than simply wattle or cervical auricles (5, 6, 8).

Although the absence of cartilage in accessory tragus is not necessarily uncommon (1, 9), there have been no definitive reports in the English literature regarding cervical lesions without cartilage. Indeed, another nomenclature of cervical chondrocutaneous branchial remnant (8) has been proposed, and cartilaginous naevus is an alternative description for those with cartilage. Our case offers valuable information regarding the relationship between accessory tragus and hair follicle naevus. Satoh et al. (9) reported that a prominent connective tissue framework in subcutaneous fat was found in accessory tragus, but not in hair follicle naevus, regardless of the presence of cartilage. Ban et al. (3) pointed out that the number of fat cells in the nodules or papules differed between the two conditions, with scant fat cells in hair follicle naevus. In our case, the diagnosis of hair follicle naevus seemed more suitable for the cervical lesion based on the scarcity of fat cells in one section. Serial sections, however, showed the presence of abundant fat with a connective tissue framework, suggesting that such differentiation criteria may be only arbitrary. Furthermore, the existence of eccrine glands and sebaceous units, as well as that of cartilage, is not useful for differentiation (3). It may not be essential to distinguish these disorders in the preauricular area, and hair follicle naevus may be incomplete accessory tragus (3). We are in favour of the concept that accessory tragus and hair follicle naevus are basically within the same spectrum of hamartoma, although the developmental mechanism may differ according to the component or location. In fact, similar to accessory tragus, hair follicle naevus reported thus far occurs almost exclusively on the face (4), and may show multiple lesions. It often presents with a polypoid clinical picture (4, 10), as in our case. It may be interpreted as accessory tragus when

it occurs in a typical area at birth or when it contains cartilage. In contrast, a lesion located in an atypical area for accessory tragus, such as near the median of the face, is usually devoid of cartilage and is then most likely diagnosed as hair follicle naevus. Kuwahara et al. (11) reported a case of hair follicle naevus occurring in frontonasal dysplasia. It is interesting to note that frontonasal dysplasia and oculo-auricular-vertebral syndrome, notably associated with multiple accessory tragi, sometimes occur together. Reconsideration of the relationship between accessory tragus and hair follicle naevus is thus desirable.

REFERENCES

1. Sebben JE. The accessory tragus – no ordinary skin tag. *J Dermatol Surg Oncol* 1989; 15: 304–307.
2. Jansen T, Romiti R, Altmeyer P. Accessory tragus: report of two cases and review of the literature. *Pediatr Dermatol* 2000; 17: 391–394.
3. Ban M, Kamiya H, Yamada T, Kitajima Y. Hair follicle nevi and accessory tragi: variable quantity of adipose tissue in connective tissue framework. *Pediatr Dermatol* 1997; 14: 433–436.
4. Davis DA, Cohen PR. Hair follicle nevus: case report and review of the literature. *Pediatr Dermatol* 1996; 13: 135–138.
5. Bendet E. A wattle (cervical accessory tragus). *Otolaryngol Head Neck Surg* 1999; 121: 508–509.
6. Fabian D, Lewin ML, Karlan MS. Cervical auriculars; congenital chondro-cutaneous appendages of the neck. *Plast Reconstr Surg* 1970; 45: 360–364.
7. Miller TD, Metry D. Multiple accessory tragi as a clue to the diagnosis of the oculo-auriculo-vertebral (Goldenhar) syndrome. *J Am Acad Dermatol* 2004; 50: S11–S13.
8. Atlan G, Egerszegi EP, Brochu P, Caouette-Laberge L, Bortoluzzi P. Cervical chondrocutaneous branchial remnants. *Plast Reconstr Surg* 1997; 100: 32–39.
9. Satoh T, Tokura Y, Katsumata M, Sonoda T, Takigawa M. Histological diagnostic criteria for accessory tragi. *J Cutan Pathol* 1990; 17: 206–210.
10. Patrizi A, Gaspari V, Bianchi F, Passarini B, Neri I. Pedunculated nodule on an infant’s face. *Pediatr Dermatol* 2007; 24: 555–556.
11. Kuwahara H, Lao LM, Kiyohara T, Kumakiri M, Igawa H. Hair follicle nevus occurring in frontonasal dysplasia: an electron microscopic observation. *J Dermatol* 2001; 28: 324–328.