

Prolonged Course of Acute Generalized Exanthematous Pustulosis with Liver Involvement due to Sensitization to Amoxicillin and Paracetamol

Regina Treudler, Sonja Grunewald, Carl Gebhardt and Jan-Christoph Simon

Department of Dermatology, Venerology and Allergology, Universitätsklinikum Leipzig A.ö.R., Leipzig, Member of GA²LEN (Global Allergy and Asthma European Network), Philipp-Rosenthal-Straße 23, DE-04103 Leipzig, Germany. E-mail: regina.treudler@medizin.uni-leipzig.de
Accepted November 10, 2008.

Sir,

The EuroSCAR group recently assigned paracetamol as “a drug of common use with no significant association” with acute generalized exanthematous pustulosis (AGEP) (1). However, some rare cases of AGEP in association with paracetamol intake have been reported (2–5). We report here the case of a patient for whom we have good evidence (i.e. by skin testing) that AGEP was elicited by a combination of amoxicillin and paracetamol and who showed unusual liver involvement and prolonged course of the disease.

CASE REPORT

A 48-year-old man with no history of psoriasis was treated with paracetamol because of otitis media. In addition, amoxicillin was started 2 days later and within 3 more days he developed exanthema, which was progressive despite immediate cessation of both drugs on day 5 after start of drug therapy, hospital admission on day 6 and therapy with prednisolone-succinate (250 mg/day for 2 days). On day 7 he was referred to our university hospital with pustular suberythrodermic exanthema (Fig. 1a) and oral erosions. Histology from the trunk revealed slight acanthosis and subcorneal pustules filled with neutrophils (Fig. 1b). In the papillary dermis there was a mixed perivascular and interstitial infiltrate of neutrophils, eosinophils and lymphocytes. Skin lesions were accompanied by fever $>39^{\circ}\text{C}$, leukocytosis (25/nl), neutrophilia (87%) and increased C-reactive protein level (CRP) (250 mg/l). On day 8, eosinophils and liver enzymes were within normal range, but gamma-glutamyl transferase (GGT) and alanine aminotransferase (ALT) then increased two- to three-fold, respectively, with a maximum on day 11 and only slight improvement until discharge on day 21. Serology was negative for acute viral infections (hepatitis A, B, C, Epstein-Barr virus, cytomegalovirus, human herpes virus (HHV)-6, parvovirus B19). The serum level of interleukin-17 was below the detection level (<2.5 pg/ml). Ultrasound revealed mild hepatomegaly but no lymphadenopathy. The content of the pustules was sterile, and blood culture was negative. The case was reported to the German Registry of Severe Skin Reactions (<http://www.uniklinik-freiburg.de/hautklinik/live/dzh.html>) and was classified as “probable” AGEP by an associated expert panel. Treatment included high-dose oral methylprednisolone (starting on day 7 with 160 mg, with slowly decreasing

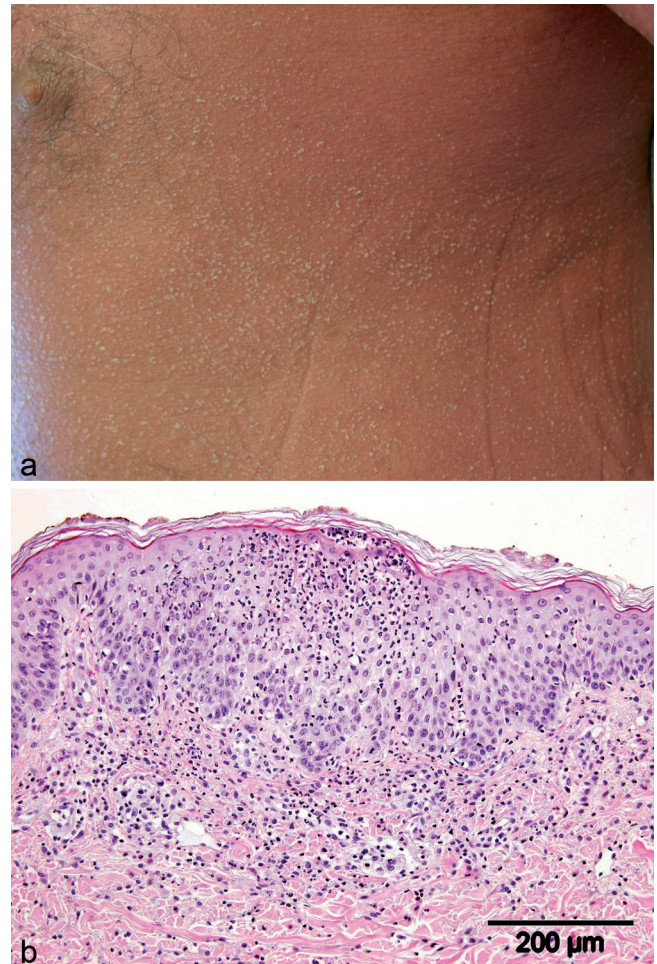


Fig. 1. (a) At first presentation, the patient showed suberythrodermic exanthema with typical non-follicular pustules. (b) Histology revealed slight acanthosis and subcorneal pustules filled with neutrophils. In the papillary dermis there was a mixed perivascular and interstitial infiltrate of neutrophils, eosinophils and lymphocytes.

dosages) in combination with topical corticosteroids. The skin lesions healed with desquamation and showed a prolonged clinical course over a period of 6 weeks, together with hepatomegaly and laboratory abnormalities. Skin testing performed 4 months later revealed positive patch tests for both amoxicillin and paracetamol (both 5% in petrolatum, day 3, Fig. 2) with papulopustular infiltrates reminiscent of typical AGEP lesions. A prick test was positive at late readings for amoxicillin (papular infiltrate of 5 mm at day 2) but not indicative for paracetamol (both pure in aqueous solution). The patient was advised to avoid both drugs in the future.

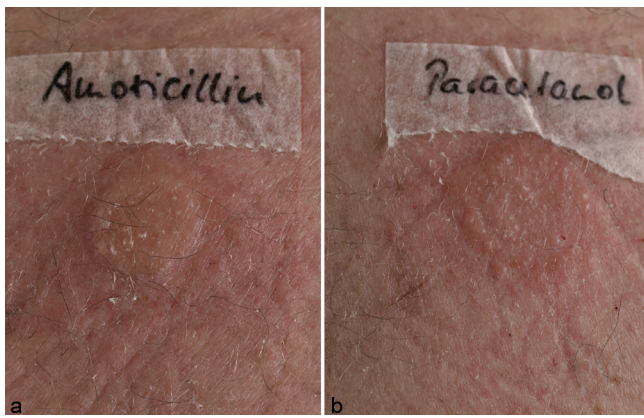

Fig. 2. Patch test reactions to (a) amoxicillin and (b) paracetamol (day 3) showed papular infiltrate with some pustules, reminiscent of acute generalized exanthematous pustulosis.

DISCUSSION

As in this case, AGEP symptoms most often start between one and 12 days after the beginning of drug intake (1). Viral infections are thought to trigger the disease (1), but this was not suspected in our patient. Complications such as haemodynamic disturbances or renal failure have been reported (4, 9), while liver involvement, as occurred in our patient, seems to be rare. As a very characteristic feature, a quick and spontaneous resolution in less than 15 days after stopping the drug is reported (1). In contrast, our patient needed prolonged corticosteroid treatment until complete recovery after 6 weeks. When applying a recently suggested scoring system for Drug Reaction with Eosinophilia and Systemic Symptoms (DRESS) (7, 9) this entity seemed to be a possible differential diagnosis, but other typical symptoms were lacking (no eosinophilia, no lymphadenopathy or HHV-6 reactivation; the latter, however, is only included in Japanese but not in European scoring systems) (7, 9). In addition, DRESS usually develops later than 3 weeks after the start of treatment with a limited number of drugs, (i.e. anticonvulsants, dapsone, abacavir) not typically involving those given in our patient (7).

Because of the clear history in combination with positive skin tests, we contributed our patient's symptoms to both amoxicillin and paracetamol. Positive patch tests in the diagnosis of AGEP have been reported for these two as well as for several other drugs (5). In our patient, patch testing was more sensitive than prick testing, where paracetamol remained negative. Definitive confirmation as the cause of AGEP could only be obtained by re-challenging the patient, which is, however, ethically not justifiable in severe cases like the one reported here.

The immune reaction associated with AGEP typically corresponds to a T-cell-dependent, sterile neutrophilic

inflammation related to high CXCL8 (formerly known as interleukin 8) and granulocyte monocyte colony stimulating factor (GM-CSF) production by T cells and tissue cells (10). Interleukin-17 was recently reported to orchestrate such neutrophil-mediated inflammatory processes (10); its normal serum levels in our patient might be due to the fact that he had already received systemic corticosteroids before being referred to our department.

In conclusion, the AGEP in our patient was unique because of: (i) the prolonged course of skin and liver involvement; and (ii) the combined sensitization to two drugs, including (iii) paracetamol, which was recently assigned as having no significant association with AGEP.

The authors declare no conflict of interest.

REFERENCES

- Sidoroff A, Dunant A, Viboud C, Halevy S, Bavinck JN, Naldi L, et al. Risk factors for acute generalized exanthematous pustulosis (AGEP)-results of a multinational case-control study (EuroSCAR). *Br J Dermatol* 2007; 157: 989–996.
- Halevy S, Cohen A, Livni E. Acute generalized exanthematous pustulosis associated with polysensitivity to paracetamol and bromhexine: the diagnostic role of in vitro interferon-gamma release test. *Clin Exp Dermatol* 2000; 25: 652–654.
- Wohl Y, Goldberg I, Sharazi I, Brenner S. A case of paracetamol-induced acute generalized exanthematous pustulosis in a pregnant woman localized in the neck region. *Skinmed* 2004; 3: 47–49.
- De Coninck AL, Van Strubarq AS, Pipeleers-Marichal MA, Huyghens LP, Suys ET, Roseeuw DI. Acute generalized exanthematous pustulosis induced by paracetamol. A case with severe hemodynamic disturbances. *Dermatology* 1996; 193: 338–341.
- Mashiah J, Brenner S. A systemic reaction to patch testing for the evaluation of acute generalized exanthematous pustulosis. *Arch Dermatol* 2003; 139: 1181–1183.
- Sidoroff A, Halevy S, Bavinck JN, Vaillant L, Roujeau JC. Acute generalized exanthematous pustulosis (AGEP) – a clinical reaction pattern. *J Cutan Pathol* 2001; 28: 113–119.
- Kardaun SH, Sidoroff A, Valeyrie-Allanore L, Halevy S, Davidovici BB, Mockenhaupt M, Roujeau JC. Variability in the clinical pattern of cutaneous side-effects of drugs with systemic symptoms: does a DRESS syndrome really exist? *Br J Dermatol* 2007; 156: 609–611.
- Brandenburg VM, Kurts C, Eitner F, Hamilton-Williams E, Heintz B. Acute reversible renal failure in acute generalized exanthematous pustulosis. *Nephrol Dial Transplant* 2002; 17: 1857–1858.
- Shiohara T, Iijima M, Ikezawa Z, Hashimoto K. The diagnosis of a DRESS syndrome has been sufficiently established on the basis of typical clinical features and viral reactivations. *Br J Dermatol* 2007; 156: 1083–1084.
- Pichler WJ. Drug hypersensitivity reactions: Classification and relationship to T-cell activation. In: Pichler WJ, editor. *Drug hypersensitivity*. Basel: Karger AG, 2007: p. 168–189.