

Urticaria Associated with Hyper-IgE in a Patient with Psoriasis Undergoing Treatment with Efalizumab

Rosita Saraceno¹, Gea Scotto², Andrea Chiricozzi¹ and Sergio Chimenti¹

Department of Dermatology, ¹University of Rome Tor Vergata, PTV, Viale Oxford, 81, IT-00133 Rome, Italy and ²Azienda Ospedaliera Sant'Anna e San Sebastiano, Caserta, Italy. E-mail: rositasaraceno@yahoo.it
Accepted October 20, 2008.

Sir,

Efalizumab (Raptiva®) is a recombinant humanized monoclonal IgG1 antibody that binds to CD11a, the α -subunit of leukocyte function antigen-1 (LFA-1). CD-11a modulates several key steps in the immunopathogenesis of psoriasis, including initial T-cell activation, trafficking from the circulation into psoriatic lesions, and reactivation therein (1). Efalizumab is approved in Europe and the USA for the treatment of plaque-type psoriasis, and several clinical trials have shown its safety and efficacy (2–4). The most common adverse events associated with efalizumab administration are acute flu-like symptoms (headache, chills, fever, myalgia, vomiting and nausea). More rarely, autoimmune thrombocytopenia, urticaria, haemolytic anaemia or other blood abnormalities have been reported (4–6).

CASE REPORT

We report here an uncommon adverse event associated with efalizumab in a 50-year-old Caucasian man who had had plaque-type psoriasis since the age of 35 years. Stable plaque lesions were localized on the scalp, trunk, upper and lower extremities. The medical history included conventional topical therapies, cyclosporine, methotrexate and phototherapy. No medical or family history of allergies, atopic dermatitis or asthma were reported by the patient. The patient's body weight was 71 kg and height 170 cm. The severity of the psoriasis was moderate-to-severe, with a psoriasis area and severity index (PASI) score of 15. Joint involvement was not present. The patient began with efalizumab in February 2007 at the standard loading dose of 0.7 mg/kg for the first week, and 1 mg/kg administered subcutaneously per week thereafter. Baseline laboratory data revealed a normal full blood count and all values were within the normal ranges, including the total IgE level. After one month of therapy, the patient presented an extensive urticarial rash accompanied by intense itching. Laboratory tests revealed high levels of total IgE (> 2000 IU/ml normal values 20.4–87.0). Anti-histamines were administered after complete radioallergosorbent test (RAST) and prick tests assessments. RAST and prick test results were negative, although these tests did not include efalizumab. The IgE level was persistently >2000 IU/ml at the subsequent evaluations. The patient

did not present any staphylococcal infection. Psoriasis did not improve significantly over the next 3 months. After 6 months of therapy efalizumab was discontinued due to the partial response (<50% of PASI) and the IgE levels >2000 IU/ml. After 2 weeks the IgE levels reduced to 1738 IU/ml and after 4 weeks there was a dramatic further reduction to 252 IU/ml (Fig. 1). In October 2007 the patient started a new treatment with the anti-tumour necrosis factor- α (TNF- α) receptor etanercept, at the conventional dosage of 50 mg twice weekly, administered subcutaneously for 12 weeks. A significant reduction in erythema, itch and desquamation was observed after 4 weeks of therapy. After 3 months, etanercept was administered at a dosage of 25 mg twice weekly for 12 weeks, achieving an almost complete resolution of the psoriatic lesions (PASI 1.2). After 4 months of efalizumab discontinuation, the IgE level was 60 IU/ml.

DISCUSSION

By blocking the interaction of CD11a and the intercellular adhesion molecule-1 (ICAM-1), efalizumab inhibits leukocyte trafficking into the skin as well as the continuous activation of T lymphocytes by antigen-presenting cells in the dermis and epidermis (1, 7). Efalizumab has a relatively rapid onset of action, with significant improvements in mean PASI scores noted as early as week 4 (2). However, our patient did not achieve a significant clinical response (PASI 50) in

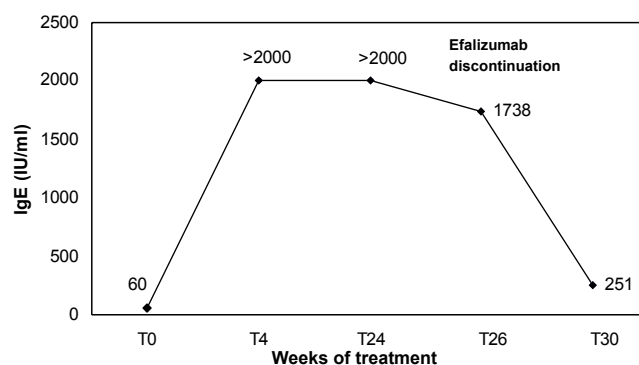


Fig. 1. An increased level of IgE was seen after efalizumab intake and a dramatic reduction in IgE with efalizumab discontinuation.

mid-term treatment with efalizumab. Concomitantly with the efalizumab administration the patient had a persistent increase in IgE. The hyper-IgE was also associated with intense itch and urticarial rash, which was partially controlled by administration of anti-histamine. The hyper-IgE was observed at the beginning of spring. However, all the allergy tests performed during and after treatment were negative.

Urticaria associated with hyper-IgE induced by efalizumab represents a rarely reported adverse reaction (6). Common adverse events during long-term treatment include increased cough, rhinitis, sinusitis and non-specific infections (e.g. colds) (3–4).

Antibodies formed against efalizumab or other epitopes as a result of treatment with efalizumab, a monoclonal antibody with important roles in T-cell function, may be postulated as the mechanism of development of the high level of IgE in our patient. Drug-induced auto-antibodies may recognize combinatorial epitopes formed by drug binding to environmental antigens.

Speculatively, the increase in IgE might represent an early parameter of unresponsiveness or partial response in a patient being treated with biologicals.

Based on the Naranjo algorithm, this adverse reaction was classed as possible (score = 8) (8). We believe that this combination is not coincidental, and that the development of hyper-IgE can be attributed to the medication.

REFERENCES

1. Jullien D, Prinz JC, Langley RG, Caro I, Dummer W, Joshi A, et al. T-cell modulation for the treatment of chronic plaque psoriasis with efalizumab (Raptiva): mechanisms of action. *Dermatology* 2004; 208: 297–306.
2. Leonardi C, Menter A, Hamilton T, Caro I, Xing B, Gottlieb AB, et al. Efalizumab: results of a 3-year continuous dosing study for the long-term control of psoriasis. *Br J Dermatol* 2008; 158: 1107–1116.
3. Costanzo A, Peris K, Talamonti M, Di Cesare A, Fargnoli MC, Botti E, et al. Long-term treatment of plaque psoriasis with efalizumab: an Italian experience. *Br J Dermatol* 2007; 156 Suppl 2: 17–23.
4. Varma R, Cafardi JA, Cantrell W, Elmetts C. Safety and efficacy of subcutaneously administered efalizumab in adults with moderate-to-severe hand and foot psoriasis: an open-label study. *Am J Clin Dermatol* 2008; 9: 105–109.
5. Fargnoli MC, Tabilio A, Coletti G, Peris K. Efalizumab-induced immune thrombocytopenia during retreatment. *J Am Acad Dermatol*. 2008; 58 Suppl 1: 125–127.
6. Papp KA, Miller B, Gordon KB, Caro I, Kwon P, Compton PG, et al. Efalizumab retreatment in patients with moderate to severe chronic plaque psoriasis. *J Am Acad Dermatol* 2006; 54: S164–S170.
7. Vugmeyster Y, Kikuchi T, Lowes MA, Chamian F, Kagen M, Gilleaudeau P, et al. Efalizumab (anti-CD11a)-induced increase in peripheral blood leukocytes in psoriasis patients is preferentially mediated by altered trafficking of memory CD8+ T cells into lesional skin. *Clin Immunol* 2004; 113: 38–46.
8. Naranjo CA, Busto U, Sellers EM, Sandor P, Ruiz I, Roberts EA, et al. A method for estimating the probability of adverse drug reactions. *Clin Pharmacol Ther* 1981; 30: 239–245.