

## CLINICAL REPORT

# Multiple Epidermolytic Acanthomas Must Not be Confused with Genital Human Papillomavirus Infection

Tarun KUKREJA and Aleksandar KRUNIC

Department of Dermatology (MC 624), University of Illinois at Chicago, Chicago, USA

**We describe two patients with multiple epidermolytic acanthomas on the scrotum initially referred to our clinic as genital warts. Both patients presented with multiple tan-colored warty papules scattered on the scrotal skin. Biopsy revealed hyperkeratosis, hypergranulosis, and clear cell changes consistent with epidermolytic acanthoma. Human papillomavirus was not detected and the lesions cleared rapidly with a liquid nitrogen cryoprobe. Despite only a few reports of multiple epidermolytic acanthomas of the scrotum, it may not be as rare as previously thought. In addition, genital localization of the wart-like lesions may lead to confusion with other conditions such as condylomata acuminata, molluscum contagiosum, or bowenoid papulosis. Key words: epidermolytic acanthoma; epidermolytic hyperkeratosis; human papillomavirus.**

(Accepted September 25, 2008.)

Acta Derm Venereol 2009; 89: 169–171.

Tarun Kukreja, Department of Dermatology (MC 624), University of Illinois at Chicago, 808 South Wood Street, Room 376 CME, Chicago, IL-60607, USA. E-mail: tkukreja@uic.edu.

Epidermolytic acanthoma is a benign tumor that was first described by Shapiro & Baraf in 1970 (1). Individual lesions have a warty surface and are usually less than 1 cm in diameter. Histopathology revealed epidermolytic hyperkeratosis consisting of orthohyperkeratosis, acanthosis, papillomatosis, and keratinocyte vacuolization with large coarse keratohyaline granules (1, 2). The etiology is unknown, with various authors suggesting trauma, sunburn, human papillomavirus (HPV), and immunosuppression playing a role in the pathogenesis (3). Several studies have failed to identify the presence of HPV in both scrotal and extragenital epidermolytic acanthomas (4). Immunohistochemical stains reveal alteration in keratins 1 and 10, similar to congenital bullous ichthyosiform erythroderma, which also has epidermolytic hyperkeratosis as the predominant histological hallmark (5).

## CASE REPORTS

Two patients presented to our clinic with multiple tan-colored warty papules on the scrotum. One was a 60-year-old man with a 30-year history of the lesions, and

the other was a 40-year-old man with a 6-year history of the lesions. Both patients were asymptomatic and could recall no triggering events. Their medical histories were unremarkable and the patients were healthy. Both were single but in monogamous heterosexual relationships with the same sexual partner for several years. Both patients tested negative for HIV 1 and 2, hepatitis B and C, syphilis, gonorrhea and chlamydia in a sexually transmitted disease panel. On physical examination the patients had multiple tan-colored 2–4 mm keratotic papules on both sides of the scrotum (Figs 1 and 2).

On histopathologic examination, the sections showed marked hyperkeratosis with orthokeratosis, papillomatosis and acanthosis. The granular layer was thickened with coarse keratohyaline granules. Separation and degeneration of cells in the granular layer with necrotic keratinocytes was observed in the mid and upper epidermis (Fig. 3). Immunohistochemical staining for HPV was negative for types 6, 11, 16, 18, 31, 33, 35, 39, 45, 51, 52, 56, 58, 59, 68, and 70.

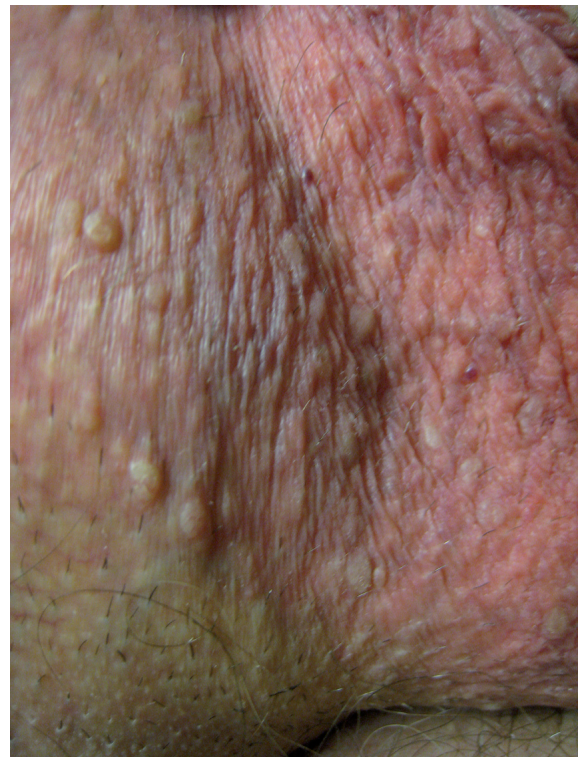


Fig. 1. Tan-colored keratotic papules on the scrotum.

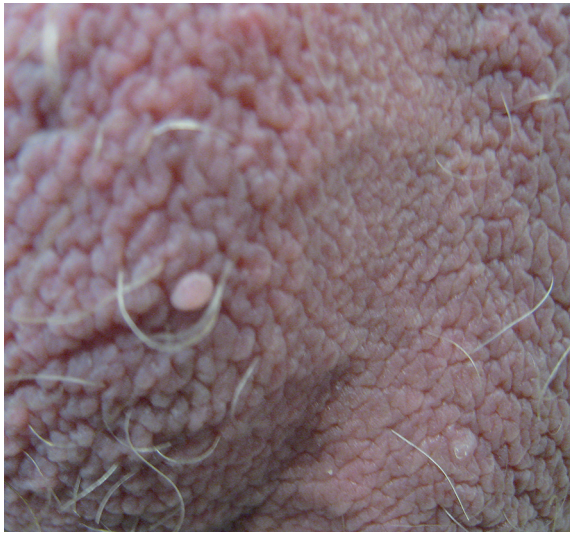


Fig. 2. Pedunculated tan-colored papules on the scrotum.

Both patients were treated with a liquid nitrogen cryoprobe applied directly to the lesions for 10 sec for 2 freeze-thaw cycles. Over the course of a few treatments, the lesions resolved with no recurrence during a 6-month follow-up period.

## DISCUSSION

Epidermolytic acanthoma is a benign, asymptomatic tumor that usually presents in adulthood. Besides the solitary (isolated) form, there are also variants that can be classified as localized or disseminated. Isolated lesions may occur anywhere on the body, but the disseminated form has been described predominantly on the back and perigenital regions (6, 7). Predilection for the genitoscrotal area with multiple epidermolytic acanthomas has been increasingly recognized in the li-

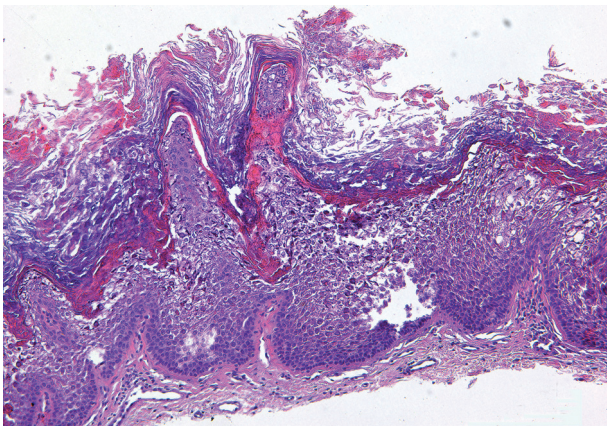


Fig. 3. Marked hyperkeratosis with orthokeratosis, papillomatosis and acanthosis. The granular layer is thickened with coarse keratohyaline granules. There is separation and degeneration of cells in the granular layer with necrotic keratinocytes observed in the mid and upper epidermis. (Hematoxylin and eosin stain  $\times 100$ ).

terature (Table I) (1–3, 8–11). Two reports in the vulvar area occurring secondarily to long periods of pruritus and scratching have also been described (12, 13).

Epidermolytic hyperkeratosis represents a reactive histopathological pattern seen in inherited diseases such as congenital bullous ichthyosiform erythroderma or as an acquired or incidental finding in many skin conditions (2). Histopathologic concept has been described by Ackerman (14) and consists of the following: (i) variously sized clear spaces around nuclei in the stratum spinosum and stratum granulosum; (ii) reticulate, lightly staining, amphophilic material forming indistinct cellular boundaries; (iii) markedly thickened granular zone containing an increased number of small and large, irregularly shaped, basophilic keratohyaline-like bodies and amorphous eosinophilic trichohyaline-like bodies; and (iv) compact hyperkeratosis (14). Ultrastructural studies have shown abnormal clumping of tonofilaments and intracellular vacuolization, as well as premature cornification of keratinocytes (15). Immunohistochemical analysis reveals decreased amounts of keratin 1 and 10 in the lesions compared with perilesional normal skin (5).

The pathogenesis of epidermolytic acanthoma is not clear. Different contributing factors have been reported, including trauma (such as friction, scratching, and tight clothing), ultraviolet light, radiation and immunosuppression. Although HPV has been suggested as a cause in some reports, immunohistochemical and molecular studies have failed to detect viral genome in lesions of both genital and extragenital origin (4, 5). The most plausible explanation at this time would be that focal epidermolytic hyperkeratosis occurs secondarily to somatic mutations of the keratinocytes involving keratin 1 or keratin 10 on exposure to trauma or other environmental triggering factors.

The genital location of this condition could be cosmetically disturbing and cause anxiety and concern about

Table I. Characteristics of patients with perigenital epidermolytic acanthomas based on a review of the literature

Study	Age (years)/	
	Sex	Location
Shapiro & Baraf (1)	49/M	Anus
	36/M	Scrotum
	39/M	Scrotum
Nizuma (2)	42/M	Scrotum
Banky et al. (3)	44/M	Scrotum
Reguiari et al. (8)	54/M	Scrotum, perineum, buttocks
Jang et al. (9)	57/M	Scrotum
Proenca & Michalany (10)	52/M	Scrotum
	68/M	Scrotum
Fukada & Saito (11)	52/M	Scrotum
Quinn & Young (12)	75/F	Vulva
	40/F	Vaginal wall
De Coninck et al. (13)	62/F	Vulva

Table II. Differential diagnosis of warty scrotal lesions with and without human papilloma virus (HPV) infection

Diagnosis	Epidermolytic acanthoma	Viral warts	Bowenoid papulosis	Molluscum contagiosum
HPV typing	–	+	+	–
Histology	Clear spaces in the granular layer with thickening and indistinct cellular boundaries, hyperkeratosis, acanthosis, papillomatosis	Orthokeratosis and parakeratosis, papillomatosis, acanthosis, hypergranulosis, and koilocytosis	Circumscribed epidermal proliferation composed of pleomorphic cells with clumped nuclei and numerous occasionally abnormal mitoses	Epidermis grows down into the dermis as multiple closely packed lobules containing large intracytoplasmic inclusion bodies
Location	Anywhere on the body	Anywhere on the body	Primarily groin and perianal	Anywhere on the body

sexually transmitted diseases. The warty appearance of individual lesions arising in scrotal, vulvar, or perigenital skin may lead to clinical confusion with genital warts, molluscum contagiosum, or bowenoid papulosis (Table II). The incidence of epidermolytic acanthoma in the general population is unknown; it may be misdiagnosed and treated as HPV infection.

Treatment is not necessary since the lesions are benign. If distressing to the patient, focused cryodestruction with liquid nitrogen cryoprobe may be used, as in our two patients. This procedure is less painful and more effective than traditional open spray cryosurgery as the probe is applied directly to the lesions, allowing focused destruction, deeper penetration and minimal lateral spread. For larger lesions, curative surgical excision may be considered.

## REFERENCES

- Shapiro L, Baraf CS. Isolated epidermolytic acanthoma. A solitary tumor showing granular degeneration. *Arch Dermatol* 1970; 101: 220–223.
- Niizuma K. Isolated epidermolytic acanthoma: a histological study. *Dermatologica* 1979; 159: 30–36.
- Banky JP, Turner RJ, Hollowood K. Multiple scrotal epidermolytic acanthomas; secondary to trauma? *Clin Exp Dermatol* 2004; 29: 489–491.
- Leonardi C, Zhu W, Kinsey W, Penneys NS. Epidermolytic acanthoma does not contain human papillomavirus DNA. *J Cutan Pathol* 1991; 18: 103–105.
- Cohen PR, Ulmer R, Theriault A, Leigh IM, Duvic M. Epidermolytic acanthomas: clinical characteristic and immunohistochemical features. *Am J Dermatopathol* 1997; 19: 232–241.
- Nakagawa T, Nishimoto M, Takaiwa T. Disseminated epidermolytic acanthoma revealed by PUVA. *Dermatologica* 1986; 173: 150–153.
- Sanchez-Carpintero I, Espana A, Idoate MA. Disseminated epidermolytic acanthoma probably related to trauma. *Br J Dermatol* 1999; 141: 728–730.
- Regui a Z, Cribier B, Derancourt C, Perceau G, Bernard P. Multiple spreading epidermolytic acanthomas of the genital and perigenital skin. *Dermatology* 2005; 211: 152–154.
- Jang BS, Jang HS, Park HJ, Kim MB, Oh CK, Kwon KS. Multiple scrotal epidermolytic acanthomas successfully treated with topical imiquimod. *J Dermatol* 2007; 34: 267–269.
- Proenca NG, Michalany N. Epidermolytic acanthoma of the scrotum. *An Bras Dermatol* 2006; 81: S270–S272.
- Fukada H, Saito R. Verruciform xanthoma in close association with isolated epidermolytic acanthoma: a case report and review of the Japanese dermatological literature. *J Dermatol* 2005; 32: 464–468.
- Quinn TR, Young RH. Epidermolytic hyperkeratosis in the lower female genital tract: an uncommon simulant of mucocutaneous papillomavirus infection – a report of two cases. *Int J Gynecol Pathol* 1997; 16: 163–168.
- De Coninck A, Willemsen M, De Dobbeleer G, Roseeuw D. Vulvar localisation of epidermolytic acanthoma. A light- and electron-microscopic study. *Dermatologica* 1986; 172: 276–278.
- Ackerman AB. Histopathologic concept of epidermolytic hyperkeratosis. *Arch Dermatol* 1970; 102: 253–259.
- Hirone T, Fukushima R. Disseminated epidermolytic acanthoma. Nonsystematized multiple verrucoid lesions showing granular degeneration. *Acta Derm Venereol* 1973; 53: 393–402.