

Pyoderma Vegetans: A Case for Discussion

Esra Adışen, Fulya Tezel and Mehmet Ali Gürer

Department of Dermatology, Gazi University Faculty of Medicine, TR-06500 Beşevler, Ankara, Turkey. E-mail: eozsoy@gazi.edu.tr

Accepted September 11, 2008.

Sir,

Pyoderma vegetans (dermatitis vegetans) is a chronic inflammatory dermatosis first described by Hallopeau in 1898 (1). Cutaneous lesions are typically vesicopustular, exudative and vegetative, and are usually localized on the face, scalp, axilla, genitalia and, less commonly, on the abdomen, trunk and distal parts of the extremities. In 1949, McCarthy reported a case with oral mucosa lesions without associating cutaneous findings and named the condition "pyostomatitis vegetans" (2). Today, these two diseases are considered to be different manifestations of the same entity. There is a lack of consensus on the nomenclature of the condition; it is named "pyoderma vegetans" and "pyodermatitis-pyostomatitis vegetans" (3, 4). The disease is believed to appear in immunosuppression states due to severe bacterial colonization or epithelial invasion (5–9). Nevertheless, it has been described infrequently in immunocompetent patients (5, 6, 10). We describe here an otherwise healthy 74-year-old patient with typical clinical and histopathological findings of pyoderma vegetans, in order to highlight the differential diagnosis of this rare entity from other chronic vegetative lesions.

CASE REPORT

A 74-year-old man presented to our clinic with a painful lesion on the right foot that had been present for 2 months and was increasing in size. His medical history revealed that a similar lesion had occurred 2 years previously on the dorsum of the right foot and had regressed with topical corticosteroids, antihistamines and various antibiotic treatments. His past medical and family history was otherwise unremarkable. On dermatological examination, a 13 × 7 cm well-circumscribed plaque with ulcero-vegetative appearance, occasional yellow and green crusts and erythematous borders involving nearly the entire dorsum of the

right foot was observed (Fig. 1a). The patient stated that the lesion was very painful. The rest of the physical examination was within normal limits. Complete blood count, kidney function tests, liver function tests, blood glucose level and serum electrolyte levels were within normal limits. The erythrocyte sedimentation rate was 30 mm/h. Wound culture taken from the lesion was positive for *Escherichia coli* and diphtheroids. Yeast culture was negative. Further laboratory evaluation using polymerase chain reaction analysis of two different biopsied tissues taken from the patient revealed negative mycobacterium tuberculosis DNA. Evaluation of cutaneous biopsy specimens revealed pseudoepitheliomatous hyperplasia, fibrosis, vascular proliferation, and a mononuclear predominant infiltration with occasional neutrophils in dermis. Periodic acid-schiff (PAS) and lipophosphoglycan stains were negative. Histopathological examination of a second specimen taken from the deeper layer of the lesion revealed neutrophils in the epidermis and an ulcer floor composed of fibrin and irregular squamous epithelial hyperplasia. The dermal compartment showed oedema, fibrosis, vascular proliferation, and neutrophil infiltration in a few vascular walls without associating fibrinoid necrosis, and a plasma cell predominant inflammation with occasional neutrophils in the papillary dermis. Immunohistochemical examination with CD68 stain revealed no granuloma formation. Based on the clinical and histopathological findings, the patient was diagnosed as having pyoderma vegetans. Therapy was initiated with fluocortolone, 60 mg/day, and ciprofloxacin, 500 mg twice daily. The patient's pain subsided within one week of commencing treatment. At the same time, the amount of wound exudate decreased appreciably. Over the next 6 weeks, his lesion continued to improve, and the steroid dose was gradually tapered down (Fig. 1b). We will continue to follow up the patient on an ongoing basis for supportive care and evaluation of a possible underlying disease.

DISCUSSION

Pyoderma vegetans is more commonly seen in middle-aged people (3, 4). The male:female ratio is 3:1 (3, 9). This disease of unknown aetiology is believed to

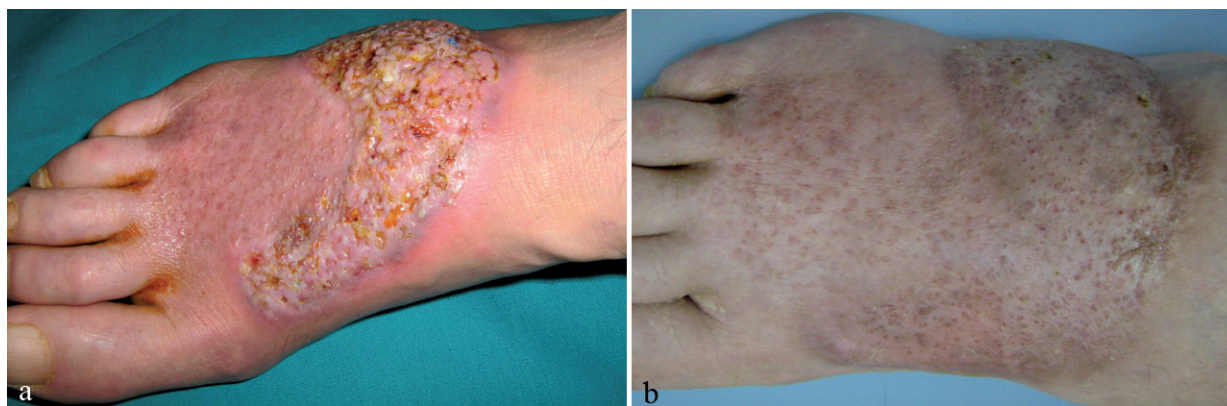


Fig. 1. A circumscribed ulcero-vegetative plaque with erythematous elevated borders and occasional yellow and green crusts involving almost the whole dorsum of the right foot (a). Improvement in the lesion after 6 weeks of systemic steroid treatment (b).

be related to an excessive inflammatory reaction in response to bacterial infections, tattoos, foreign body reactions and halogens in patients with neutrophilic dermatoses or in the states of immunodeficiency (3, 4, 7, 11, 12). During this inflammation, released connective tissue activating proteins are thought to stimulate matrix formation, fibroblast and epidermal cell proliferation (7).

In the literature, the disease is reported to coexist with a variety of diseases, including ulcerative colitis, diffuse T-cell lymphoma, alcoholism, chronic malnutrition, HIV infection and chronic myeloid leukaemia (6, 7, 11–16). However, the disease has also been reported in healthy patients (5, 6, 10), as in our case. Many authors (5, 6, 8, 10) consider pyoderma vegetans to be a highly specific marker for an intestinal disorder and recommend that these patients should be followed on a routine basis and evaluated for an underlying inflammatory bowel disease (3, 4, 7, 9, 11). New markers, such as faecal calprotectin are non-invasive, simple, sensitive and specific parameters in detecting inflammatory bowel diseases and they can be used for this purpose (17). Although the development of squamous cell carcinoma and colon cancer after the diagnosis of pyoderma vegetans has been reported in the literature (3), there is no consensus on screening this patient population for an underlying immunodeficiency or malignancy. Therefore, reports similar to ours are necessary in order to develop an appropriate follow-up schedule for pyoderma vegetans.

The most common microbial agents isolated are staphylococci and beta-haemolytic streptococci. Other suspected agents are *Klebsiella*, *Bacteroides*, *enterococci*, *Pseudomonas aeruginosa* and *Corynebacterium* (4, 6–9). A case associated with *Trichophyton mentagrophytes* has also been reported (10). Some authors believe that the microbiological agent is not primarily responsible for the disease and the infection develops secondary to an immune dysfunction (6, 10). In support of this theory, in some of cases serum immunoglobulin levels were decreased and phagocytic dysfunction was observed (5, 8, 10, 12–14). The condition also fails to respond to antibiotic treatment alone, which further supports this theory (3–5).

Cutaneous lesions start as erythematous papulopustular lesions that rapidly coalesce into annular vegetative plaques with elevated borders. These lesions are usually localized in face, scalp, axilla, genitalia and, less commonly, in abdomen, trunk and distal parts of extremities and usually heal with post-inflammatory hyperpigmentation (3–6, 9). The lesions tend to be localized in intertriginous areas where moisture and friction make an ideal growth field for microbial colonization. Therefore both the localization of the lesions and the defence mechanisms of the host may be involved in the aetiopathogenesis of the disease. Skin involvement can occur before, during or after oral mucosa involvement

(3, 4, 6, 9). Oral mucosa lesions usually present as white plaques or pustules (3, 6, 9). In some cases various levels of pain accompany the lesion.

The diagnosis of the disease depends primarily on the exclusion of other diseases that can present as chronic vegetative lesions, including invasive mycosis, botryomycosis, pyoderma gangrenosum, iododerma, pemphigus vegetans, tuberculosis cutis verrucosa and squamous cell carcinoma (3, 4, 7–9). The histopathological hallmarks of pyoderma vegetans are pseudoepitheliomatous hyperplasia, epidermal and dermal neutrophilia, or eosinophil-bearing epidermal or dermal abscesses. Typically, there is no granuloma formation (3, 4, 8).

There has been much debate as to whether pyoderma vegetans and pyoderma gangrenosum are variants of a single disease (4, 7, 8). Deep-seated painful subcutaneous nodules or superficial hemorrhagic pustules that rapidly turn into ulcers with necrotic floor, hemorrhagic and purulent exudate can be the first signs of pyoderma gangrenosum. In almost all cases, the ulcer is circumscribed with an erythematous halo, and the borders of the ulcer are typically elevated and inflammatory (3, 4, 8). The lack of these characteristic clinical features should favour a diagnosis of pyoderma vegetans (8). In pyoderma gangrenosum, trauma-like pathergy test, prick test or biopsy can cause new lesion formation. In our patient, multiple biopsies or shaving did not produce new lesions and wound cultures were positive in accordance with the features of pyoderma vegetans. Moreover, pseudoepitheliomatous hyperplasia, which may or may not be present in pyoderma gangrenosum, was observed on histological examination of our patient (8).

The lesion can heal spontaneously, but usually recurs and becomes chronic. There are no standard treatment modalities. Case reports show the importance of treating the underlying disease and also the need for an appropriate and supportive topical wound care. In cases with positive bacterial and yeast cultures, specific antimicrobial treatment is necessary (3–5, 11, 15, 16). In cases associated with ulcerative colitis, treatment of both illnesses should be planned together since they have a parallel course (6, 7, 11). Other treatment options include intralesional corticosteroids, systemic corticosteroids, dapsone, isotretinoin, cyclosporine, laser ablation, and excision (3, 4, 6, 9, 12). Antibiotic treatment, local wound care and systemic steroids controlled the disease in our case.

The authors declare no conflict of interest.

REFERENCES

1. Hallopeau M. Pyodermitis Vegetante, ihre Beziehungen Zur dermatitis herpetiformis und dem Pemphigus vegetan. Arch Dermatol Syph 1898; 19: 77–88.
2. McCarthy FP. Pyosomatitis Vegetans. report of three cases. Arch Dermatol Syph 1949; 60: 750–764.

3. Hegarty AM, Barrett AW, Scully C. Pyostomatitis vegetans. *Clin Exp Dermatol* 2004; 29: 1–7.
4. Nigen S, Poulin Y, Rochette L, Levesque MH, Gagne E. Pyodermatitis-pyostomatitis vegetans: two cases and a review of the literature. *J Cutan Med Surg* 2003; 7: 250–255.
5. Su WP, Duncan SC, Perry HO. Blastomycosis-like pyoderma. *Arch Dermatol* 1979; 115: 170–173.
6. Brinkmeier T, Frosch PJ. Pyodermatitis-pyostomatitis vegetans: a clinical course of two decades with response to cyclosporine and low-dose prednisolone. *Acta Derm Venereol* 2001; 81: 134–136.
7. Bianchi L, Carozzo AM, Orlandi A, Campione E, Hagman JH, Chimenti S. Pyoderma vegetans and ulcerative colitis. *Br J Dermatol* 2001; 144: 1224–1227.
8. Papadopoulos AJ, Schwartz RA, Kapila R, Samady JA, Ruszczak Z, Rao BK, et al. Pyoderma vegetans. *J Cutan Med Surg* 2001; 5: 223–227.
9. Konstantopoulou M, O'Dwyer EM, Steele JC, Field EA, Lewis MA, Macfarlane AW. Pyodermatitis-pyostomatitis vegetans complicated by methicillin-resistant *Staphylococcus aureus* infection. *Clin Exp Dermatol* 2005; 30: 666–668.
10. Skorepová M, Stuchlík D. Chronic pyoderma vegetans triggered by *Trichophyton mentagrophytes*. *Mycoses* 2006; 49: 143–144.
11. Harish K, Varghese T, Najeeba R, Harikumar R. Pyoderma vegetans and ulcerative colitis. *J Postgrad Med* 2006; 52: 302–303.
12. Rieder JM, Moresi JM, Parsons JK. Pyoderma vegetans of the penis. *J Urol* 2004; 171: 354.
13. Welch KJ, Burke WA, Park HK. Pyoderma vegetans: association with diffuse T-cell lymphoma (large cell type). *J Am Acad Dermatol* 1989; 20: 691–693.
14. Dutta TK, James J, Baruah MC, Ratnakar C. Blastomycosis-like pyoderma in a case of chronic myeloid leukaemia. *Postgrad Med J* 1992; 68: 363–365.
15. Boyd AS, Zemtsov A. A case of pyoderma vegetans and the follicular occlusion triad. *J Dermatol* 1992; 19: 61–63.
16. Fujita M, Okamoto S. A case of pyoderma vegetans associated with acne conglobata. *J Dermatol* 1990; 17: 429–434.
17. Angriman I, Scarpa M, D'Inca R, Basso D, Ruffolo C, Polese L, et al. Enzymes in feces: useful markers of chronic inflammatory bowel disease. *Clin Chim Acta* 2007; 381: 63–68.