

LETTERS TO THE EDITOR

Fatal Case of Darier's Disease with Recurrent Severe Infections

Etsuko Okada, Yayoi Nagai, Sei-ichiro Motegi, Atsushi Tamura and Osamu Ishikawa

Department of Dermatology, Gunma University Graduate School of Medicine, 3-39-22 Showa-machi, Maebashi, Gunma 371-8511, Japan.

E-mail: eokada@showa.gunma-u.ac.jp

Accepted September 29, 2008.

Sir,

Darier's disease (DD) is an uncommon hereditary cutaneous disease that is difficult to manage, especially in adolescence. It has been reported that the disease is caused by mutations in a gene mapped onto a single locus on chromosome 12q23-q24.1, which encodes a sarco/endoplasmic reticulum calcium ATPase pump (SERCA2) (1). DD has characteristic clinical and histological findings; however, it can sometimes be misdiagnosed or overlooked. We report here a fatal case of DD that had been misdiagnosed as atopic dermatitis for 11 years in another institution. The patient had repeated bacterial and psychiatric disorders.

CASE REPORT

A 25-year-old Japanese man with a painful erosive skin eruption and high fever presented at our hospital on 16 October 2004. He had been suffering from a skin eruption, which had been diagnosed and treated as atopic dermatitis, since the age of 14 years. Over the years, corticosteroid ointments had been used without significant clinical response.

Physical examination revealed widespread erythema over his entire body. He also had odorous erosive lesions on his trunk, buttocks and lower extremities. Our initial diagnosis was atopic dermatitis with severe secondary infection. He was admitted to our department. Bacterial cultures from his erosive skin lesions detected *Streptococcus aureus*, *Pseudomonas aeruginosa* and *Klebsiella pneumoniae*. Abnormal laboratory findings included leukocytosis (13,500/mm³), increased levels of C-reactive protein (CRP) (9.4 mg/dl) and hypoproteinaemia (total protein 5.8 g/dl, albumin 2.0 g/dl). Treatment with oral prednisolone 30 mg/day and systemic and topical antibacterial agents resulted in a partial response. Several days later, numerous warty hyperkeratotic papules appeared on his face, trunk and limbs (Fig. 1). Furthermore, careful examination revealed V-shaped notches at the free edges of his finger nails and longitudinal streaks in some finger nails. There were no palmar pits or oral mucosal lesions.

A biopsy specimen taken from his chest showed marked hyperkeratosis with parakeratosis, suprabasal clefts and acantholysis associated with corps ronds and grains (Fig. 2). His family history revealed that his mother and sister also had multiple keratotic papules. We then established a diagnosis of DD. Treatment with oral etretinate, 40 mg/day, resulted in a partial improvement. He was discharged on 25 July 2005.

Six weeks later, he was readmitted because of the recurrence of painful erosive skin lesions accompanied by a high fever and dyspnoea (Fig. 3). The results of bacterial cultures from erosive skin revealed *P. aeruginosa* and others. Treatment with intravenous minocycline hydrochloride 200 mg/day and topical application of antibacterial ointment were effective in improving the infection. The papules and erythema remained

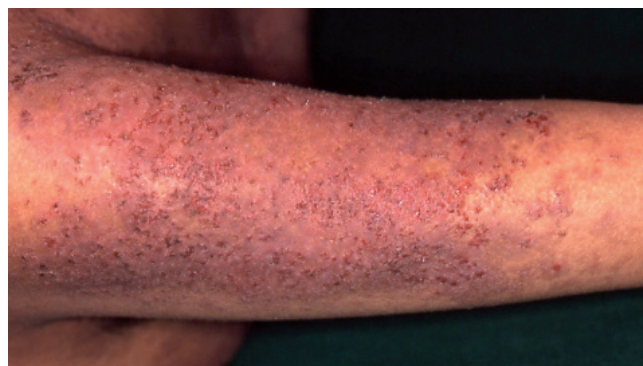

Fig. 1. One week after admission. Disseminated keratotic papules were noted on the patient's trunk and extremities.

unchanged, and oral etretinate 40 mg/day and cyclosporine 200 mg/day were ineffective. Etretinate was increased to 70 mg/day, and gentamicin ointment was applied topically to the entire body. Erosions of the trunk gradually improved, but then recurred. We tried ablation treatment and a split thickened skin graft on his left lower extremity on 11 April 2006. The grafted area almost healed for a few weeks; however, haemorrhagic and erosive lesions developed again. In addition, Kaposi's varicelliform eruptions developed three times, accompanied by high fever and rapidly extended erosive skin. Each time, the patient received intravenous acyclovir 750 mg/day.

Laboratory tests disclosed persistent hypoalbuminaemia ranging from 0.9 to 1.7 mg/dl, despite a high-calorie diet and

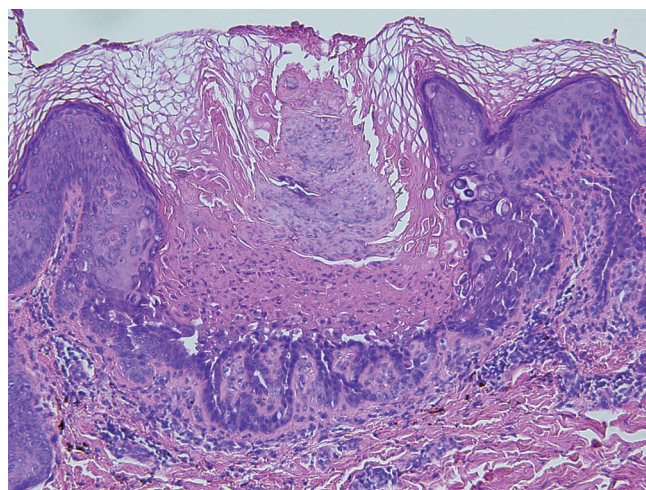


Fig. 2. Marked hyperkeratosis with parakeratosis, suprabasal clefts and acantholysis associated with dyskeratosis including corps ronds and grains. (Haematoxylin and eosin (H&E) stain $\times 200$).

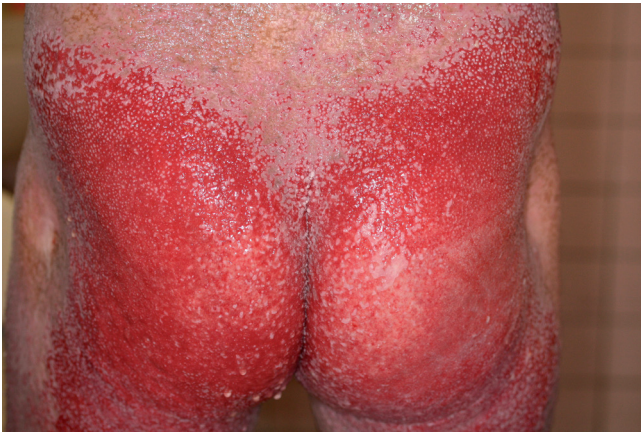

Fig. 3. Widespread flush of the entire body. Odorous erosive lesions affected the trunk, buttocks and lower extremities.

intravenous albumin. Since intestinal investigations revealed no abnormalities, we considered that the hypoalbuminaemia was caused by his severely eroded skin.

In May 2006, the skin lesions worsened so rapidly that intravenous antibiotic agents were administered again. However, acute renal failure developed secondary to sepsis and dehydration. The patient died on 30 July 2006.

DISCUSSION

The severity of DD is unpredictable, but it usually runs a chronic course with exacerbations and remissions (2, 3). Exacerbations can be caused by hot weather, excessive sun exposure, medications, steroids or mechanical trauma. The incidence of mucous or gastrointestinal lesions varies from 15% to 50% (4).

There are several clinical variations of DD, including hypertrophic, linear or zosteriform and vesiculo-bullous types (3, 5–9). In the last form, vesicles and bullae develop in the exposed skin, and are often induced by high humidity, physical or surgical stress and bacterial or viral cutaneous infections. Localized blistering is not uncommon in DD, but a widespread vesiculo-bullous type is rare. Our case might be classified as this type, and undoubtedly a secondary bacterial infection colonizing the keratotic debris must have induced the intractable lesions.

Although there have been some reports describing selective immune defects in patients with Darier's disease, no consistent or specific abnormality has been demonstrated (10). Nikkels et al. (11) reported a fatal case with severe HSV skin infection followed by HSV-related pneumonia, gastrointestinal involvement and acute respiratory distress syndrome.

Oral retinoids have proven to be quite effective in DD (12). However, the management of widespread vesiculo-bullous DD is difficult because oral retinoids may increase skin fragility. Other topical medications with 5-fluorouracil, tazarotene or calcipotriol have been

used with variable outcomes. In recalcitrant cases, systemic administration of cyclosporine, contraceptives and diazepam have also been reported (12, 13). Oral steroids or cyclosporine reduces inflammation in patients with eczematized conditions (15), but papules and erosions are often unresponsive. A recent study showed that topical aminoglycosides brought about remission in a patient with Hailey-Hailey disease by reversing the effects of pathogenic nonsense mutations (14). As in this study, we tried topical gentamicin ointment. Exudation gradually decreased; however, this was not enough to make the skin lesions subside. Photodynamic therapy, excision, electrodesiccation, dermabrasion, abrasion with carbon dioxide or erbium YAG laser have been reported to have successful outcomes (3). Dermabrasion and split thickened skin graft were not effective in our patient who eventually died due to severe systemic complications.

REFERENCES

1. Sakuntabhai A, Ruiz-Perez V, Carter S, Jacobsen N, Burge S, Monk S, et al. Mutations in ATP2A2, encoding a Ca²⁺ pump, cause Darier's disease. *Nat Genet* 1999; 21: 271–277.
2. Burge SM, Wilkinson JD. Darier-White disease: a review of the clinical features in 163 patients. *J Am Acad Dermatol* 1992; 27: 40–50.
3. Sehgal VN, Srivastava G. Darier's (Darier-White) disease/keratosis follicularis. *Int J Dermatol* 2005; 44: 184–192.
4. Robaee AA, Hamadah LR, Khuroo S, Alfadley A. Extensive Darier's disease with esophageal involvement. *Int J Dermatol* 2004; 43: 835–839.
5. Mei S, Amato L, Gallerani I, Perrella E, Caproni M, Palleschi GM, Fabbri P. A case of vesiculo-bullous Darier's disease associated with bipolar psychiatric disorder. *J Dermatol* 2000; 27: 673–676.
6. Telfer NR, Burge SM, Ryan TJ. Vesiculo-bullous Darier's disease. *Br J Dermatol* 1990; 122: 831–834.
7. Hori Y, Tusuru N, Niimura M. Bullous Darier's disease. *Arch Dermatol* 1982; 118: 278–279.
8. Colver GB, Gawkrödger DJ. Vesiculo-bullous Darier's disease. *Br J Dermatol* 1992; 126: 416–417.
9. Speight EL. Vesiculo-bullous Darier's disease responsive to oral prednisolone steroids. *Br J Dermatol* 1998; 139: 934–935.
10. Partrizi A, Ricci G, Neri I, Specchia F, Varotti C, Masi M. Immunological parameters in Darier's disease. *Dermatologica* 1989; 178: 138–140.
11. Nikkels AF, Beauthier F, Quatresooz P, Pierard GE. Fatal herpes simplex virus infection in Darier disease under corticotherapy. *Eur J Dermatol* 2005; 15: 293–297.
12. Burge S. Management of Darier's disease. *Clin Exp Dermatol* 1999; 24: 53–56.
13. Shahidullah H, Humphreys F, Beveridge GW. Darier's disease: severe eczematization successfully treated with cyclosporin. *Br J Dermatol* 1994; 131: 713–716.
14. Kallermayer R, Szigeti R, Keeling KM, Bedekovics T, Bedwell DM. Aminoglycosides as potential pharmacogenetic agents in the treatment of Hailey-Hailey Disease. *J Invest Dermatol* 2006; 126: 229–231.