

Labial Agglutination in a Prepubertal Girl: Effect of Topical Oestrogen

Marie Hjerrild Velander, Dorthe Bisgaard Mikkelsen and Anette Bygum*

Department of Dermatology, Odense University Hospital, DK-5000 Odense C, Denmark. *E-mail: anette.bygum@ouh.regionsyddanmark.dk

Accepted September 3, 2008.

Sir,

Labial agglutination in younger prepubertal girls is rather common, but it is rarely described in dermatological textbooks. Many cases are asymptomatic, but in symptomatic cases the preferred treatment is topical oestrogen therapy. The cause of labial agglutination appears to be a mild inflammatory condition in a child with a thin layer of labial epithelial cells secondary to a low oestrogen level.

CASE REPORT

A 13-month-old girl was referred to our hospital with a noticeable labial agglutination, detected recently by her parents who feared retention of urine. Examination of the vulva showed an almost complete agglutination of the labia minora fused with a thin, pale and shining membrane starting posteriorly (Fig. 1A). A 5-mm opening in the agglutination anteriorly allowed free voiding. No signs of lichen sclerosus et atrophicus were seen in the surrounding skin.

Treatment with betamethasone dipropionate (Diproderm[®], Schering Plough, Ballerup, Denmark) was started and continued for 6 weeks without any effect. It appeared as though the condition progressed, with the anterior opening appearing even smaller and the surrounding skin becoming red and irritated. Diproderm[®] was ceased and treatment with a magistral formulation of an oestrogen-containing cream (containing 0.625 mg/g of conjugated oestrogens, as in Premarin[®] cream, Wyeth Pharmaceuticals, Madison, US) was applied at the

agglutination once daily. After a few days the effects of treatment were seen, and after one week the labial agglutination had completely dissolved (Fig. 1B). The treatment was continued for a further week, after which the agglutination had completely dissociated. After 6 months the girl was again referred to our hospital because of a gradual recurrence of the labial agglutination. The oestrogen-containing cream was re-instituted this time with the commercial pharmaceutical EstroGel[®] (estradiol 0.6 mg/g in a gel containing ethanol, Leiras, Turku, Finland). After 2 weeks of treatment with EstroGel[®] no effect was seen at the agglutination but a quite remarkable local irritating effect occurred. EstroGel[®] was ceased and treatment with the magistral Premarin[®]-like cream was instituted. After 4 weeks of treatment only a few millimetres of agglutination remained posteriorly. The treatment was continued for a further 2 weeks.

DISCUSSION

Labial agglutination, also known as labial adhesion, is a thin membranous fusion of the labia minora of varying length. It originates at the posterior fourchette and progresses towards the clitoris. If complete, the fusion conceals the vaginal opening. If partial, as in our case, the adhesion occurs near the posterior fourchette or at times midway between the posterior fourchette and clitoris (1). Most children with minor agglutination of the labia are asymptomatic. When symptoms occur, they are often related to interference with voiding, such as dysuria or altered urinary stream, or symptoms related to the accumulation of urine behind the agglutination predisposing to vaginal or urinary tract infections (2). The agglutination in our case was almost complete, with a risk of dysuria and accumulation of urine as the parents feared. To minimize the risk of vaginal or urinary tract infections treatment was begun.

The condition is rather common but rarely described in dermatological textbooks. The estimated labial adhesion rate in girls is about 1.8%, with a peak incidence of 3.3% at 13–23 months of age (3). However, in a single study systematically studying genital findings in prepubertal girls, a prevalence as great as 38.9% has been found, including very small adhesions of 2 mm or less detected only through the colposcope (4).

The cause of labial agglutination appears to be a mild inflammatory condition in a child with a thin layer of labial epithelial cells secondary to a low oestrogen level. When vulvitis or another inflammatory condition occurs,

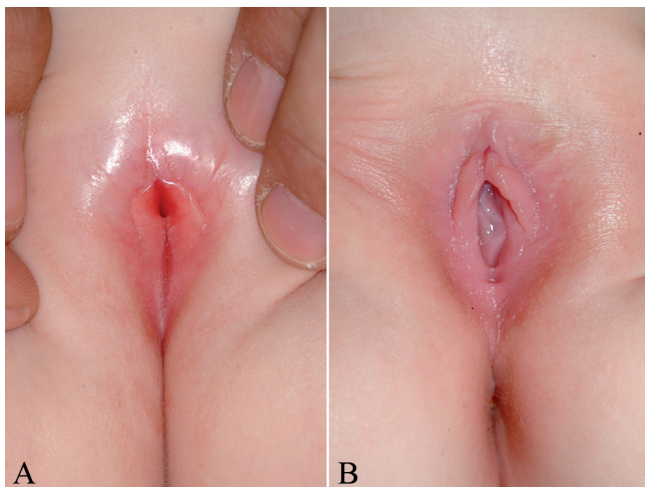


Fig. 1. (A) Almost complete labial agglutination with a thin, pale, shiny membrane starting posteriorly. (B) After 1-week treatment with oestrogen-containing cream the labial agglutination had completely dissolved.

the thinner layer of epithelia cells can denude and apposition of the eroded areas can result in agglutination of the labia (3). The peak incidence at 13–23 months of age might be a result of the combination of the children's low oestrogen level and irritated skin caused by nappy use. In the study by Leung et al. (3) it was noticed that the incidence of labial agglutination was lower in children younger than 3 months of age, as they still might be influenced by maternal oestrogens. In our case there was no previous history of vulvitis; therefore we do not know why our patient developed labial agglutination, except perhaps due to the use of nappies.

Labial agglutination, as such, is not a developmental anomaly and therefore is not associated with abnormalities of the internal genitalia or urinary system. Some authors have suggested that in some cases labial agglutination could be an early stage of lichen sclerosus (5). In our case we were aware of this possibility from the beginning, but found nothing which indicated that the labial agglutination was caused by lichen sclerosus. Doctors should be aware that in rare cases labial agglutination can be a sign of sexual abuse (6).

If the labial agglutination is asymptomatic it is recommended to wait for spontaneous resolution, which will often happen when the oestrogen level rises at the onset of puberty. Symptomatic or complete labial agglutination is treated with topical oestrogen therapy (Premarin® vaginal cream with a concentration of conjugated oestrogens of 0.625 mg/g) applied 1–3 times daily in 1–8 weeks. The success rate differs from 47% to 100% depending on treatment frequency and length (7–9). The recurrence rate of labial fusion observed in a retrospective study of 109 girls was 41% (8). An alternative medical treatment is to apply a thin layer of 0.05% betamethasone cream twice daily along the adhesion line for 4–6 weeks (10). The success rate of this treatment is 68%, and there is a frequency of recurrence at 23% in a maximal follow-up period of 24 months. Topical steroid treatment was tried in our case without success. If the child does not respond to topical treatment, the adhesion can be separated mechanically, e.g. manual separation under topical anaesthesia with EMLA® (eutectic mixture of lidocaine and prilocaine). A study of 289 prepubertal girls reported that labial separation under topical anaesthesia was attempted in 138 patients and was successful in 112 patients (81%) (7). In cases of very dense and fibrous agglutination, surgical separation under general anaesthesia is an option.

The different treatments have potential side-effects. Topical oestrogen therapy may cause vulval pigmentation, erythema, fine downy labial hair and breast tender-

ness or transient breast enlargement (9, 11). In a few cases vaginal bleeding have been reported. Our patient developed some redness and oedema in the treated area of the vulva secondary to the oestrogen treatment. To minimize the possibility of side-effects the oestrogen cream should be applied precisely to the agglutination. No side-effects to the betamethasone cream used for this indication have been described. Manual separation may be physically and emotionally traumatic to the patient (11). Surgical separation can cause development of fibrous tissue and thicken adhesions.

It is important to educate parents and carers in the awareness of the benign nature of the agglutinations, the causative mechanisms and the natural resolution. Parents should be educated to observe for signs of urethritis and urinary tract infections and for recurrence of the labial agglutination. Proper technique in the application of ointment must be demonstrated.

The authors declare no conflict of interest.

REFERENCES

1. Starr NB. Labial adhesions in childhood. *J Pediatr Health Care* 1996; 10: 26–27.
2. Bacon JL. Prepubertal labial adhesions: evaluation of a referral population. *Am J Obstet Gynecol* 2002; 187: 327–332.
3. Leung AK, Robson WL, Tay-Uyboco J. The incidence of labial fusion in children. *J Pediatr Child Health* 1993; 29: 235–236.
4. McCann J, Wells R, Simon M, Voris J. Genital findings in prepubertal girls selected for nonabuse: a descriptive study. *Pediatrics* 1990; 86: 428–439.
5. Gibbon KL, Bewley AP, Salisbury JA. Labial fusion in children: a presenting feature of genital lichen sclerosus? *Pediatr Dermatol* 1999; 16: 388–391.
6. Berenson AB, Chacko MR, Wiemann CM, Mishaw CO, Friedrich WN, Grady JJ. A case-control study of anatomic changes resulting from sexual abuse. *Am J Obstet Gynecol* 2000; 182: 820–834.
7. Muram D. Treatment of prepubertal girls with labial adhesions. *J Pediatr Adolesc Gynecol* 1999; 12: 67–70.
8. Schober J, Dulabon L, Martin-Alguacil N, Kow LM, Pfaff D. Significance of topical estrogens to labial fusion and vaginal introital integrity. *J Pediatr Adolesc Gynecol* 2006; 19: 337–339.
9. Leung AK, Robson WL, Kao CP, Liu EK, Fong JH. Treatment of labial fusion with topical estrogen therapy. *Clin Pediatr* 2005; 44: 245–247.
10. Myers JB, Sorensen CM, Wisner BP, Furness PD, Passamaneck M, Koyle MA. Betamethasone cream for the treatment of pre-pubertal labial adhesions. *J Pediatr Adolesc Gynecol* 2006; 19: 407–411.
11. Kumetz LM, Quint EH, Fisseha S, Smith YR. Estrogen treatment success in recurrent and persistent labial agglutination. *J Pediatr Adolesc Gynecol* 2006; 19: 381–384.