

## Tortuous Innominate Artery Simulating a Supraclavicular Subcutaneous Tumour

Tohru Tanigawa<sup>1</sup>, Atsushi Shinohara<sup>2</sup>, Takashi Sato<sup>3</sup>, Jun-ichi Yamashita<sup>4</sup> and Shigeru Inafuku<sup>1</sup>

<sup>1</sup>Department of Otolaryngology, Aichi Medical University, <sup>2</sup>Department of Oral and Maxillofacial Surgery, Aichi Medical University, <sup>3</sup>Department of Otolaryngology, Aichi Gakuin University and <sup>4</sup>Department of Breast Oncology, Okazaki City Medical Association Public Health Center, Aichi, Japan.

E-mail: tanigawa@aichi-med-u.ac.jp

Accepted September 8, 2008.

Sir,

When a subcutaneous mass is noticed in the anterior neck of a patient, we usually consider a diagnosis of skin tumour, lymph node swelling (1), or thyroid tumour (2). Vascular diseases, such as a tortuous major artery, aneurysm, or haemangioma are extremely rare (3–7).

We describe here a case of a right tortuous innominate artery in which it proved impossible to detect pulsation because of the skeleto-muscular structures shielding the affected area. If either an aspiration or an open biopsy were to be performed near a tortuous innominate artery simulating a subcutaneous mass, a major artery might be damaged, possibly with lethal consequences. We present here clinical findings that call for caution in dealing with a tortuous innominate artery simulating a supraclavicular subcutaneous tumour.

### CASE REPORT

A 73-year-old woman presented at our hospital complaining of an anterior neck mass that she had noticed only 4 weeks previously. She was not obese (BMI=19.3), nor was her medical history regarding hypertension, hyperlipidaemia and syphilis particularly remarkable. She had no dyspnoea or dysphagia, but her husky voice and severe throat discomfort were clearly alarming. A fibroscopic examination revealed no abnormality in the pharynx or larynx. We palpated a 1.5-cm subcutaneous mass in the right supraclavicular fossa (Fig. 1), but were unable to detect any obvious

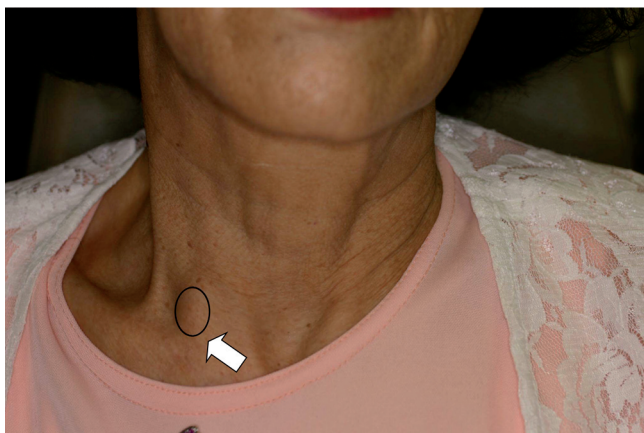

Fig. 1. A mass in the right supraclavicular fossa with the appearance of a subcutaneous tumour (arrow). Pulsation of the mass could not be detected clearly because of the patient's normal blood pressure.

pulsation of the mass. Ultrasonography revealed that our access to a view within the mass was blocked by the clavicle, which covered the lower part of the mass. Computerized tomography (CT) showed a tortuous innominate artery protruding from the mediastinal space (Fig. 2A). In addition, magnetic resonance angiography (MRA) revealed that the forward and lateral arterial bending becomes the substance of the mass (Fig. 2B). From these examinations, we diagnosed it as a tortuous innominate artery simulating a subcutaneous neck tumour. Since her symptoms were not accompanied by neurological signs, we kept the patient under careful observation for 12 months.

### DISCUSSION

This case revealed a tortuous innominate artery, which had initially been observed as a subcutaneous mass within a supraclavicular lesion. We could detect no obvious pulsation of the mass, but subsequent CT and magnetic resonance imaging (MRI) revealed a tortuous innominate artery. From our experience, when a subcutaneous tumour occurs near the clavicle, one should look for signs of an abnormal course of the innominate arteries, since their evanescent character is related to blood pressure levels (4). Initially, a radiological survey including CT, MRI, or MRA should be conducted.

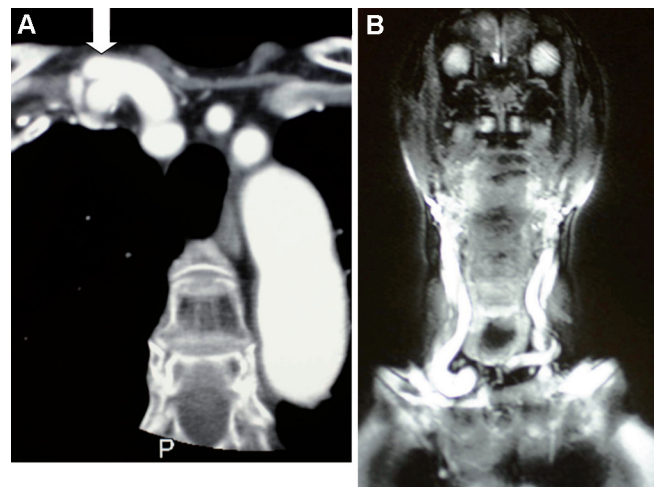


Fig. 2. (A) Computed tomography (axial image) demonstrated a tortuous innominate artery (arrow) markedly protruding from the mediastinal space into the subcutaneous tissue of the anterior neck. (B) Magnetic resonance angiography revealed that the forward and lateral arterial bending becomes the substance of the mass.

If a subcutaneous tumour occurs above the clavicle, or if the clavicle shields the mass, it is difficult to obtain detailed information about the evanescent mass by palpation or ultrasonography alone. In addition, Polachek (2) reported on a patient with a tortuous innominate artery that was compressing the right lobe of the thyroid, resulting in atrophy of its lower portion. In that case, a diagnosis of thyroid tumour had been discounted since a cold nodule of the right lobe was detected with <sup>131</sup>I scintigraphy. Buck & Siddiqui (8) reported on a tortuous carotid artery that raised the thyroid gland, thus simulating a thyroid nodule. Such reports suggest that there are occasional difficulties in distinguishing between aberrant arteries and tumour masses.

In the management of a tortuous innominate artery, careful attention should be paid to vascular anomalies if the patient has to undergo a tracheotomy. In cases of emergent tracheotomy (5) and/or percutaneous dilational tracheostomy (9), in particular, the utmost care should be taken not to damage major aberrant vessels by mistake. We think that had a tracheotomy been indicated in our case, we would have first used Doppler ultrasonography to confirm that the pulsating sound of a tortuous innominate artery could not be heard.

The pathogenesis of a tortuous or kinking innominate artery is unclear. Such diseases often accompany hypertension and obesity in middle-aged women. Moreover, arteriosclerotic changes due to hyperlipaemia have also been suggested (3). However, we speculate that decreased elasticity of the vascular walls due to ageing is one of the causes of this abnormality. We have also speculated as to whether another cause might be a congenital deformity of the artery, since neither hypertension nor obesity were involved in our case.

Successful surgical corrections of tortuous neck arteries have been reported (3). However, as long as the patient shows no cerebrovascular signs, and no stenosis or aneurysm of the artery is involved, many reports have recommended no surgical treatment (10). Our case showed no cerebrovascular ischaemic signs, and a strict follow-up schedule was implemented.

## REFERENCES

1. Sakurai Y, Koide S, Kawada S, Shotsu A. Tortuous right common carotid and/or subclavian arteries. *J Jpn Coll Angiol* 1990; 30: 449–452.
2. Polachek AA. Tortuous innominate artery simulating thyroid nodule. *NY State J Med* 1975; 75: 1276–1277.
3. Suzuki H, Sugawara M, Uenohawa H. Tortuous brachiocephalic trunk – a case report. *Otolaryngol Head Neck Surg (Tokyo)* 1997; 69: 496–498.
4. Bergan JJ, Hoehn JG. Evanescent cervical pseudoaneurysms. *Ann Surg* 1965; 162: 213–217.
5. Hori Y, Hashimoto S, Katori Y, Koiwa T, Hozawa K, Kobayashi T. Tracheostomy in tortuous brachiocephalic artery. *J Otolaryngol Jpn* 2004; 107: 152–155.
6. Schneider HJ, Felson B. Buckling of the innominate artery simulating aneurysm and tumor. *Am J Roentgenol Radium Ther Nucl Med* 1961; 85: 1106–1110.
7. Buxton JT Jr, Stallworth JM. Tortuous innominate arteries simulating aneurysm. *J Am Med Acad* 1963; 184: 1048–1049.
8. Buck RT, Siddiqui AR. Thyroid abnormality secondary to tortuous carotid artery. *Eur J Nucl Med* 1986; 12: 51–52.
9. Muhammad JK, Major E, Wood A, Patton DW. Percutaneous dilatational tracheostomy: haemorrhagic complications and vascular anatomy of the anterior neck. A review based on 497 cases. *Int J Oral Maxillofac Surg* 2000; 29: 217–222.
10. Leipzig TJ, Dohrmann GJ. The tortuous or kinked carotid artery: pathogenesis and clinical considerations. A historical review. *Surg Neurol* 1986; 25: 478–486.