

## Compression Bandage as Treatment for Ulcers Induced by Intramuscular Self-injection of Paraffin Oil

Line Iversen, Asja Lemcke, Mikael Bitsch and Tonny Karlsmark

Department of Dermatology, Bispebjerg Hospital, Copenhagen University, Bispebjerg Bahke 23, DK-2400 Copenhagen, Denmark.

E-mail: li07@bbh.regionh.dk

Accepted August 28, 2008.

Sir,

Injection of foreign substances, such as paraffin oil, for the purpose of body contour augmentation has been used from the beginning of the last century (1). Since the severe destructive consequences of migrating paraffin oil were recognized (2, 3), the procedure has become obsolete in Western medicine. However, oil injections are still practised, either as self-injection or by unauthorised personnel. Adverse effects include skin inflammation, induration, sterile abscesses, fistulas, and skin rupture with suppuration of oily material.

Among bodybuilders, 3 cases have been reported (4–6) in which all had performed oil injection for the purpose of muscle augmentation. We describe here another case from this subculture in which the person developed skin and muscle necroses forming multiple ulcers after paraffin oil injections. The ulcers healed after conservative treatment with compression bandage. However, this patient may suffer from long-term sequelae, such as the formation of paraffinomas, which may require further surgical treatment.

### CASE HISTORY

A 23-year-old male bodybuilder was referred to Copenhagen Wound Care Centre with numerous ulcers on both upper arms (Fig. 1). Previously, he had presented to different regional hospitals.

For the purpose of muscle augmentation, he had injected paraffin oil in the biceps, triceps and anterior/

posterior part of the deltoid muscle. Over a period of 1–1.5 years, he carried out 10 series of oil injections of 20 ml in each muscle. In total, he had injected approximately 1 litre of oil in each arm. At the same time he also abused anabolic steroids.

Approximately one month after the last series of oil injections, he developed increasing pain in both arms. He also complained of malaise and temperature. The skin covering the deltoid region and the brachial anterior region was red, swollen and indurated. Enlarged painless lymphatic nodes were found in the neck, but none in the axillae. Laboratory examinations showed increased infection parameters with leukocytes  $20.2 \times 10^9$  with neutrofilocytoses CRP 92 mg/l. Ultrasound showed multiple echo-empty structures of different sizes compatible with oil but no abscesses. At this time no treatment was given.

Over the next 2 months, skin necroses developed with spontaneous perforation and suppuration of oily, necrotic material leaving numerous ulcers in both arms. The largest one was approximately 7×15 cm. A larger abscess-like structure over the right pectoral muscle was punctured twice with extraction of blood blended with oil. Microbiological culture of the material showed no pathogens.

To evaluate the possibilities for surgery, magnetic resonance imaging (MRI) of both arms was performed (Fig. 2). MRI gave an almost identical picture to that of ultrasound. The biceps muscles showed small cystic

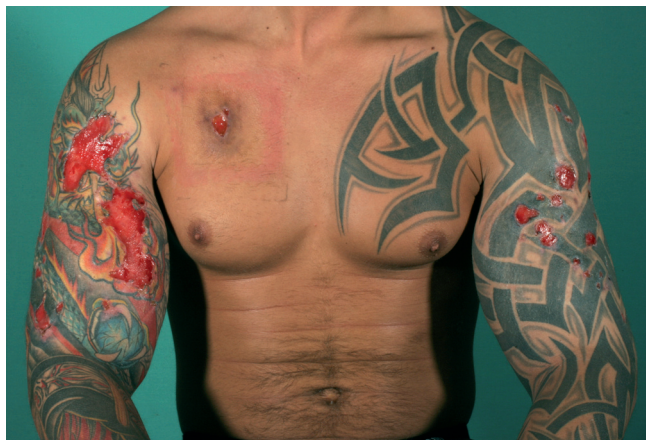

Fig. 1. Bodybuilder with multiple ulcers on his arms as a reaction to injected mineral oil.

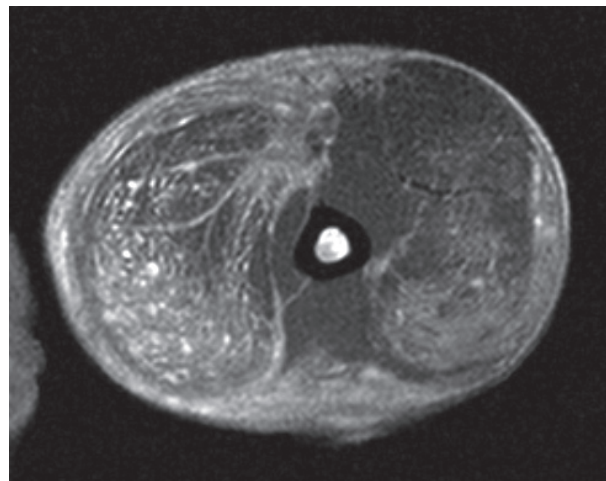


Fig. 2. Cross-sectional magnetic resonance image of the upper right arm approximately one month after the last oil injection, showing illuminated, confluent and small, cystic areas representing paraffin oil.

and confluent areas corresponding to the paraffin oil. Almost equivalent changes were seen in the triceps musculature. No abscesses or fistulas were seen. Because of the extensive spread of the oil, it was not possible to perform surgery.

At Copenhagen Wound Care Centre, he was treated conservatively with dicloxacillin and compression bandage from the wrists and up to the shoulder region. Against our advice, the patient did not show up for further management until 1.5 years later. During that time, he had used compression therapy on himself, for as long as possible and he observed improvement and even complete healing of the wounds with that treatment. However, he developed several sore firm tumours on both arms including smaller ones around the nipple area, probably representing paraffinomas. He was referred to plastic surgery.

## DISCUSSION

The clinical features of paraffin oil injection are well known. The initial symptom is an acute inflammatory phase 1–6 months after injection. Later, a latent phase often follows, during which the substance is tolerated. After a variable time-interval, late reactions appear. The paraffin oil is resistant to the action of lysosomal enzymes of tissues and macrophages, which leads to chronic granulomatous inflammation. This is parallel to other foreign body reactions. The foreign body reaction to paraffin oil results in the formation of fibrous tissue, which helps walling of the mineral oil, and separates it into small globules (7). This reaction may lead to skin induration, necroses and disfiguring subcutaneous nodules. The granulomatous tissue may further undergo suppuration and fistulae formation, giving rise to discharging sinuses. Mineral oil spreads and infiltrates soft tissues, therefore an area larger than the original oil injection area, is often affected (8).

Histopathology of paraffinoma reveals chronic granulomatous inflammation with foreign body giant cells and cystic spaces containing paraffin oil and calcification giving the so-called “Swiss cheese” microscopic appearance (7).

The term paraffinoma describes the tumours caused by granulomatous reaction to paraffin (mineral oil) or other lipophilic substances introduced in the subcutis. Tumours are also sometimes designated according to the injected substance as oleomas or siliconomas when oil or silicon, respectively, is injected (3).

In general it is advisable to perform excisional surgery to remove as much of the injected material or affected area as possible (8–10). In some cases, as in the one described here, conservative treatment may be the only option, because of very deep and widespread distribution of the oil. Treatment with compression bandage on ulcers induced by oil injection has not been reported

previously. Conservative treatment with prednisolone to reduce inflammation has been reported (7).

The positive result of treatment with compression bandages may be secondary to the improvement in microcirculation through reduction of oedema. The compression bandage provides closer contact between capillaries and skin, which makes the diffusion distance shorter. This improves nutrition and oxygenation, and leads to wound healing. This effect of compression therapy is seen in ulcers due to chronic venous insufficiency (11), but beneficial effect of compression therapy on other kinds of ulcers is, to the author’s knowledge, mainly based on empirical observations. On the other hand, the healing could also be a spontaneous reaction as a result of tolerance following the acute inflammatory phase.

In the case described here, the diagnosis was made based on the history, clinical and radiological appearance. There was no specimen for histopathological examination. We cannot exclude that contamination of the injected material could have taken place, but our examination did not point in that direction. We do not know how prevalent self-injection of oil is amongst bodybuilders. The few reports we have of this procedure among bodybuilders may just be the tip of the iceberg, as reactions to the injected oil often appear after year-long periods of latency.

## REFERENCES

1. Gersuny R, Über eine subcutane Prothese. *Zeitschrift f. Heilkunde* 1900; 21: 199. (The classic reprint).
2. Smetana HF, Bernard W. Sclerosing lipogranulomas. *Arch Pathol Lab Med* 1956; 50: 296–325.
3. Newcomer VD, Graham JH, Schaffer RR. Sclerosing lipogranuloma from exogenous lipids. *Arch Dermatol* 1956; 73: 361–372.
4. Georgieva J, Assaf C, Steinhoff M, Treudler R, Orfanos CE, Geilen CC. Bodybuilder oleoma. *Br J Dermatol* 2003; 149: 1289–1290.
5. Darsow U, Bruckbauer H, Worret W, Hofmann H, Ring J. Subcutaneous oleomas induced by self-injection of sesame seed oil for muscle augmentation. *J AM Acad Dermatol* 2000; 42: 292–294.
6. Munch I, Hvoriris JJ. Bodybuilding ved hjælp af intramuskulær injektion af valnøddeolie [Bodybuilding with help of intramuscular injections of chest nut oil]. *Ugeskr Læger* 2001; 163: 6758 (in Norwegian).
7. Urbach F, Wine SS, Johnson WC, Daivis RE. Generalized paraffinoma. *Arch Dermatol* 1971; 103: 277–285.
8. Di Benedetto G, Pierangeli M, Scalise A, Bertani A. Paraffin oil injection in the body: an obsolete and destructive procedure. *Ann Plast Surg* 2002; 49: 391–396.
9. Catalano OA, Dal Pozzo F, Nizzi Grifi D, Menchi I, Rosenthal DI. Paraffinoma of the knee. *Skeletal Radiol* 2003; 32: 485–488.
10. Hohause K, Bley B, Köstler E, Schönlebe J, Wollina U. Mineral oil granuloma of the penis. *Eur Acad Dermatol Venereol* 2003; 17: 585–587.
11. Klyscz T, Galler S, Steins A, Züder D, Rassner G, Jünger M. Influence of compression therapy on skin microcirculation in patients with chronic venous insufficiency. *Hautarzt* 1997; 48: 806–811.