

## Pyoderma Gangrenosum with Myelodysplastic Syndrome Treated with Analogous Bone Marrow Transplantation

Kazuohoshi Yamanaka<sup>1</sup>, Shuichi Kuniyuki<sup>1\*</sup>, Naoki Maekawa<sup>1</sup>, Yuki Yoshida<sup>1</sup> and Hirohumi Teshima<sup>2</sup>

<sup>1</sup>Division of Dermatology and <sup>2</sup>Division of Hematology, Osaka City General Hospital, Miyakojima-Hondori 2-13-22, Miyakojima-ku, 534-0021, Osaka, Japan. \*E-mail: ga28547@wa2.so-net.ne.jp

Accepted August 25, 2008.

Sir,

Pyoderma gangrenosum (PG) is a neutrophilic dermatosis characterized by necrotizing suppurative inflammation. PG is often associated with myelodysplastic syndrome (MDS). Its pathogenesis is unknown, but immune dysfunction associated with neutrophil hyperactivity has most often been proposed. In general, patients are treated with systemic steroids or immunosuppressive agents (1). Cases of PG in a patient with MDS treated with systemic steroids or immunosuppressive agents have rarely been documented. The pathogenesis of the association of PG and MDS is controversial. We describe here an 18-year-old man with multiple PG ulcers. Treatment with analogous bone marrow transplantation (BMT) achieved complete relief.

### CASE REPORT

An 18-year-old Japanese man was referred to our outpatient clinic in March 2003 for the evaluation of a one-month history of multiple erythematous ulcerating plaques. In addition, he had a continuous high fever, anaemia and leukopaenia. Physical examination revealed painful erythematous ulcers with undermined violaceous raised borders, and necrotic pustules on the thighs and buttocks (Fig. 1A). Laboratory data revealed a decreased white blood cell count ( $2690/\mu\text{l}$ ), anaemia (red blood cell count  $3.29 \times 10^6/\mu\text{l}$ , haemoglobin 9.7 g/dl, haematocrit 31.9%), normal platelet count ( $276 \times 10^3/\mu\text{l}$ ) and increased C-reactive protein (7.47 mg/dl). Liver and renal function tests gave normal results. A biopsy of bone marrow aspiration showed decreased haematopoietic cells (decreased granulocytes 32.8%, increased erythroblasts 30.6%). No gene rearrangement of T-cell receptors was found in the sample of peripheral blood.

Histopathology of the lesion on the right thigh revealed necrotizing suppurative inflammation with dense infiltration of neutrophils, intermingled with multinucleated histiocytes and leukocytoclasia, throughout the whole dermis (Fig. 2). The patient was diagnosed with PG from the clinical and histopathological findings and was treated with pulse therapy of 1 g methylpred-

nisolone for 3 days, along with systemic cyclosporine 5 mg/kg daily. Despite this treatment, the aggravation of severe arthritis, high fever and repeated skin ulceration persisted. Subsequently, the above treatment could provide no relief from PG inflammation. Finally, the patient underwent a BMT, donated by his brother, with human leukocyte antigen (HLA) type HLA-A2, B-35, B-54, CW-1, and CW-3, which completely matched the patient. After the combination of whole body electron irradiation and immunosuppression with systemic cyclophosphamide 60 mg/day for 10 days, analogous BMT was performed in January 2004. Four weeks after BMT, temporary acute graft-versus-host disease appeared and was treated successfully with systemic administration of tacrolimus 60 mg/day for 2 days. Subsequently, the grafted bone marrow took completely, with normalization of the blood cell count and complete remission of the PG lesions (Fig. 1B). At present, 4 years after BMT, he has had no relapse of PG and MDS.

### DISCUSSION

More than 50% of patients with PG have associated systemic diseases, including ulcerative colitis, MDS (2), Crohn's disease, and inflammatory arthritis (1), and the aetiology remains unclear. Margo et al. (3) reported that clonality in neutrophilic dermatoses, while characteristic of underlying myeloid dyscrasia, is not observed exclusively in the setting of myeloproliferative diseases, suggesting that PG might be a localized form of cutaneous neutrophilic dyscrasia. Immunosuppressants, including cyclosporin A and corticosteroids, diaminodiphenylsulfone, minocycline, thalidomide, and granulocyte apheresis are effective in PG (1). In PG associated with MDS, pulse therapy with intravenous methylprednisolone is effective in cases refractory to oral steroid therapy (4).

The course of PG is unpredictable and the manifestations range from very limited and superficial ulcerations to widespread disease with extracutaneous manifestations. PG is still life-threatening with a mortality rate

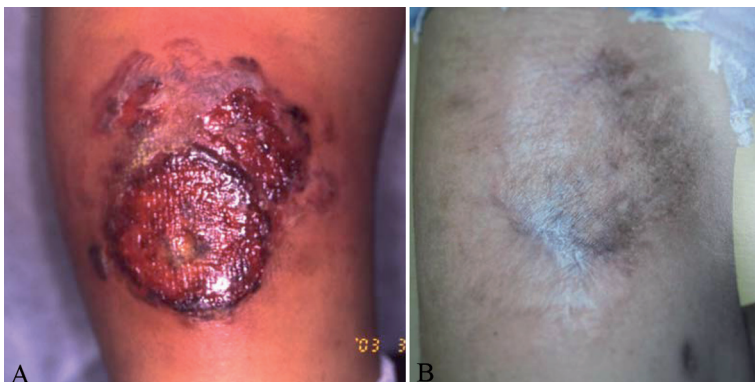

Fig. 1. (A) Clinical appearance of erythematous ulcerated lesions on the right thigh. (B) Six weeks after analogous bone marrow transplantation, pyoderma gangrenosum lesions had resolved, leaving post-inflammatory hyperpigmentation.

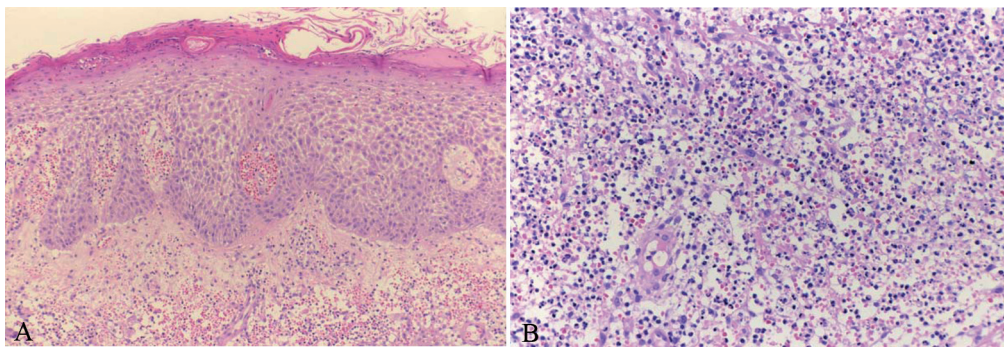


Fig. 2. (A) Histopathological examination of the lesion on the right thigh revealed central necrotizing suppurative inflammation, dense infiltration of neutrophils, multinucleated histiocytes and leukocytoclasia throughout the whole dermis (H&E stain  $\times 40$ ). (B) Dense infiltration of neutrophils, multinucleated histiocytes and leukocytoclasia were observed (H&E stain  $\times 400$ ).

of up to 30% in some series (5). In addition, long-term follow-up by von den Driesch ( $n=42$ , median follow-up 26.5 months) revealed that 6 patients had died due to the PG and/or underlying diseases (6). This emphasizes that BMT should be considered even in early stage of MDS associated with PG.

The pathogenesis of MDS has been suggested as an anomaly of bone marrow stem cells, which cause pancytopenia of leukocytes, red blood cells and platelets. Despite treatment with immunosuppressive agents and systemic steroid administration, haematopoietic stem cell transplantation (HSCT) is the only proven curative treatment for MDS (7), offering good results, especially in young patients or in the early stage of MDS. HSCT treatment is generally performed for haematological disorders of leukaemia, malignant lymphoma and MDS. In addition, autologous HSCT has recently been performed for patients with cancer on strong and curative chemotherapy. Since 1996, approximately 1000 patients have received autologous HSCT as treatment for severe autoimmune disease, including multiple sclerosis, systemic lupus erythematosus, rheumatoid arthritis, etc. (8). Many patients have experienced long-term disease-free remission, and immune reconstitution studies have shown in some cases that a "resetting" of autoimmunity is possible (8), although the procedures are generally not curative. In contrast, allogeneic HSCT appears to be potentially curative by a process of immune replacement, but the potential for high toxicity has limited its use in this context (9). Patients with concomitant autoimmune disease receiving allogeneic and autologous HSCT for conventional indications, such as malignancy or aplastic anaemia, have occasionally shown improvement in both conditions (10); those observations are also supported by data on experimental animals (11).

Over the past decade, a steady stream of single cases and small case series has been published showing the outcome of coincidental autoimmune disease in patients receiving HSCT for conventional indications such as malignancy or aplastic anaemia (12). In many of these patients, but not all, long-term remission of autoimmune disease was observed. Therefore, we supposed that the present case, who ultimately did not respond at all to intensive drug therapy, was indicated for analogous BMT

in order to control both PG and MDS. To the best of our knowledge, this is the first case of PG in an MDS patient successfully treated with BMT, providing complete relief of both MDS and PG. We speculate that immunosuppression in BMT by cyclophosphamide along with systemic tacrolimus had almost no effect on the control of PG, because the present case had been refractory to steroid pulse therapy, or cyclosporine.

## REFERENCES

1. Wollina U. Pyoderma gangrenosum – a review. *Orphanet J Rare Dis* 2007; 2: 19–35.
2. Aractingi S, Bachmeyer C, Miclea JM, Verola O, Rousselot P, Dubertret L, et al. Unusual specific cutaneous lesions in myelodysplastic syndromes. *J Am Acad Dermatol* 1995; 33: 187–191.
3. Margo CM, Kiani B, Li J, Crowson AN. Clonality in the setting of Sweet's syndrome and pyoderma gangrenosum is not limited to underlying myeloproliferative disease. *J Cutan Pathol* 2007; 34: 526–534.
4. Yamaguchi T, Ishida K, Iwashima Y, Ikegaya S, Kawai Y, Wakahara M, et al. Successful treatment of pyoderma gangrenosum that developed in a patient with myelodysplastic syndrome. *J Infect Chemother* 2003; 9: 268–271.
5. Hafner J, Kuhne A, Trueb RM. Successful grafting with EpiDex in pyoderma gangrenosum. *Dermatology* 2006; 212: 258–259.
6. von den Driesch. Pyoderma gangrenosum: a report of 44 cases with follow-up. *Br J Dermatol* 1997; 137: 1000–1005.
7. Barrett AJ, Savani BN. Allogeneic stem cell transplantation for myelodysplastic syndrome. *Semin Hematol* 2008; 45: 49–59.
8. Passweg J, Tyndall A. Autologous stem cell transplantation in autoimmune diseases. *Semin Hematol* 2007; 44: 278–285.
9. Kapoor S, Wilson AG, Sharrack B, Lobo A, Akil M, Sun L, et al. Hematopoietic stem cell transplantation – an evolving treatment for severe autoimmune and inflammatory diseases in rheumatology, neurology and gastroenterology. *Hematology* 2007; 12: 179–191.
10. Knaan-Shanzer S, Houben P, Kinwel-Bohre EP, van Bekkeum DW. Remission induction of adjuvant arthritis in rats by total body irradiation and autologous bone marrow transplantation. *Bone Marrow Transplant* 1991; 8: 333–338.
11. Tyndall A, Daikeler T. Autologous hematopoietic stem cell transplantation for autoimmune diseases. *Acta Hematol* 2005; 114: 239–247.
12. Marmount AM. Stem cell transplantation for autoimmune disorders. Coincidental autoimmune diseases in patients transplanted for conventional indications. *Best Pract Res Clin Haematol* 2004; 17: 223–232.