

Merkel Cell Carcinoma Associated with *In situ* and Invasive Squamous Cell Carcinoma

Begoña Vieites¹, José M. Suárez-Peñaranda¹, Victor Delgado², Hugo Vázquez-Veiga³, Juan Varela¹ and Jerónimo Forteza¹

Departments of ¹Pathology and ³Dermatology, University Hospital of Santiago de Compostela, c/ Choupana s/n, ES-15706 Santiago de Compostela, Spain, and ²Department of Pathology, Hospital Guillermo Almenara, Lima, Peru. E-mail: bvieites@yahoo.es
Accepted June 30, 2008.

Sir,

Merkel cell carcinoma (MCC) is an uncommon neuroendocrine malignant neoplasm whose origin has not been well documented. Clinically, it presents as a rapidly enlarging nodule, usually located in the head and neck area of patients older than 60 years of age (1, 2). Little is known about the association with other malignant skin diseases, although there have been some reports of metachronous MCC and basal cell carcinoma, *in situ* or infiltrating squamous cell carcinoma and malignant melanoma (2–5). Suggested causes or risk factors for the association with Bowen's disease include chronic exposure to arsenic or other harmful chemicals, and excessive radiation (4). We present here two cases of MCC associated with *in situ* and invasive squamous cell carcinoma, respectively.

CASE REPORTS

Case 1. An 86-year-old woman was referred to hospital complaining of a 10-cm tumour located on her left forearm. It was a painless, hard, well-circumscribed, non-ulcerated mass, which had progressively enlarged for the last 2 months. Physical examination showed no other abnormalities and routine blood analyses were normal. The patient did not report contact with chemical agents nor had she been chronically exposed to excessive ultraviolet (UV) radiation. Following a diagnostic biopsy the tumour was completely excised.

Formalin-fixed paraffin-embedded tissue from both cases were sectioned and routinely stained with haematoxylin and eosin (HE). Immunohistochemistry was performed on selected paraffin-embedded tissue with the Dako REAL™ EnVision™ Detection System, Peroxidase/DAB+, Rabbit/Mouse (Dako, Glostrup, Denmark), using an automated immunostainer (TechMate™ 500 plus, Dako). The following primary antibodies were evaluated: pancytokeratin (AE1/AE3, Dako, 1/20), cytokeratin 20 (CK20, Dako, 1/20), neuron-specific enolase (NSE, Dako, 1/20), Chromogranin A (CGA, Novocastra, Newcastle, UK, 1/50), Synaptophysin (SPH, Biogenes, San Ramon, USA, 1/100), Thyroid Transcription Factor 1 (TTF-1, Dako 1/20) and CD117 (c-kit, pharmDx, Dako).

Histopathological examination showed dermal nests of small and medium-sized, round, basophilic cells arranged in a trabecular or diffuse pattern, extending deeply through the dermis to the subcutaneous fat (Fig. 1A). At greater magnification the tumour cells were seen to be uniform, with little cytoplasm and round nuclei with finely granulated chromatin and single, inconspicuous nucleoli. In some sections, the keratinocytes located in the overlying epidermis were atypical in appearance, with hyperchromatic nuclei and pleomorphism affecting the full thickness of the epidermis. Occasionally, dyskeratotic cells and areas of pagetoid appearance were also noted (Fig. 1B).

The dermal tumour cells were strongly positive for neuron-specific enolase and synaptophysin, and moderately positive for CGA, CD117, AE1/AE3, and CK20, showing a dot-like pattern, but negative for TTF1 and CK7. The neoplastic epidermal cells

were negative for NSE, SPH, CGA, CD117, CK7, TTF1 and CK20, but strongly positive for AE1/AE3. On the basis of the histopathological and immunohistochemical findings, the diagnosis of MCC associated with Bowen's disease was established. No other treatments were given and the patient died 2 years later of an unrelated disease.

Case 2. A 75-year-old man was referred to our hospital because of a left retroauricular nodular lesion. He reported rapid growth for the last 5 months. The lesion was an exophytic, irregular mass, extensively ulcerated, approximately 5.5 cm in width. No previous history of trauma or surgical procedure was available. The lesion was excised with wide margins.

Histopathological examination showed that the neoplasm had two completely different areas (Fig. 2A–B). Most of it corresponded to a solid proliferation of small and medium-sized cells arranged in nests and ribbons or diffusely throughout the whole dermis and the subcutaneous fat. Nuclei were uniform, with fine chromatin and inconspicuous nucleoli, while cytoplasm were scanty. The second component of the tumour was formed by atypical squamous cells located both in the epidermis and superficial dermis, with an infiltrative pattern. A regional lymph node was resected, but metastatic cells were not demonstrated.

Immunohistochemical study showed diffuse staining of the small cells for AE1/AE3, CK20, with "dot-like" pattern, CK7, NSE, CGA, SPH and CD117, but not for TTF1. Keratinizing atypical cells also stained for AE1/AE3, but not for CK20, CK7, NSE, CGA, SPH, TTF1 and CD117. These morphological and immunohistochemical findings were consistent with the diagnosis of MCC associated with invasive squamous cell carcinoma.

Two months after initial surgery, the patient presented with unilateral enlarged cervical lymph nodes and was admitted to left cervical radical lymphadenectomy. Metastatic cells were present in one out of the seven lymph nodes removed and also in the left parotid gland. One month later, a nodular lesion appeared on the scar of the previous excision and it was removed again. The only neoplastic component demonstrated in the recurrences was that of the MCC. The patient is alive and free of disease 9 months after his last surgery.

DISCUSSION

The origin of cutaneous MCC has not yet been elucidated. Although the most commonly accepted hypothesis is an origin from the Merkel cell, a mechanoreceptor located at the basal layer of the epidermis, some authors propose a pluripotential cell as the origin of this type of tumour (5–7). Merkel cells share some similitudes with MCC cells, but also some differences: the whorl- or plaque-like arrangements of intermediate filaments (CK20 or neurofilaments) of MCC cells is not seen in normal Merkel cells (7). Additionally, if this cutaneous cell were a precursor of MCC, a higher number of tumours with an intraepidermal component would be expected, but these have been reported in only 9–18%

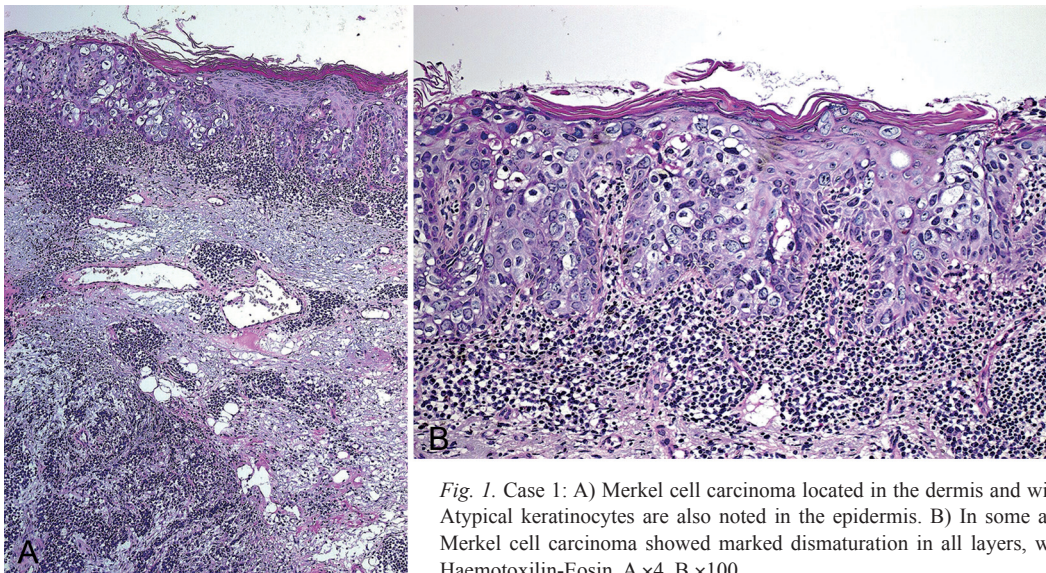


Fig. 1. Case 1: A) Merkel cell carcinoma located in the dermis and without extension to the epidermis. Atypical keratinocytes are also noted in the epidermis. B) In some areas the epidermis overlying the Merkel cell carcinoma showed marked dysmaturization in all layers, with many atypical keratinocytes. Haematoxylin-Eosin, A $\times 4$, B $\times 100$.

of MCCs (6, 8–10). The possibility of considering MCC arising from a pluripotential stem cell is supported by the association between MCC and other neoplasms and by the divergent differentiation (neuroendocrine, squamous, adnexal and melanocytic) described in some MCC (5–7). Immunohistochemical studies have shown staining for a variety of antibodies, but reactivity with neuroendocrine markers and a dot-like staining for CK 20 are most characteristic (1). This pattern has been well documented in our two cases, clearly demonstrating that we are dealing with MCC. Recent immunohistochemical studies have described the diagnostic utility of new markers, such as the CD117, with potential relevance in the management of the neoplasm; CD117 was positive in our two cases and in most MCC, but these neoplasms do not contain activating mutations in exons 9, 11, 13 or 17 of Kit gene (11).

What makes our cases remarkable is the presence of what seems to be a completely different second neoplasm. Histopathological examination and immunohistochemistry clearly demonstrate that both patients have two different but synchronous neoplasms arising in the same place. In case 1, squamous cell carcinoma

is exclusively located in the epidermis while MCC is restricted to the dermis, without continuity between both neoplasms. Although in case 2 the two neoplasms are closely related in the dermis, there is no transition between them, and they seem to be two clearly different tumours. MCC has already been reported in association with other cutaneous neoplasms, usually squamous cell carcinoma, invasive or intraepidermal, but also sweat gland tumours, actinic keratosis or basal cell carcinoma (2–4, 7). This association may be synchronous or metachronous and when both neoplasms appear synchronously they are usually separated by a “Grenz zone” with only occasional cases showing both neoplasms intermingled (12). Although the absence of transition between the two neoplasms favours no common origin from a pluripotential epithelial cell, the presence of squamous or glandular differentiation in some MCC (13), the location of both neoplasms in sun-exposed skin, and the demonstration of the same mutations in ras and p53 genes in some cases (14), could point in the opposite direction.

Although the induction of a second neoplasm by the first tumour cannot be excluded, the most probable ex-

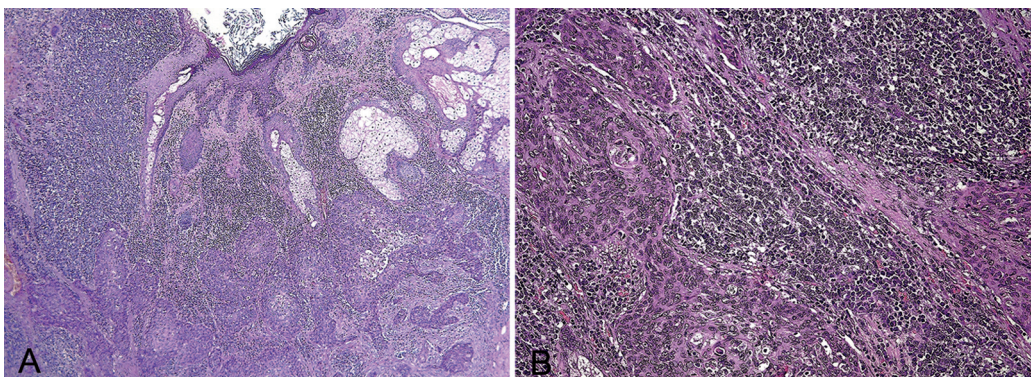


Fig. 2. Case 2: A) Merkel cell carcinoma and invasive squamous carcinoma in the dermis, beside normal cutaneous anexa. B) Nests of atypical squamous cells are present between small round cells disposed diffusely. Haematoxylin-Eosin, A $\times 20$, B $\times 400$.

planation is that we are dealing with a collision tumour, either coincidental or because they share some common aetiopathogenic agents or risk factors that have not yet been identified (2–4, 6, 7, 15).

REFERENCES

1. Mott RT, Smoller BR, Morgan MB. Merkel cell carcinoma: a clinicopathological study with prognostic implications. *J Cutan Pathol* 2004; 31: 217–223.
2. Plaza JA, Suster S. The Toker tumour. Spectrum of morphologic features in primary neuroendocrine carcinomas of the skin (Merkel cell carcinoma). *Ann Diag Pathol* 2006; 10: 376–385.
3. Avesti C, Grossin M, Toublanc M, Benrejeb N, Bourgeois-Droin C, Delacretaz J, et al. Association d'un carcinome neuro-endocrine cutané et d'une maladie de Bowen. *Ann Pathol* 1990; 2: 86–98.
4. Ohnishi Y, Murakami S, Ohtsuka H, Miyauchi S, Shinomori H, Hashimoto K. Merkel cell carcinoma and multiple Bowen's disease: incidental association or possible relationship to inorganic arsenic exposure? *J Dermatol* 1997; 24: 310–316.
5. Foschini MP, Eusebi V. Divergent differentiation in endocrine and non neuroendocrine tumours of the skin. *Sem Diagn Pathol* 2000; 17: 162–168.
6. Al-Ahmadie HA, Mutasim DF, Mutema GK. A case of intraepidermal Merkel cell carcinoma within squamous cell carcinoma in-situ: Merkel cell carcinoma in-situ? *Am J Dermatopathol* 2004; 26: 230–233.
7. Moll I, Roessler M, Brandner JM, Eispert AC, Houdek P, Moll R. Human Merkel cells- aspects of cell biology, distribution and functions. *Eur J Cell Biol* 2005; 84: 259–271.
8. Smith KJ, Skeleton HG 3rd, Holland TT, Morgan AM, Lupton GP. Neuroendocrine (Merkel cell) carcinoma with an intraepidermal component. *Am J Dermatopathol* 1993; 15: 528–533.
9. Ferringer T, Rogers HC, Metcalf JS. Merkel cell carcinoma in situ. *J Cutan Pathol* 2005; 32: 162–165.
10. Hashimoto K, Lee MW, D'Annunzio DR, Balle MR, Narisawa Y. Pagetoid Merkel cell carcinoma: epidermal origin of the tumor. *J Cutan Pathol* 1998; 25: 572–579.
11. Swick BL, Ravdel L, Fitzpatrick JE, Robinson WA. Merkel cell carcinoma: evaluation of KIT (CD117) expression and failure to demonstrate activating mutations in the C-KIT proto-oncogene – implications for treatment with imatinib mesylate. *J Cutan Pathol* 2007; 34: 324–329.
12. Iacocca MV, Abernethy JL, Stefanato CM, Allan AE, Bhawan J. Mixed Merkel cell carcinoma and squamous cell carcinoma of the skin. *J Am Acad Dermatol* 1998; 39: 882–887.
13. Silva EG, Mackay B, Goepfert H, Burgess MA, Fields RS. Endocrine carcinoma of the skin (Merkel cell carcinoma). *Pathol Annu* 1984; 19: 1–30.
14. Popp S, Waltering S, Herbst C, Moll I, Boukamp P. UV-B-type mutations and chromosomal imbalances indicate common pathways for the development of Merkel and skin squamous cell carcinomas. *Int J Cancer* 2002; 99: 352–360.
15. Skelton HG, Smith KJ, Hitchcock CL, McCarthy WF, Lupton GP, Graham JH. Merkel cell carcinoma: analysis of clinical, histologic, and immunohistologic features of 132 cases with relation to survival. *J Am Acad Dermatol* 1997; 37: 734–739.