

Novel Treatment for Cheilitis Glandularis

Hendrik Jorn Bovenschen

Department of Dermatology, Radboud University Nijmegen Medical Center, René Descartes dreef 1, PO Box 9101, 6525 GL, Nijmegen, The Netherlands.

E-mail: j.bovenschen@derma.umcn.nl

Accepted June 30, 2008.

Sir,

In 1870, von Volkmann (1) introduced the term cheilitis glandularis (CG). He described a distinct, chronic inflammatory condition of the lower lip characterized by mucopurulent exudates from the ductal orifices of enlarged labial salivary glands. Historically, CG has been classified into three subtypes: simplex, superficial suppurative, and deep suppurative. However, it is now believed that these represent three stages in progression of a single disease entity. Conventional treatment consists of vermilionectomy or the administration of intralesional corticosteroids. Additional treatment with antibiotics is frequently necessary (2, 3). We report here on a patient with CG treated successfully with a combination of oral minocycline and tacrolimus ointment 0.1%, thereby avoiding invasive therapy.

CASE REPORT

An otherwise healthy 58-year-old woman presented with a one-year history of persistent swelling of mainly the lower lip after considerable sunburn in summer (Fig. 1A). The main complaint was an intense burning pain that greatly impaired her quality of life. Anamnestically, there was no evidence for angioedema or urticaria. Dermatological investigation revealed swollen, erythematous to purpuric lips with small firm indurated papules at the margin of the lips and mucosa. The lower lip was clinically more severe than the upper lip. There were no signs of bacterial superinfection or suppurative exudate. Cheilitis granulomatosa, lupus erythematosus, actinic cheilitis

and sarcoidosis, amongst other dermatoses, had been ruled out by lip biopsy and auto-immune serology. The non-spectacular histology showed a normal epidermis with slight salivary gland enlargement, enlarged vessels and a dermal lymphohistiocytic infiltrate. No signs of suppurative exudate or bacterial infection were observed (Fig. 2). The diagnosis of CG simplex was made on clinicopathological correlation. Treatment consisted of minocycline 100 mg once daily in combination with topical tacrolimus ointment 0.1% twice daily, both for 6 weeks. After 6 weeks both the clinical appearance and the burning pain had completely disappeared (Fig. 1B). The patient continued monotherapy with tacrolimus ointment 0.1% for another 6 weeks. A further 6-month treatment-free follow-up period did not reveal any sign of recurrence. No side-effects were recorded.

DISCUSSION

It has been challenged that CG is a separate clinical entity or merely a reaction pattern to chronic irritation of the lips. It has been reported that CG is associated with various external causes, including actinic damage, factitial injury, atopy, infection, and tobacco irritation (4). CG is highly uncommon and has to be differentiated from other clinical entities, such as cheilitis granulomatosa, lupus erythematosus, angioedema, atopic cheilitis, actinic cheilitis and sarcoidosis. Diagnosis is made on clinicopathological correlation by excluding these differential diagnoses by lip biopsy derived histological analysis.

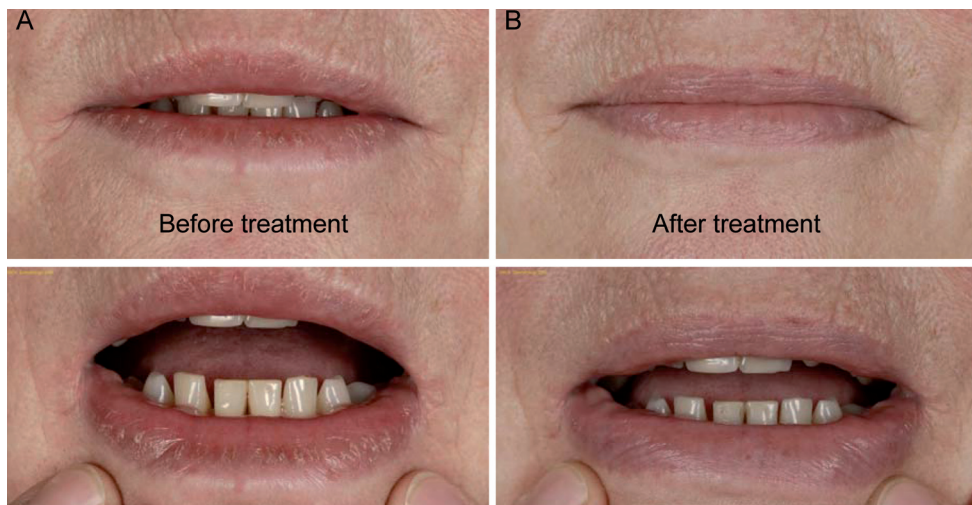


Fig. 1. Cheilitis glandularis simplex: (A) before and (B) after successful treatment with a combination of oral minocycline 100 mg once daily and tacrolimus ointment 0.1% twice daily for 6 weeks.

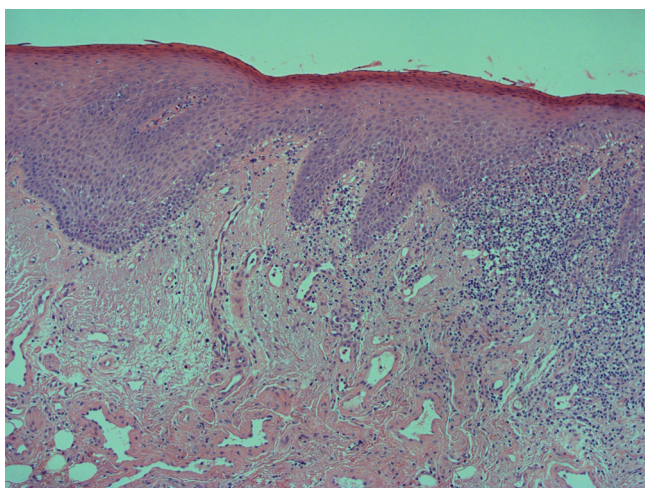


Fig. 2. Non-specific histopathology of cheilitis glandularis simplex, in this case characterized by a dense lymphocytic infiltrate and enlarged salivary glands. Other differential diagnoses could be excluded. Magnification $\times 100$.

The histopathology of CG can reveal a wide range of possible histological changes. Therefore, no regular or pathognomonic features of this disorder are observed at the microscopic level. Instead, a diverse collection of possible alterations can be detected in both epidermis and submucosal tissues. These findings best allow us to determine the aetiology and nature of individual cases. Although randomized controlled clinical trials are lacking due to the low incidence of CG, effective treatment often involves surgery or intralesional injections with corticosteroids (2, 3, 5). Topical corticosteroids, 5-fluorouracil and cryotherapy are other described options, although the safety and efficacy of these treatments remain obscure (2, 4). There is only one case report describing a successful treatment of CG (secondary to oral lichen ruber planus) with topical calcineurin inhibitors tacrolimus and pimecrolimus (4).

Minocycline has both anti-bacterial and anti-inflammatory actions, including suppression of neutrophil chemotaxis and proinflammatory cytokines, inhibition of T-cell activation and up-regulation of regulatory T-cell-associated interleukin 10 (6). Treatment with minocycline was preferable in our patient in order to establish an anti-inflammatory effect and meanwhile to prevent bacterial superinfection. The addition of

tacrolimus ointment was based on the appearance of multiple T cells in the histology. Tacrolimus ointment is a strong T-cell inhibitor and acts by virtue of blocking calcineurin, an enzyme in T cells that is essential in their activation and the production of pro-inflammatory cytokines. Many off-label indications have been described in the literature since the introduction of this type of medication for the treatment of atopic dermatitis (7).

It has been proposed that patients with CG have a slightly increased risk of development of dysplasia and malignant transformation of the lip (8). Therefore, it is important that patients are instructed to stop smoking and to reinstate proper hygiene. Furthermore, the use of sunscreens should be obligatory due to the reduced local immune surveillance caused by our treatment and therefore the theoretical chance of enhancing malignant transformation. In our patient the treatment period was short and during winter.

In conclusion, treatment of CG with a combination of oral minocycline and tacrolimus ointment 0.1% may be a novel option for those patients in whom invasive therapy is less preferable.

REFERENCES

1. Von Volkmann R. Einige Falle von Cheilitis Glandularis Apostematosa (Myxadenitis Labialis). *Virchows Arch Pathol Anat* 1870; 50: 142–144.
2. Swerlick RA, Cooper PH. Cheilitis glandularis: a reevaluation. *J Am Acad Dermatol* 1984; 10: 466–472.
3. Hillen U, Franckson T, Goos M. Cheilitis glandularis: a case report. *Acta Derm Venereol* 2004; 84: 77–79.
4. Erkek E, Sahin S, Kilic R, Erdogan S. A case of cheilitis glandularis superimposed on oral lichen planus: successful palliative treatment with topical tacrolimus and pimecrolimus. *J Eur Acad Dermatol* 2007; 21: 999–1000.
5. Verma S. Cheilitis glandularis: a rare entity. *Br J Dermatol* 2003; 148: 362.
6. Sapadin AN, Fleischmajer R. Tetracyclines: nonantibiotic properties and their clinical implications. *J Am Acad Dermatol* 2006; 54: 258–265.
7. Sehgal VN, Srivastava G, Dogra S. Tacrolimus: approved and unapproved dermatologic indications/uses-physician's sequential literature survey: part II. *SKINmed* 2008; 7: 73–77.
8. Carrington PR, Horn TD. Cheilitis glandularis: a clinical marker for both malignancy and/or severe inflammatory disease of the oral cavity. *J Am Acad Dermatol* 2006; 54: 336–337.