

Etanercept for the Treatment of Hidradenitis Suppurativa

Eleni Sotiriou, Zoe Apalla and Dimitrios Ioannidos

1st Dermatologic Department, Medical School, Aristotele University, Papakyriazi 8, str., GR-54645 Thessaloniki, Greece. E-mail: elenasotiriou@yahoo.gr
Accepted May 27, 2008.

Sir,

Hidradenitis suppurativa (HS) is a rather common, painful, debilitating and chronic inflammatory skin disease with associated severe morbidity (1, 2), affecting 1% of the general population. Potential complications include abscesses, sinus tract and fistulae formation and scarring. Treating HS is challenging, as the common therapeutic approaches such as antibiotics, retinoids, oral contraceptives and immunosuppressive therapies do not achieve complete remission, or lead to relapse after discontinuation (3). Biologic medications have been used as an "off-label" treatment for HS (4–8). Etanercept, a soluble anti-tumour necrosis factor (TNF) agent used in our study, proved beneficial to the management of HS.

PATIENTS AND METHODS

Four patients, 3 females and one male, with severe, recalcitrant, treatment-resistant HS were recruited and treated with etanercept over a 6-month period between September 2006 and February 2007. The inclusion criterion was severe chronic HS (Hurley stage II and above) (9), unresponsive to at least two conventional treatments. History of cardiac failure, tuberculosis, neurological diseases, malignancy and smoking were exclusion criteria. Signed informed consent was obtained in all cases. The mean age of the patients was 36 years (range 25–41 years) and the mean disease duration was 3.75 years (range 3.5–5 years). Previous therapeutic modalities included oral antibiotics (amoxicillin, doxycycline, oxytetracycline), dapson, anti-androgenic oral contraceptives and isotretinoin. All previous treatments were discontinued 2 weeks before initiation of etanercept treatment. Etanercept was administered at a dose of 25 mg subcutaneously twice a week in all cases. At the time of initial administration all patients were free of acute or chronic infections, had negative chest X-ray and purified protein derivative test. Clinical evaluations were performed by the same examiners at baseline, at months 1, 3 and 6, and at 3 months after discontinuation of treatment. At each visit the examiners evaluated the severity of the disease using a scoring system described by Sartorius et al. (10) and graded the response to therapy, while the patients evaluated their clinical improvement

in percentage terms. In addition, before initiation and after discontinuation of treatment, patients were asked to complete a Dermatology Life Quality Index (DLQI) questionnaire.

RESULTS

Etanercept treatment was well tolerated. No patient required treatment discontinuation due to adverse effects. Patient 4 experienced a mild reaction at the infusion site during the first week of treatment. Improvement in subjective symptoms was experienced at a mean of 13 days (range 8–81 days) after the initial dose. During the first follow-up clinical evaluation, decreased inflammation, induration, sinus drainage and tenderness was observed in patients 1, 2 and 4. A poor response in patient 3 lead to the decision to double the dosage to 50 mg twice weekly. After 3 months patient 1 showed an almost complete resolution and absence of inflammatory lesions, purulence, drainage, pain or tenderness in all involved areas. Patients 2 and 4 had a further reduction in disease activity, while patient 3 showed a marked reduction in induration, tenderness and sinus drainage. At month 6, disease activity was stable for all 4 patients.

Mean self-reported improvement on the 6th month was 68.75% (range 55–80%), while the DLQI questionnaires showed a mean reduction of 66.5% (range 54–73%).

During the last follow-up, 3 months after treatment discontinuation, relapse of the disease was observed in patients 2, 3 and 4, whereas patient 1 continued to have a good response patients 2 and 3 relapsed within 2 weeks and patient 4 within 3 weeks of discontinuing etanercept. As a result, a second therapeutic cycle of etanercept was prescribed.

Demographic and specific disease data are shown in Table I. Changes in disease activity over the treatment and follow-up period are shown in Fig. 1.

Table I. Patient characteristics and results after 6 months of etanercept therapy

Patient no.	Sex/age/disease duration (years)	Hurley staging	Previous therapies	Etanercept dosage	Subjective improvement (%)	DLQI reduction (%)	Response to therapy ^a
1	F/41/4.5	II	Abs, OCP, isotretinoin	25 mg × 2/week	80	73	+++
2	F/35/3	III	Abs, prednisone, isotretinoin	25 mg × 2/week	70	68	+++
3	M/43/5	III	Abs, isotretinoin	25 mg × 2/week	55	71	++
4	F/25/2.5	II	dapsone	doubled after 1 month			
			Abs, OCP	25 mg × 2/week	70	54	+++

DLQI: Dermatology Life Quality Index; Abs: oral antibiotics; OCP: oral contraceptives.

^aResponse to therapy graded by treating physicians as: +++ marked improvement, ++ moderate improvement, + mild improvement, 0 no change.

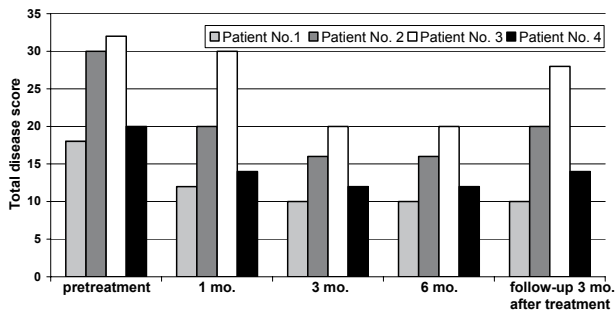


Fig. 1. Disease activity score in individual patients before, during and after etanercept therapy.

DISCUSSION

The aetiology and pathogenesis of HS remain obscure. HS is usually localized to apocrine gland-bearing areas of the body, which at one time led to the belief that apocrine glands play a central role in the disease. However, recent studies prove that the primary lesion is an occluding spongiform infundibulo-folliculitis, leading to dilatation of the follicle followed by its rupture and leakage of contents into surrounding dermis. This triggers an acute inflammatory cell infiltration of neutrophils, lymphocytes and histiocytes, followed by the chronic granulomatous phase of the disease, characterized by the presence of histiocytes and giant cells. TNF- α induces pro-inflammatory cytokines, activates neutrophils and lymphocytes and also recruits inflammatory cells to sites of inflammation; thus, it contributes to granuloma formation. TNF- α is found increased within and around granulomas in HS tissues (11). It may, therefore, play an important role in the disease (12). The importance of immune dysregulation in HS is further demonstrated by its association in many individuals with inflammatory bowel disease (13). Additionally, the response of HS to systemic corticosteroids and other medications that are broadly immunosuppressive, such as cyclosporine (14), underscores its inflammatory pathogenesis.

Etanercept is a competitive inhibitor of TNF- α , binding to its cell surface receptors (15). Previous reports with limited number of patients have shown clinical benefit of anti-TNF- α drugs in HS (4–8). The first case of effective treatment of HS with etanercept was reported by Jurgensmeyer & Fleischer in 2004 (6), followed by a case reported in 2006 by Henderson (4). Two clinical trials performed by Cusack & Buckley in 2006 (5) and Giamarellos-Bourboulis et al. in 2008 (8), including 6 and 10 patients, respectively, concluded that etanercept could be an effective and safe treatment for HS. Finally, Zangrilli et al. (7) reported in 2008 one case of HS treated with etanercept and underlined the long-term efficacy of the treatment.

According to our results, etanercept appears to be an effective, well-tolerated and safe alternative treat-

ment for this challenging disease. Further controlled trials and additional clinical experience is needed to determine the optimal dosing schedules and safety of etanercept in HS.

The authors state no conflicts of interest.

REFERENCES

1. von der Werth JM, Jemec GB. Morbidity in patients with hidradenitis suppurativa. *Br J Dermatol* 2001; 144: 809–813.
2. Wolkenstein P, Loundou A, Barraou K, Auquier P, Revuz J. Quality of Life Group of the French Society of Dermatology. Quality of life impairment in hidradenitis suppurativa: a study of 61 cases. *J Am Acad Dermatol* 2007; 56: 621–623.
3. Jemec GB. Medical treatment of hidradenitis suppurativa. *Expert Opin Pharmacother* 2004; 5: 1767–1770.
4. Henderson RL Jr. Treatment of atypical hidradenitis suppurativa with the tumor necrosis factor receptor-Fc fusion protein etanercept. *J Drugs Dermatol* 2006; 5: 1010–1011.
5. Cusack C, Buckley C. Etanercept: effective in the management of hidradenitis suppurativa. *Br J Dermatol* 2006; 154: 726–729.
6. Jurgensmeyer JC, Fleischer A. Clinical improvement of refractory hidradenitis suppurativa with etanercept. *Poster* 58. *J Am Acad Dermatol* 2004; 50 Suppl 3: 15.
7. Zangrilli A, Esposito M, Mio G, Mazzotta A, Chimenti S. Long-term efficacy of etanercept in hidradenitis suppurativa. *J Eur Acad Dermatol Venereol* 2008 [Epub ahead of print].
8. Giamarellos-Bourboulis E.J, Pelekanou E, Antonopoulou A, Petropoulou H, Baziaka F, Karagianni V, et al. An open-label phase II study of the safety and efficacy of etanercept for the therapy of hidradenitis suppurativa. *Br J Dermatol* 2008; 158: 567–572.
9. Hurley HJ. Axillary hiperhidrosis, apocrine bromhidrosis, hidradenitis suppurativa and familial benign pemphigus: surgical approach. In: Roenigk RA, Roenigk HH Jr, editors. *Dermatological surgery: principles and practice*. New York: Marcel Dekker, 1989: p. 735.
10. Sartorius K, Lapins J, Emtestam L, Jemec GB. Suggestions for uniform outcome variables when reporting treatment effects in hidradenitis suppurativa. *Br J Dermatol* 2003; 149: 211–213.
11. Ahmed AA, Nordlind K, Schultzberg M, Liden S. Immunohistochemical localization of IL-1 alpha, IL-1 beta, IL-6 and TNF-alpha-like immunoreactivities in human apocrine glands. *Arch Dermatol Res* 1995; 287: 764–766.
12. Fardet L, Dupuy A, Kerob D, Levy A, Allez M, Begon E, et al. Infliximab for severe hidradenitis suppurativa: transient clinical efficacy in 7 consecutive patients. *J Am Acad Dermatol* 2007; 56: 624–628.
13. Rosi YL, Lowe L, Kang S. Treatment of hidradenitis suppurativa with infliximab in a patient with Crohn's disease. *J Derm Treat* 2005; 16: 58–61.
14. Rose R, Goodfield M, Clark S. Treatment of recalcitrant hidradenitis suppurativa with oral ciclosporin. *Clin Exp Dermatol* 2005; 31: 154–155.
15. Giamarellos-Bourboulis EJ, Antonopoulou A, Petropoulou C, Mouktaroudi M, Spyridaki E, Baziaka F, et al. Altered innate and adaptive immune responses in patients with hidradenitis suppurativa. *Br J Dermatol* 2007; 156: 51–56.