

CLINICAL REPORT

PR3-ANCA-positive Necrotizing Multi-organ Vasculitis Following Cocaine Abuse

Sven NEYNABER¹, Nouhad MISTRY-BURCHARD², Christian RUST³, Walter SAMTLEBEN², Walter H.C. BURGDORF¹, Michael Andreas SEITZ⁴, Gerald MESSER¹ and Andreas WOLLENBERG¹

Departments of ¹Dermatology, ²Internal Medicine I, ³Internal Medicine II and ⁴Urology, Ludwig-Maximilians-University Munich, Germany

A 22-year-old man with a history of cocaine abuse from 2003 to 2005 developed recurrent bleeding of the nasal septum and a progressive cough and dyspnoea. He was admitted to the intensive care unit because of fulminant pneumonia, impaired renal function and progressive general deterioration. While hospitalized, he developed cutaneous vasculitis, thrombosis of the right subclavian and right jugular veins, testicular pain and, eventually, expanding red papules and plaques on the limbs. The symptoms were a diagnostic challenge, until skin biopsy showed immunoglobulin deposits in small vessels and kidney biopsy focal and segmental pauci-immune, crescentic glomerulonephritis. This led, together with anti-neutrophil cytoplasmic antibodies (cANCA and PR3-ANCA), to the diagnosis of Wegener granulomatosis. The number of affected organ systems in our patient exceeds that commonly found in the literature. Several clinical observations of cocaine abuse followed by Wegener granulomatosis suggest an active induction of a PR3-ANCA-positive vasculitis by cocaine. *Key words:* Wegener's granulomatosis; testicular vasculitis; immunoglobulin M deposits.

(Accepted April 23, 2008.)

Acta Derm Venereol 2008; 88: 594–596.

Andreas Wollenberg, Department of Dermatology, Ludwig-Maximilians-University Munich, Frauenlobstr. 9–11, DE-80337 München, Germany. E-mail: Andreas.Wollenberg@lrz.uni-muenchen.de

A cocaine-addicted patient with midline destructive lesions developed vasculitis with multiple organ involvement of upper and lower airways, kidney, testis and skin with accompanying laboratory findings, which led to a diagnosis of Wegener granulomatosis (WG). Multiple organ involvement is typical for WG; testicular involvement, however, is rare. We speculate that this patient's cocaine abuse triggered the systemic granulomatous vasculitis.

CASE REPORT

A 22-year-old man was referred to our hospital for the diagnosis and treatment of dyspnoea, which had

developed over the past 2 weeks. His medical history included weekly heroin and cocaine abuse for 2 years preceding the onset of his first systemic signs and symptoms. The cocaine sniffing had caused destruction of his nasal septum. Progressive cough, dyspnoea, fulminant pneumonia and, later, decreased renal function and deterioration of his general condition led to admission to the intensive care unit (ICU). Skin findings included cutaneous nodules and plaques on arms and legs, which persisted on diascopy (Fig. 1). The initial chest X-ray showed dense infiltrates in the right upper and middle lobe compatible with pneumonia and intra-alveolar haemorrhage (Fig. 2). However, a complete microbiological work-up including bronchoscopic sampling did not reveal an infectious agent. Pathological laboratory findings included leukocytosis 36.2 g/l (normal < 11.0), d-dimers 18.9 mg/dl (< 0.5), creatinine 1.5 mg/dl (\leq 1.2), creatinine clearance 49 ml/min (80–120) and C-reactive protein (CRP) 19.0 mg/dl (< 0.5). A skin biopsy revealed leukocytoclastic vasculitis of small and medium-sized dermal vessels, with fibrinoid vessel wall necrosis, extravasated red blood cells, and a neutrophil infiltrate with nuclear dust. Direct immunofluorescence revealed large deposits of IgM with lesser amounts of IgG, IgA and C3 at small cutaneous vessels (Fig. 3). Because of

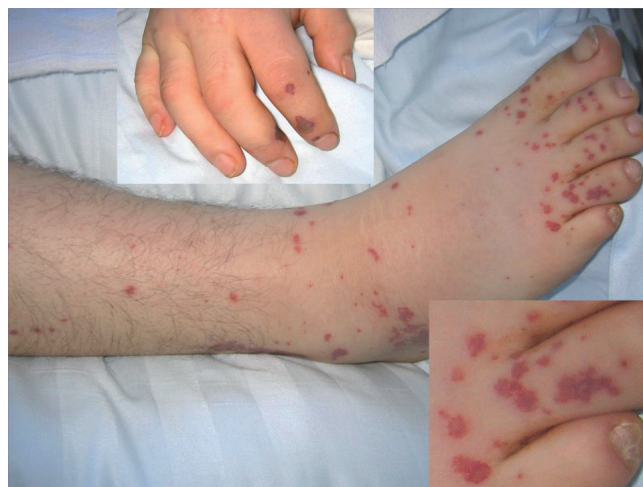

Fig. 1. Multiple disseminated non-blanching red-violet papules on the hands and feet: clinical features of a systemic vasculitis.

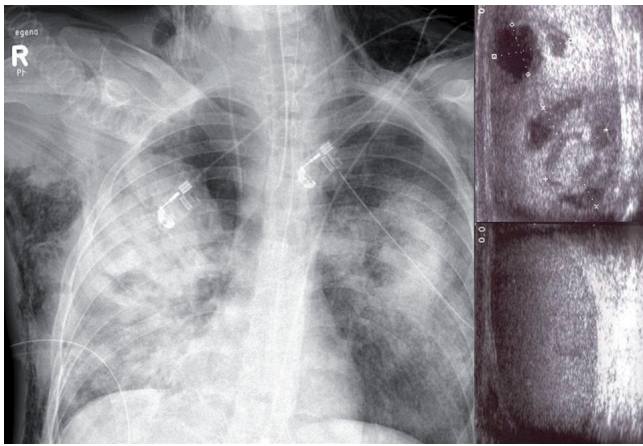


Fig. 2. Radio- and ultrasound diagnostics. *Left*: Skin emphysema, pneumonia in the upper and middle lobe; massive bleeding into the parenchyma. *Top right*: Testicular tumour with inhomogeneous echogenicity, partly hyperechogenic to some extent hypoechogenic. *Bottom right*: Three months later after treatment. Homogeneous echogenicity with a slight hypoechogenic pattern in the former suspected tumour region.

renal insufficiency (rising creatinine up to 2.0 mg/dl), proteinuria (4.8 g/day) and microhaematuria (>250 erythrocytes per higher power field (HPF)), a kidney biopsy was performed. It showed a focal and segmental glomerulonephritis with crescents, but without immune deposits ("pauci-immune rapidly progressive glomerulonephritis"). The described lesions are typical for renal involvement of antineutrophil cytoplasmic antibodies (ANCA)-associated vasculitides. Characteristic elevated c-ANCA immunofluorescence (1:640) together with antibodies against proteinase 3 (PR3-ANCA; 89 U/ml, normal: <10 U/ml) in enzyme-linked immunosorbent assay (ELISA) analysis led to our diagnosis of WG. Anti-nuclear antibody (ANA) assay on Hep2-cells was negative, but the Hep2-cells showed cytoplasmic fluorescence. Immunofluorescence for p-ANCA and the MPO-ANCA ELISA remained negative.

Therapy was started with prednisolone, 250 mg/day, and cyclophosphamide, 100 mg/day. The patient's ICU

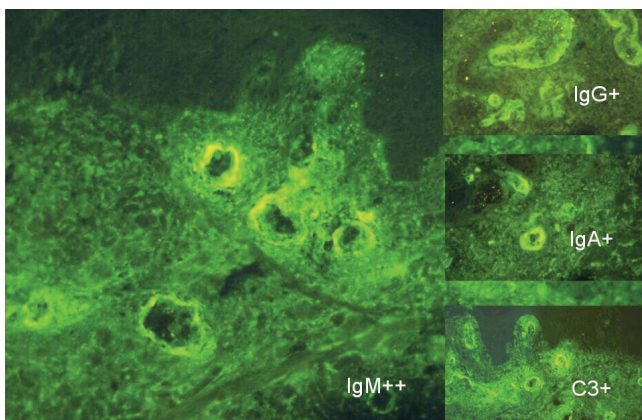


Fig. 3. Immunoglobulin and complement deposits in small cutaneous vessels; large deposits of immunoglobulin M (IgM).

stay was complicated by severe pneumonia, bilateral pneumothoraces with accompanying emphysema, thrombosis of the subclavian and right jugular vein and seizures after extubation, probably due to heroin withdrawal. All manifestations improved under antibiotic and immunosuppressive therapy, and the prednisolone dose was tapered to a maintenance dose of 20 mg/day. Based on clinical criteria, the pulmonary lesions in our patient could be pneumonitis, intra-alveolar haemorrhage and/or granulomatous lung disease.

A few weeks later the therapy was tapered and the patient complained of testicular pain. Ultrasound B-scan examination showed a tumour 13 × 18 mm in size with inhomogeneous echogenicity with both hyper- and hypo-echogenic areas. The working diagnosis was a cT1 testicular cancer, but vasculitis with haemorrhage was a differential diagnostic consideration. Testicular vasculitis is a rare manifestation of WG. Reintroduction of prednisolone and cyclophosphamide was again effective in improving all signs and symptoms. A control ultrasound examination revealed normal conditions on both testicles, indicating that immunosuppressive therapy was effective.

DISCUSSION

This case of fulminant WG is instructive in several ways. First, midline destructive lesions of the nasal septum are a well-known side-effect of long-term cocaine abuse. As this was a reasonable explanation for the septal damage, a workup for possible WG was delayed until further symptoms developed. Secondly, our patient differed from the usual pauci-immune manifestations of WG by showing immunoglobulin and complement deposits in skin. Thirdly, testis involvement is an unusual manifestation of WG. However, any isolated inflammation of the testicle (orchitis) is an uncommon disease, and may be triggered by *Mycobacterium tuberculosis*, *Treponema pallidum* and *Brucella* spp. as well as mumps virus or Coxsackie-B virus, and does not respond to immunosuppressive therapy (1).

The clinical picture of WG was first described in 1931 by Heinz Klinger, a German medical student (2). In 1936 the German pathologist Friedrich Wegener (1907 to 1990) gave a detailed description of the complex autoimmune syndrome (3). It is characterized by necrotizing vasculitis together with granulomatous vasculitis of the upper and lower respiratory tract, kidneys and skin. Following the 1994 Chapel Hill Consensus Classification, WG is classified as a clinically characteristic small-vessel vasculitis highly associated with a specific laboratory marker, the c-ANCA (4–6).

The target of cANCA is mainly PR3, a 29 kDa protein localized intracellularly in the azurophilic granules, secretory vesicles and specific granules of neutrophils and monocytes (7). In a meta-analysis of cANCA and

WG the sensitivity ranged from 34% to 92%, pooled sensitivity 66%, the specificity ranged from 88% to 100%, pooled specificity was 98% (8). However, cANCA may also be absent in WG (9). This cANCA-negative WG is diagnosed through clinical, serological and histological findings and remains a diagnostic challenge. The pathogenic role of ANCA for WG is still unclear, because patients can have low or absent ANCA titres during active disease, the levels of antibody titres do not correlate well with the activity of WG and patients with WG in remission can have high ANCA titres without recurrence of disease (10, 11).

As no infectious agent could be isolated from our patient, and as antibiotic therapy did not improve our patient's clinical condition or his pulmonary infiltrates, we discarded the possible diagnosis of bacterial pneumonia and diagnosed an infiltration due to pulmonary WG. The rapid lung improvement following immunosuppressive therapy supported the latter diagnosis.

Colonization of the nasal vestibulum with *Staphylococcus aureus* is an accepted trigger for WG exacerbation, whereas clinically apparent infections are rarely identified. *S. aureus* seems to induce the expression of interleukin-8 (IL-8) and to trigger a poorly understood immunological cascade in the upper airways. Many clinical observations have shown that antibiotic therapy can reduce the rate of WG recurrence (12, 13). After we cultured *S. aureus* from our patient's nasal mucosa, we treated topically with mupirocin ointment.

Some authors use the term cocaine-induced pseudo-vasculitis with clinical and serological findings and positive cANCA and distinguish this from WG and other types of vasculitides (14). It remains unclear, however, if pseudo-vasculitis is an independent phenomenon of early, localized vasculitis in WG, as this term is not well-defined, does not imply clinical consequences and, at least in our patient, true vasculitis was present. Therefore, we think the concept of pseudo-vasculitis for a condition fulfilling the histological criteria for leukocytoclastic vasculitis is inadequate.

Coexistence of cocaine abuse and WG has been reported several times. From the chronology of cocaine abuse and WG in our patient, we think that the activation of the autoimmune vasculitis in WG was triggered by cocaine abuse. Pathophysiologically, the chronic necrotizing process leads to inflammation, clearance of dead cells and activation of an inflammatory process engaged in the specific immunological response and wound healing. All of these processes might play a role in the activation of an autoimmune disease as a trigger, if a certain genetic background can support a specific immune response to proteins as PR3 in WG. We support the notion that recurrent cocaine abuse at the mucosa of the nose can lead to the systemic autoimmune disease WG. As a consequence, we suggest that patients with cocaine abuse and midline destructive lesions should be examined for vasculitis of

the upper respiratory tract, kidneys and skin, as well as screened for c-ANCA and PR3-ANCA positivity.

Both WG and cocaine abuse may induce midline destructive lesions with very similar symptoms. Indeed, it may be difficult to distinguish cocaine-induced midline destructive lesions and early localized WG of the upper airways. Both causes must be considered early in the differential diagnosis of midline destructive lesions, but larger studies are needed to show how often cocaine-induced lesions reflect the presence of WG.

REFERENCES

- Weidner W, Krause W. Orchitis. In: Knobil E, Neill JD, editors. Encyclopedia of reproduction. San Diego: Academic Press, 1999, p. 524–527.
- Klinger H. Grenzformen der Periarteriitis nodosa. Frankfurter Zeitschrift für Pathologie, Wiesbaden 1931; 42: 455–480.
- Wegener F. Über generalisierte, septische Gefässkrankungen. Verhandlungen der deutschen pathologischen Gesellschaft, Stuttgart 1936; 29: 202.
- Andrassy K, Koderisch J, Rufer M, Erb A, Waldherr R, Ritz E. Detection and clinical implication of anti-neutrophil cytoplasm antibodies in Wegener's granulomatosis and rapidly progressive glomerulonephritis. Clin Nephrol 1989; 32: 159–167.
- Hunder GG, Arend WP, Bloch DA, Calabrese LH, Fauci AS, Fries JF, et al. The American College of Rheumatology 1990 criteria for the classification of vasculitis. Introduction. Arthritis Rheum 1990; 33: 1065–1067.
- Jennette JC, Falk RJ, Andrassy K, Bacon PA, Churg J, Gross WL, et al. Nomenclature of systemic vasculitides. Proposal of an international consensus conference. Arthritis Rheum 1994; 37: 187–192.
- van der Geld YM, Limburg PC, Kallenberg CG. Proteinase 3, Wegener's autoantigen: from gene to antigen. J Leukoc Biol 2001; 69: 177–190.
- Rao JK, Weinberger M, Oddone EZ, Allen NB, Landsman P, Feussner JR. The role of antineutrophil cytoplasmic antibody (c-ANCA) testing in the diagnosis of Wegener granulomatosis: a literature review and meta-analysis. Ann Intern Med 1995; 925–932.
- Mustonen J, Soppi E, Pasternack A, Hallstrom O. Clinical significance of autoantibodies against neutrophil cytoplasmic components in patients with renal disease. Am J Nephrol 1990; 10: 482–488.
- Kerr GS, Fleisher TA, Hallahan CW, Leavitt RY, Fauci AS, Hoffman GS. Limited prognostic value of changes in antineutrophil cytoplasmic antibody titer in patients with Wegener's granulomatosis. Arthritis Rheum 1994; 37: 596–597.
- Finkelman JD, Merkel PA, Schroeder D, Hoffman GS, Spiera R, St Clair EW, et al. WGET Research Group. Antiproteinase 3 antineutrophil cytoplasmic antibodies and disease activity in Wegener granulomatosis. Ann Intern Med 2007; 147: 611–619.
- DeRemee RA, McDonald TJ, Weiland LH. Wegener's granulomatosis: observations on treatment with antimicrobial agents. Mayo Clin Proc 1985; 60: 27–32.
- Rasmussen N. Management of the ear, nose, and throat manifestations of Wegener granulomatosis: an otorhinolaryngologist's perspective. Curr Opin Rheumatol 2001; 13: 3–11.
- Friedman DR, Wolfsthal SD. Cocaine-induced pseudo-vasculitis. Mayo Clin Proc 2005; 80: 671–673.