

## CLINICAL REPORT

# Two Cases of Anti-Epiligrin Cicatricial Pemphigoid With and Without Associated Malignancy

Satoshi FUKUSHIMA<sup>1</sup>, Kiyofumi EGAWA<sup>1</sup>, Hazuki NISHI<sup>1</sup>, Shoji WAKASUGI<sup>1</sup>, Norito ISHII<sup>2</sup>, Takashi HASHIMOTO<sup>2</sup>, Kim B. YANCEY<sup>3</sup> and Hironobu IHN<sup>1</sup>

<sup>1</sup>Department of Dermatology & Plastic and Reconstructive Surgery, Graduate School of Medical and Pharmaceutical Sciences, Kumamoto University, Kumamoto, <sup>2</sup>Department of Dermatology, Kurume University School of Medicine, Kurume, Japan, and <sup>3</sup>Department of Dermatology, University of Texas Southwestern Medical Center, Dallas, USA

**Anti-epiligrin cicatricial pemphigoid (AECp) is a chronic, mucous membrane-dominated, subepithelial blistering disease characterized by circulating anti-basement membrane zone auto-antibodies to laminin 5. Recent studies have shown that people with AECp have an increased relative risk for malignant tumours. In this report we describe two patients with AECp. In both cases, indirect immunofluorescence demonstrated circulating IgG anti-basement membrane auto-antibodies that bound to the dermal side of 1M NaCl split normal skin. Immunoblotting using laminin 5 purified from keratinocyte extract as a substrate showed that the IgG antibodies of patient 1 reacted with the 140-kDa  $\beta 3$  subunit of laminin 5 and IgG antibodies of patient 2 reacted with the 165-kDa and 145-kDa  $\alpha 3$  subunits. Patient 1 had prostate carcinoma and his blistering was resistant to therapy. Patient 2 had no detectable malignancy and treatment with doxycycline was successful. Key words: doxycycline; epiligrin, laminin 5; mucous membrane pemphigoid; prostate carcinoma.**

(Accepted April 2, 2008.)

Acta Derm Venereol 2008; 88: 484–487.

Satoshi Fukushima, Department of Dermatology & Plastic and Reconstructive Surgery, Graduate School of Medical and Pharmaceutical Sciences, Kumamoto University, 1-1-1 Honjo, Kumamoto JP-860-8556, Japan. E-mail: 056r5162@med.stud.kumamoto-u.ac.jp

Anti-epiligrin cicatricial pemphigoid (AECp) is a chronic, mucous membrane-dominated, subepithelial blistering disease characterized by circulating anti-basement membrane auto-antibodies to laminin 5. In AECp, laryngeal and intranasal involvements are more common than in the other forms of mucous membrane pemphigoid (MMP). However, it is sometimes difficult to distinguish clinically the mucosal lesions of AECp from those of other types of MMP. In AECp, the mucosal surfaces of the mouth and eye are most commonly involved (1). Symblepharon and laryngeal stenosis are the most severe complications. The importance of identifying or distinguishing AECp within the spectrum of mucosal-dominant blistering disease by

immunoblot and immunoprecipitation is underscored by its association with cancer (2, 3). On the other hand, MMP with antibodies to  $\beta 4$  integrin has a significantly lower incidence of cancer.

We describe here two patients with AECp. Patient 1 is the first published case of AECp associated with prostate carcinoma and his skin lesions were resistant to therapy. Patient 2 had no detectable malignancy and treatment with doxycycline gave a successful response.

## CASE REPORTS

### Case 1

A 90-year-old Japanese man presented with recurrent erosions on the buccal mucosa, nasal meatus, trunk and extremities (Fig. 1a). Laryngoscopy revealed a white coating around the epiglottis, but not laryngeal stenosis. He showed symblepharon of both eyes and corneal perforation of the left eye (Fig. 1b). He had rheumatoid arthritis, diabetes mellitus and prostate carcinoma. The latter had been diagnosed one year before the blistering. The histological diagnosis of the prostate carcinoma was poorly differentiated adenocarcinoma (Gleason score 9). A blood test for prostate specific antigen (PSA) gave a result of 100 ng/ml (normal <4 ng/ml). Following treatment with leuprorelin acetate monthly, his PSA level decreased to normal and an abnormal level was not recorded during the following 3 years. Skin biopsy of the lower leg revealed a subepidermal blister with an infiltration of eosinophils and neutrophils (Fig. 1c). Direct immunofluorescence demonstrated linear deposits of IgG and C3 at the basement membrane zone of the epidermis (Fig. 1d). Indirect immunofluorescence demonstrated circulating IgG anti-basement membrane zone auto-antibodies that bound to the dermal side of 1M NaCl split normal skin (Fig. 1e). Immunoblotting using laminin 5 purified from keratinocyte extract as a substrate showed that IgG antibodies of the patient reacted with 140-kDa polypeptides identical to the  $\beta 3$  subunit of the laminin 5 molecule (Fig. 2). With the diagnosis of AECp, treatment was commenced with oral prednisolone 30 mg, minocycline hydrochloride 100 mg, and nicotinamide 1500 mg daily. Although

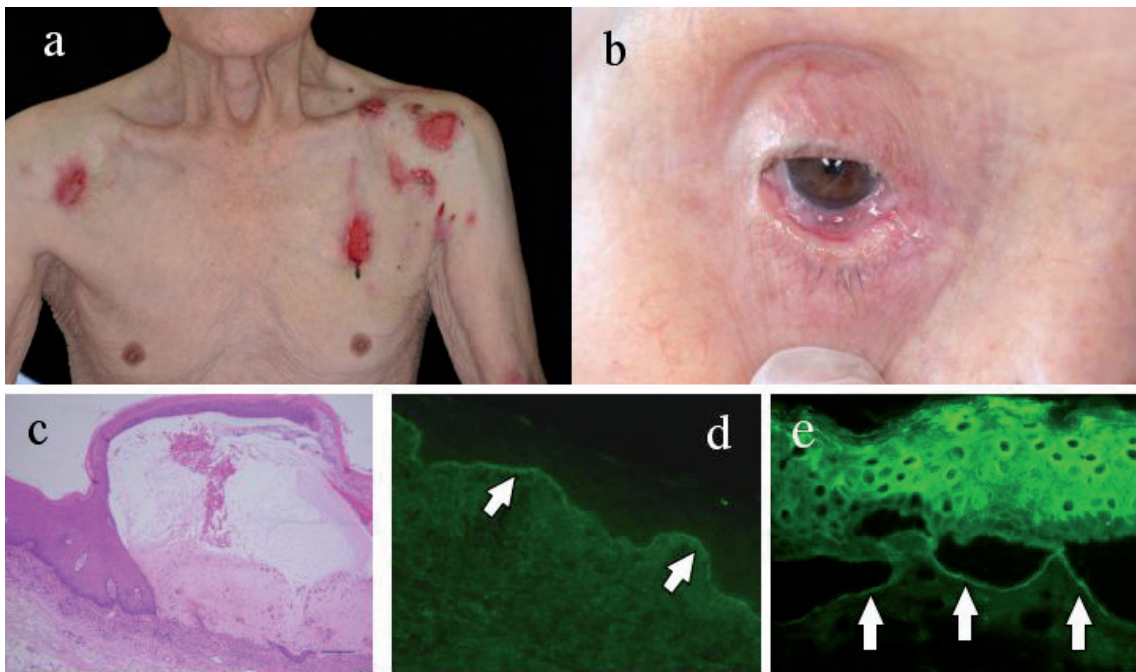


Fig. 1. Clinical features and histological and immunopathological findings of patient 1. (a) Recurrent erosions on the trunk and extremities. (b) Symblepharon. (c) Skin biopsy from the lower leg revealed a subepidermal blister with an infiltration of eosinophils and neutrophils. Bar=100  $\mu$ m. (d) Direct immunofluorescence demonstrated a linear deposit of IgG at the basement membrane zone of the epidermis (arrows). (e) Indirect immunofluorescence demonstrated circulating IgG anti-basement membrane zone auto-antibodies that bound to the dermal side of 1M NaCl split normal skin (arrows). Positivity of epidermis is non-specific staining.

the number of blisters decreased, new blister formation persisted. Additional oral dapsone, 100 mg daily, produced a slower response. Computed tomography of the whole body, ultrasonography of the abdomen and gastric endoscopy revealed no detectable malignant lesion.

Case 2

A 69-year-old Japanese woman presented with recurrent erosions and a white coating on the larynx and nose with trachyphonia and dyspnoea. The lesions healed with scarring (Fig. 3a). She also developed blistering of the trunk and lower legs (Fig. 3b). Skin biopsy of the trunk revealed a subepidermal blister with an infiltration of eosinophils and neutrophils (Fig. 3c). Direct immunofluorescence demonstrated linear deposits of IgG and C3 at the basement membrane zone of the epidermis, with an n-serrated pattern compatible with AECP (Fig. 3d) (4). Indirect immunofluorescence demonstrated circulating IgG anti-basement membrane zone auto-antibodies that bound to the dermal side of 1M NaCl split normal skin (Fig. 3e). Immunoprecipitation of radiolabelled human keratinocyte extract revealed the presence of anti-laminin 5 IgG antibodies in the patient's serum (Fig. 4a). Immunoblotting using laminin 5 purified from keratinocyte extract as a substrate showed that IgG antibodies of the patient reacted with 165-kDa and 145-kDa polypeptides that were identical to the processed form of the  $\alpha$ 3 subunit of the laminin 5 molecule and its degradation product (Fig. 4b). The patient was diagnosed as having AECP of the laryngeal mucosa and skin, and was treated with oral prednisolone 40 mg daily. However, prednisolone was stopped because she presented steroid-induced myopathy soon after starting the medication. She was then given oral minocycline hydrochloride 100 mg daily, but she could not continue

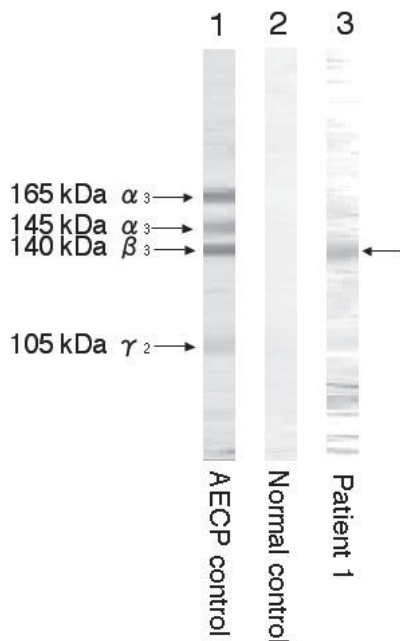
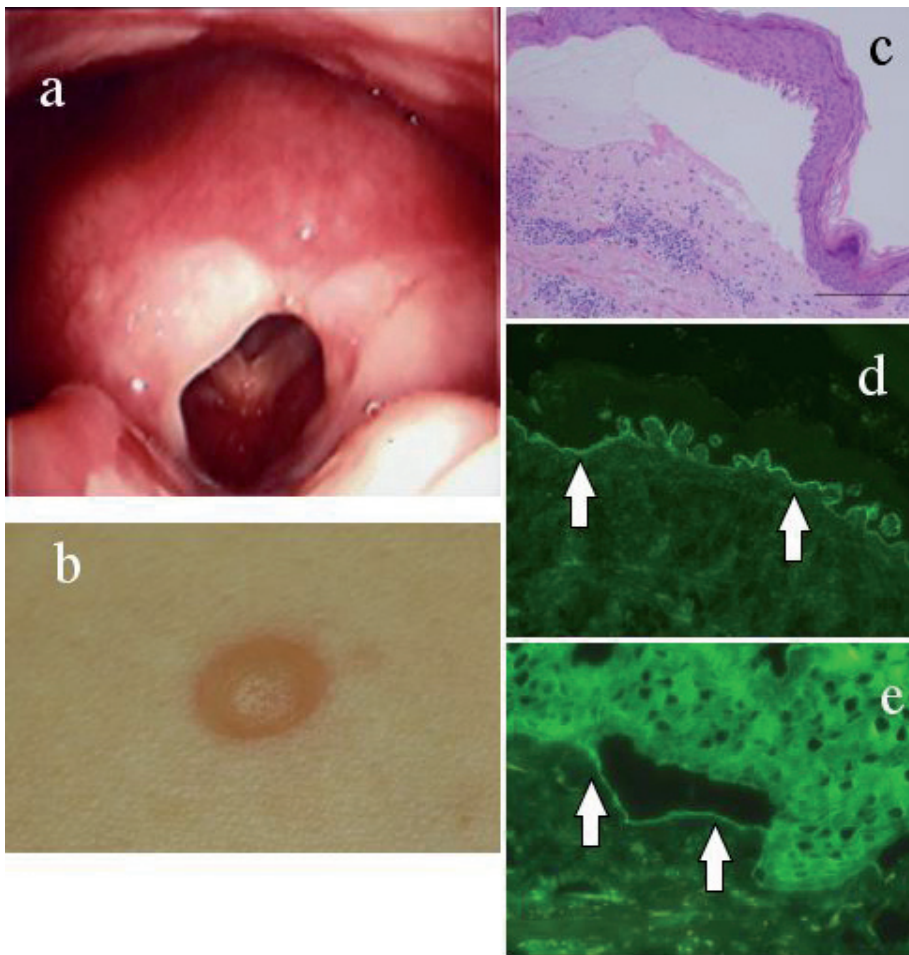


Fig. 2. Immunoblotting using laminin 5 purified from keratinocyte extract as the substrate for patient 1 showed that the IgG antibodies reacted with 140-kDa polypeptides identical to the  $\beta$ 3 subunit of the laminin 5 molecule.



*Fig. 3.* Clinical features and histological and immunopathological findings of patient 2. (a) Laryngoscopy demonstrated stenosis of the vocal chink, surrounded by scar tissue. (b) Blistering on the trunk. (c) Skin biopsy from the trunk revealed a subepidermal blister with an infiltration of eosinophils and neutrophils. Bar=200  $\mu$ m. (d) Direct immunofluorescence demonstrated a linear deposit of IgG at the basement membrane zone of the epidermis (arrows). (e) Indirect immunofluorescence demonstrated circulating IgG anti-basement membrane zone auto-antibodies that bound to the dermal side of 1M NaCl split normal skin (arrows).

the medication due to vertigo and nausea. She was therefore treated with doxycycline hydrochloride 100 mg, and nicotinamide 1500 mg daily. The erosions on the laryngeal mucosa and blistering of the skin improved gradually in response to this treatment. Although the stenosis of her vocal chink and trachyphonia did not improve, the breathing difficulty resolved. We searched for underlying occult cancer in this patient, but did not detect any malignancy. She showed no malignancy when followed up for 3 years.

## DISCUSSION

AECP is a chronic, autoimmune, mucous membrane-dominated, subepithelial blistering disease that occurs with equal frequency in men and women. Current estimates suggest that it comprises 5–20% of cases of mucous membrane pemphigoid (1).

Recent studies have shown that people with AECP have an increased relative risk for malignant tumours (1–3). Sadler et al. (2) reviewed 15 cases of AECP associated with cancers. Five cases had lung cancers, three had stomach cancers, two had colon cancers, two had endometrial cancers and one had ovarian cancer as solid tumours. Two cases had lymphomas. In 12 of

15 patients, the time between blister onset and cancer diagnosis was under 14 months. Patient 1 in this report is the first published case of AECP associated with prostate carcinoma. The prostate carcinoma was diagnosed one year before the onset of blistering.

Egan et al. (3) calculated the expected numbers of cancers in a cohort of 35 patients with AECP in the National Cancer Institute's Surveillance, Epidemiology, and End Results (NCI SEER) Registry. Ten of these patients (28.6%) had solid cancers and the relative risk for malignancy in this cohort was 6.8, similar to the risk for malignancy among patients with dermatomyositis. Similarly, Matsushima et al. (5) reviewed 16 cases of AECP in Japan and 5 of these cases (31.2%) were complicated with solid cancers.

Some experimental studies have demonstrated that AECP is a distinct disorder mediated by tissue-specific, pathogenic auto-antibodies against laminin 5 (6–9). Laminin 5 ( $\alpha 3\beta 3\gamma 2$ ) is a heterotrimeric protein of 460 kDa. Laminin 5 is a major adhesive component of epidermal basement membrane zone. In the skin, laminin 5 is localized to the interface of lamina lucida and the lamina densa, where it is thought to form a critical link between hemidesmosome-anchoring filament complexes, the lamina densa and underlying anchoring fibrils (10).



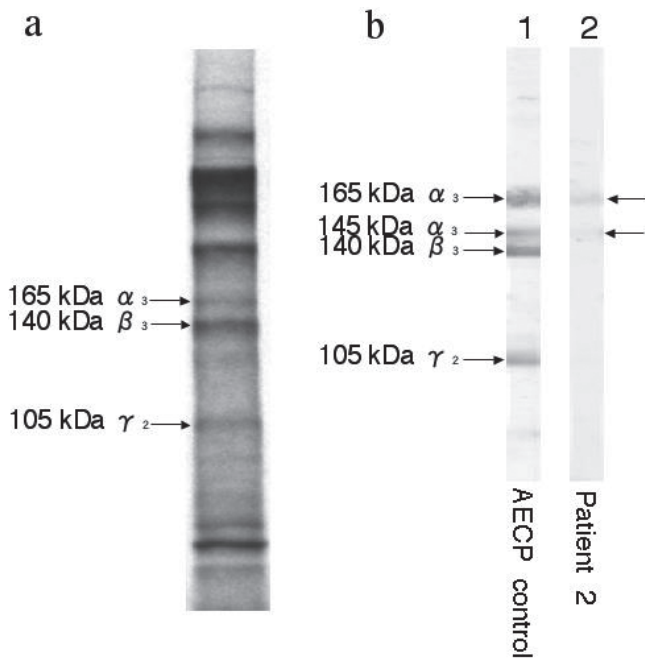


Fig. 4. Immunoprecipitation and immunoblotting of patient 2. (a) Immunoprecipitation of radiolabelled human keratinocyte extract showed the presence of anti-laminin 5 IgG antibodies in the patient's serum. (b) Immunoblotting using laminin 5 purified from keratinocyte extract as the substrate for patient 2 showed that IgG antibodies reacted with 165-kDa and 145-kDa polypeptides identical to  $\alpha_3$  subunits of the laminin 5 molecule.

The mechanism underlying the association of AECp and cancer is not fully understood, but there is emerging evidence that laminin 5 expression in cancer cells promotes their growth, invasion and metastasis (11). However, some studies showed controversial data. Hao et al. (12) reported invasive prostate carcinoma showing a loss of expression of  $\beta_3$  and  $\gamma_2$  subunits of laminin 5 with variable expression of  $\alpha_3$  subunit. Nevertheless, Taniuchi et al. (13) reported an interesting case of AECp associated with gastric carcinoma. The gastric carcinoma cells in the patient produced laminin 5 and the patient's serum contained auto-antibodies against laminin 5. Furthermore, the blistering symptoms and titre of anti-basement membrane zone antibodies coordinately changed with the resection and subsequent relapse of the gastric cancer.

Patients who present with mucous membrane pemphigoid, anti-laminin 5 auto-antibodies should be checked, and careful screening for internal malignancies should be performed in cases that are positive for anti-laminin 5 antibodies.

AECp is a chronic, insidiously progressive disease with a high mortality rate. Mortality is especially high in AECp patients who develop solid cancers in close proximity to the time of blister onset. Egan et al. (1) reported that 14 of 35 (40%) patients died during the follow-up period. Eight patients died from cancer, and 4 of the remaining 6 deaths were due to infections that developed during intensive treatment with immunosup-

pressives. The combined therapy of tetracycline and nicotinamide was reported as an effective treatment for various types of cicatricial pemphigoid (14). Patient 2 in this report, who had no detectable malignancy, was treated successfully with doxycycline and nicotinamide. For patients in whom immunosuppressive medication cannot be used in the treatment of AECp, treatment with doxycycline and nicotinamide should be considered.

## REFERENCES

- Egan CA, Lazarova Z, Darling TN, Yee C, Yancey KB. Anti-epiligrin cicatricial pemphigoid: clinical findings, immunopathogenesis, and significant associations. *Medicine (Baltimore)* 2003; 82: 177–186.
- Sadler E, Lazarova Z, Sarasombath P, Yancey KB. A widening perspective regarding the relationship between anti-epiligrin cicatricial pemphigoid and cancer. *J Dermatol Sci* 2007; 47: 1–7.
- Egan CA, Lazarova Z, Darling TN, Yee C, Cote T, Yancey KB. Anti-epiligrin cicatricial pemphigoid and relative risk for cancer. *Lancet* 2001; 357: 1850–1851.
- Vodegel RM, Jonkman MF, Pas HH, de Jong MC. U-serrated immunodeposition pattern differentiates type VII collagen targeting bullous diseases from other subepidermal bullous autoimmune diseases. *Br J Dermatol* 2004; 151: 112–118.
- Matsushima S, Horiguchi Y, Honda T, Fujii S, Okano T, Tanabe M, et al. A case of anti-epiligrin cicatricial pemphigoid associated with lung carcinoma and severe laryngeal stenosis: review of Japanese cases and evaluation of risk for internal malignancy. *J Dermatol* 2004; 31: 10–15.
- Lazarova Z, Yee C, Darling T, Briggaman RA, Yancey KB. Passive transfer of anti-laminin 5 antibodies induces subepidermal blisters in neonatal mice. *J Clin Invest* 1996; 98: 1509–1518.
- Kirtschig G, Marinkovich MP, Burgeson RE, Yancey KB. Anti-basement membrane autoantibodies in patients with anti-epiligrin cicatricial pemphigoid bind the alpha subunit of laminin 5. *J Invest Dermatol* 1995; 105: 543–548.
- Lazarova Z, Hsu R, Briggaman RA, Yancey KB. Fab fragments directed against laminin 5 induce subepidermal blisters in neonatal mice. *Clin Immunol* 2000; 95: 26–32.
- Lazarova Z, Hsu R, Yee C, Yancey KB. Human anti-laminin 5 autoantibodies induce subepidermal blisters in an experimental human skin graft model. *J Invest Dermatol* 2000; 114: 178–184.
- Masunaga T, Shimizu H, Ishiko A, Tomita Y, Aberdam D, Ortonne JP, Nishikawa T. Localization of laminin-5 in the epidermal basement membrane. *J Histochem Cytochem* 1996; 44: 1223–1230.
- Miyazaki K. Laminin-5 (laminin-332): Unique biological activity and role in tumor growth and invasion. *Cancer Sci* 2006; 97: 91–98.
- Hao J, Jackson L, Calaluce R, McDaniel K, Dalkin BL, Nagle RB. Investigation into the mechanism of the loss of laminin 5 ( $\alpha_3\beta_3\gamma_2$ ) expression in prostate cancer. *Am J Pathol* 2001; 158: 1129–1135.
- Taniuchi K, Takata M, Matsui C, Fushida Y, Uchiyama K, Mori T, et al. Antiepiligrin (laminin 5) cicatricial pemphigoid associated with an underlying gastric carcinoma producing laminin 5. *Br J Dermatol* 1999; 140: 696–700.
- Sakamoto K, Mori K, Hashimoto T, Yancey KB, Nakashima T. Antiepiligrin cicatricial pemphigoid of the larynx successfully treated with a combination of tetracycline and niacinamide. *Arch Otolaryngol Head Neck Surg* 2002; 128: 1420–1423.