

Psoriatic Skin Lesions Induced by BCG Vaccination

Kaoru Takayama, Takahiro Satoh, Miho Hayashi and Hiroo Yokozeki

Department of Dermatology, Graduate School, Tokyo Medical and Dental University, 1-5-45 Yushima, Bunkyo-ku, Tokyo 113-8519, Japan.

E-mail: tkaoru.derm@tmd.ac.jp

Accepted March 31, 2008.

Sir,

Tuberculids are cutaneous reactions that occur in response to an internal focus of tuberculosis. It is thought that tuberculids are mediated by immunological reactions to toxins or antigenic fragments of dead bacilli. We report here a case of BCG-induced tuberculid-like eruption accompanied by psoriatic skin changes.

CASE REPORT

A 6-month-old girl presented with skin eruptions that appeared following BCG vaccination that had been carried out at a local public health centre. Plaques initially appeared on the vaccination site one month after vaccination, followed by the appearance of multiple plaques on the face and extremities during the next month. Physical examination revealed multiple red papules and well-defined plaques covered by whitish-yellow scale/crust on the face and extremities, as well as at the site of BCG vaccination (Fig. 1A–C). The nails of the fingers and toes showed subungual hyperkeratosis (Fig. 1D). The patient's medical history included congenital mitral valve insufficiency, and

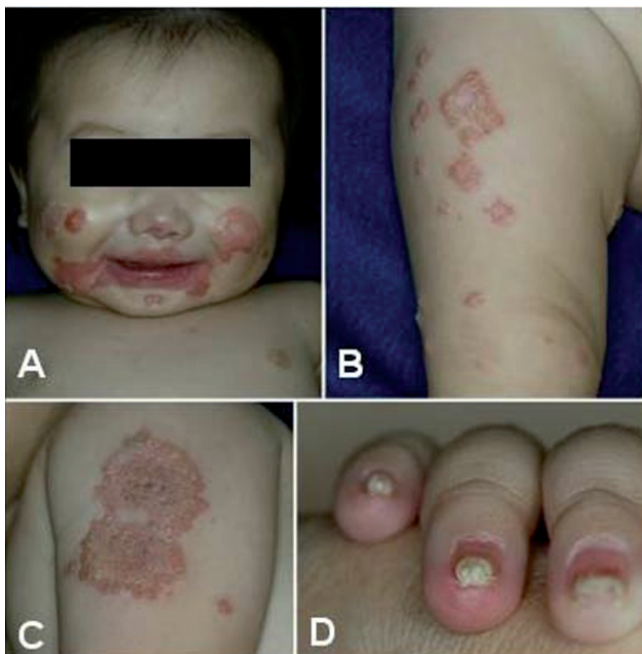

Fig. 1. Clinical manifestations. (A and B) Reddish plaques of varying sizes with scale/crust on the face and extremities. (C) Similar lesions at the BCG vaccination site. (D) All fingernails show subungual hyperkeratosis with moderate erythema.

she had no history of any other vaccination. Biopsy specimens from a plaque located on the thigh showed a marked parakeratotic hyperkeratosis with thinning of granular layers and elongation of epidermal rete ridges (Fig. 2A and B). There was a cellular infiltrate in the papillary dermis, consisting of lymphocytes and a few neutrophils. Notably, an epithelioid granuloma with minimal caseation necrosis was found in the upper dermis of the central region of the plaque (Fig. 2C). Routine blood tests and chest X-rays showed no abnormal findings. Mycobacterium could not be isolated on bacterial cultures. In addition, mycobacterial DNA was not detected by polymerase chain reaction analysis. The patient had no family history of tuberculosis and/or psoriasis. With no specific treatment, the skin lesions, including the nail changes, improved spontaneously without scarring within 3 months.

DISCUSSION

BCG vaccination has been shown occasionally to be associated with cutaneous tuberculid-like reactions, including papular-, papulonecrotic-, and lichen scrofulosorum-like eruptions (1–3). We have presented a patient with an unusual type of tuberculid-like eruption caused by BCG vaccination. While there was an epithelioid granuloma in the dermis, the overlying epidermis exhibited a marked parakeratotic hyperkeratosis with regular elongation of rete ridges; these findings are morphologically similar to those of psoriasis. The skin lesions improved spontaneously with no medications, which ruled out a possible active *Mycobacterium tuberculosis* and/or *bovis* infection.

The aetiological relationship between psoriatic reactions and BCG vaccination is uncertain. An early report described a case of psoriasis following BCG vaccination under the name of “psoriasis vaccinalis” (4). BCG vaccination has also been reported to cause guttate psoriasis-like eruptions and psoriatic arthropathy (5, 6).

Currently, it is thought that the pathological mechanisms responsible for psoriasis are related to IL-22, a Th17 cell-derived cytokine, which is a key player in the development of the characteristic epidermal changes of psoriasis (7). IL-22 activates epidermal Stat-3 (8), a member of signal transducers and activators of transcription (Stats), which is essential for the epidermal proliferation in psoriasis (9). In the present case, expression of activated phospho-Stat-3 was found in the epidermal keratinocytes of the lesional skin (Fig. 2D).

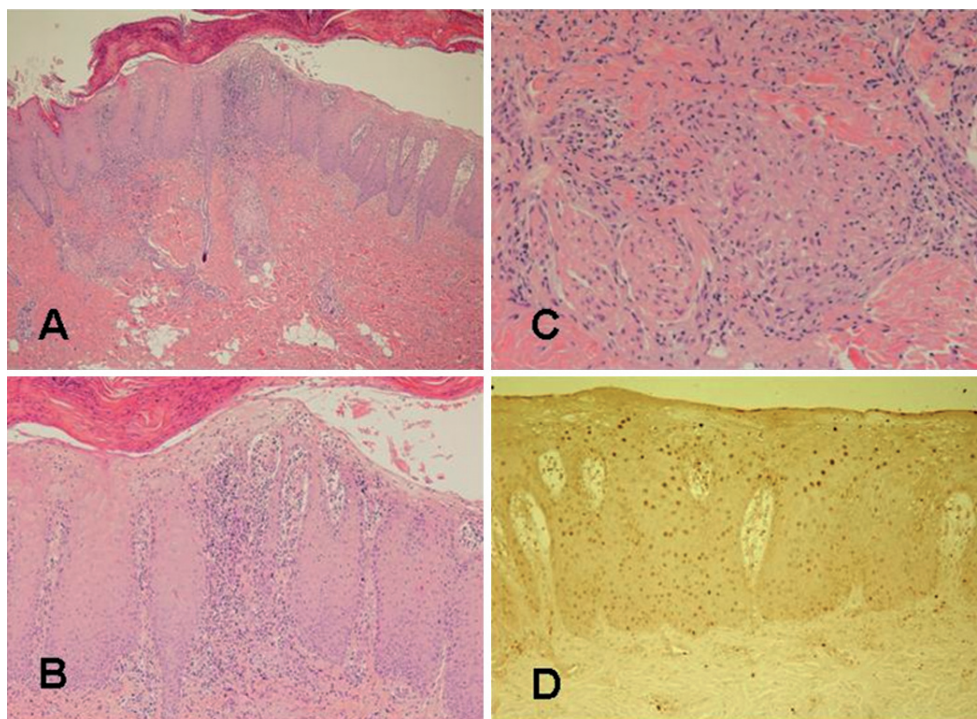


Fig. 2. Histological features of the lesion. (A) The plaque located on the thigh shows hyperkeratotic acanthosis with a dermal cellular infiltrate. (B) The epidermal changes are characterized by marked parakeratotic hyperkeratosis, regular elongation of rete ridges, and thinning of granular layers. (C) There is an epithelioid granuloma in the upper dermis. (D) Phospho-Stat3 is expressed in the nuclei of the epidermal keratinocytes (Phospho-Stat-3 (Tyr705) antibody, Cell Signaling Technology Inc., Beverly, MA, USA).

Mycobacterial heat shock proteins have been found to stimulate IL-6 production by lymphocytes and/or monocytes/macrophages (10–12). IL-6 promotes the development of Th17 cells (13, 14). Consistent with these findings, mice infected with BCG generate Th17 cells *in vivo* (15). Thus, it can be speculated that an immunological reaction to BCG vaccination might mediate the generation of IL-22-producing Th17 cells and lead to the activation of epidermal Stat-3 and a psoriatic skin reaction.

REFERENCES

- De Bruyne JI, Van Creveld S, Prakken JR, Stoppelman MR. Papular tuberculids after BCG vaccination. *Acta Derm Venereol* 1953; 33: 385–390.
- Takada T, Yamashita T, Sato M, Kawakami Y, Tominaga A, Ono I, et al. Papulonecrotic tuberculid-like eruptions after Bacille Calmette-Guerin vaccination. *J Dermatol* 2007; 34: 183–188.
- Warner J. Lichen scrofulosorum following B.C.G. *Br J Dermatol* 1966; 78: 549.
- Raaschou-Nielsen W. Psoriasis vaccinalis; report of two cases, one following B.C.G. vaccination and one following vaccination against influenza. *Acta Derm Venereol* 1955; 35: 37–42.
- Koca R, Altinyazar HC, Numanoglu G, Unalacak M. Guttate psoriasis-like lesions following BCG vaccination. *J Trop Pediatr* 2004; 50: 178–179.
- Queiro R, Ballina J, Weruaga A, Fernandez JA, Riestra JL, Torre JC, et al. Psoriatic arthropathy after BCG immunotherapy for bladder carcinoma. *Br J Rheumatol* 1995; 34: 1097.
- Zheng Y, Danilenko DM, Valdez P, Kasman I, Eastham-Anderson J, Wu J, et al. Interleukin-22, a T(H)17 cytokine, mediates IL-23-induced dermal inflammation and acanthosis. *Nature* 2007; 445: 648–651.
- Sa SM, Valdez PA, Wu J, Jung K, Zhong F, Hall L, et al. The effects of IL-20 subfamily cytokines on reconstituted human epidermis suggest potential roles in cutaneous innate defense and pathogenic adaptive immunity in psoriasis. *J Immunol* 2007; 178: 2229–2240.
- Sano S, Chan KS, Carbajal S, Clifford J, Peavey M, Kiguchi K, et al. Stat3 links activated keratinocytes and immunocytes required for development of psoriasis in a novel transgenic mouse model. *Nat Med* 2005; 11: 43–49.
- Dubaniewicz A, Trzonkowski P, Dubaniewicz-Wybieralska M, Dubaniewicz A, Singh M, Mysliwski A. Mycobacterial heat shock protein-induced blood T lymphocytes subsets and cytokine pattern: comparison of sarcoidosis with tuberculosis and healthy controls. *Respirology* 2007; 12: 346–354.
- Retzlaff C, Yamamoto Y, Hoffman PS, Friedman H, Klein TW. Bacterial heat shock proteins directly induce cytokine mRNA and interleukin-1 secretion in macrophage cultures. *Infect Immun* 1994; 62: 5689–5693.
- Friedland JS, Shattock R, Remick DG, Griffin GE. Mycobacterial 65-kD heat shock protein induces release of proinflammatory cytokines from human monocytic cells. *Clin Exp Immunol* 1993; 91: 58–62.
- Liang SC, Tan XY, Luxenberg DP, Karim R, Dunussi-Joannopoulos K, Collins M, et al. Interleukin (IL)-22 and IL-17 are coexpressed by Th17 cells and cooperatively enhance expression of antimicrobial peptides. *J Exp Med* 2006; 203: 2271–2279.
- Betelli E, Carrier Y, Gao W, Korn T, Strom TB, Oukka M, et al. Reciprocal developmental pathways for the generation of pathogenic effector TH17 and regulatory T cells. *Nature* 2006; 441: 235–238.
- Cruz A, Khader SA, Torrado E, Fraga A, Pearl JE, Pedrosa J, et al. Cutting edge: IFN-gamma regulates the induction and expansion of IL-17-producing CD4 T cells during mycobacterial infection. *J Immunol* 2006; 177: 1416–1420.