

CLINICAL REPORT

Targeted Broadband Ultraviolet B Phototherapy Produces Similar Responses to Targeted Narrowband Ultraviolet B Phototherapy for Vitiligo: A Randomized, Double-blind Study

Pravit ASAWANONDA, Jirasin KIJLUAKIAT, Wiwat KORKIJ and Wannasri SINDHUPAK

Division of Dermatology, Department of Medicine, Faculty of Medicine, Chulalongkorn University, Bangkok, Thailand

Narrowband ultraviolet B (NB-UVB) phototherapy, with a 308-nm xenon chloride excimer laser, and targeted UVB phototherapy have produced encouraging therapeutic results for vitiligo. However, very few studies employing broadband UVB exist. Moreover, there has been no direct comparison study between broadband UVB and NB-UVB for the treatment of vitiligo. The aims of this study were to compare the repigmenting efficacy of targeted broadband UVB phototherapy with that of NB-UVB in an equi-erythemogenic manner. Twenty identical vitiliginous lesions from 10 patients were randomly allocated to receive either targeted broadband UVB or targeted NB-UVB phototherapy. UV fluences were started at 50% of the minimal erythema dose detected within the vitiliginous patches, then increased gradually, in the same manner, to ensure equi-erythemogenic comparison. Treatments were carried out twice weekly for 12 weeks. The results show that grade 1, i.e. 1–25% repigmentation, to grade 2, 26–50% repigmentation, occurred in 6 of 10 subjects. Responses in terms of repigmentation, de-pigmentation, or lack thereof, were similar between lesions receiving broadband and NB-UVB phototherapy. Onset of repigmentation occurred as early as 4 weeks of treatment in most subjects. Treatments were well tolerated, with only minimal erythema and hyperpigmentation. Limitations: the study was carried out in a small number of patients with skin types III, IV and V. The irradiation device was a targeted UVB device and thus the results may not be applicable to other light sources, such as the excimer laser or total-body irradiation cabinets. In conclusion, targeted broadband UVB produces similar clinical responses to targeted NB-UVB in the treatment of the non-segmental type of vitiligo. *Key words: targeted phototherapy; vitiligo; narrowband UVB; broadband UVB; ultraviolet.*

(Accepted February 11, 2008.)

Acta Derm Venereol 2008; 88: 376–381.

Pravit Asawanonda, Division of Dermatology, Department of Medicine, Chulalongkorn University, Rama 4 Road, Bangkok 10330, Thailand. E-mail: pravit@adsl.loxinfo.com

Vitiligo is a very common depigmenting disorder that affects a large number of patients worldwide. The condition

is not harmful, but may be mistaken for a more serious condition, such as leprosy, by people in some parts of the world, thus resulting in psychological damage.

Total-body narrowband ultraviolet B (NB-UVB) phototherapy, at a wavelength of 311–313 nm, is now the mainstay of treatment for generalized vitiligo (1, 2). Compared with psoralen photochemotherapy (PUVA), NB-UVB has been shown to produce at least equal, or even better, repigmentation capability (1). These total-body treatments, however, are associated with undue burning and skin ageing of the unaffected skin when administered long-term.

There are numerous studies employing different targeted UVB devices, namely the 308-nm xenon chloride (XeCl) excimer laser (3–13) and other targeted UVB light sources, such as monochromatic excimer light (MEL) (14), microphototherapy (15, 16), and our own report using a targeted broadband UVB (BB-UVB) system (DuaLight™) (17), and excellent repigmentation of more than 75% has been observed.

The fact that targeted BB-UVB phototherapy results in repigmentation in vitiligo, even in the segmental type (17), similar to the results seen with phototherapy using a narrower spectrum, prompted us to conduct a randomized study to compare the efficacies of targeted BB-UVB and targeted NB-UVB in an equi-erythemogenic manner. As most studies using this type of irradiation device have demonstrated that repigmentation occurs more rapidly than that from total-body irradiation (5, 10, 14), our primary question was whether NB-UVB produces better repigmentation within the first 12 weeks of irradiation. However, we also continued our study to 24 weeks to allow us to determine the effect of longer-term treatments.

MATERIALS AND METHODS

Patients

Patients, aged 16 years or older, with stable focal or generalized vitiligo were eligible to enter the study. Stable vitiligo was defined as lack of repigmentation, or depigmentation within 8 weeks of recruitment into the study. Wash-out periods of 4 weeks for all forms of phototherapy, and 2 weeks for topical treatments, were required. Patients with a history of skin cancers, photosensitive conditions, such as xeroderma pigmentosum, solar urticaria, chronic actinic dermatitis or lupus erythematosus, and those who were pregnant or lactating were excluded.

The study protocol was approved by the ethics committee of the Faculty of Medicine, Chulalongkorn University. Informed consent was obtained from each participant prior to the start of treatment.

Study lesions

Lesions in sun-protected areas, within the same anatomical area, and on the same side of the body, were chosen as preferred study patches. If this was not possible, then lesions symmetrically located in contralateral areas were allowed. Lesions were then randomized, using randomization cards, to receive either targeted BB-UVB or targeted NB-UVB. Lesions were mapped and digitally photographed (Fujifilm, FINEPIX S3 Pro, Tokyo, Japan) at baseline and every 4 weeks thereafter. The photographs were all taken using the same camera settings.

Device

The irradiation source used in this study, DuaLight™ (TheraLight, Inc. Carlsbad, CA 92008, USA), was a high-pressure mercury lamp capable of emitting either BB-UVB or NB-UVB via a switch on the hand-piece. The BB-UVB spectral output of this light source includes peaks at 302 nm and 312 nm, with an average weighted erythema wavelength of 304 nm, while that of NB-UVB has only one major peak at 313 nm and an average weighted erythema of 311 nm. The high output of this device allows irradiation of 100 mJ/cm² of UVB to occur within approximately 0.7 sec. UV radiation is delivered through a square aperture, measuring 1.9 × 1.9 cm.

Protocol

Minimal erythema doses (MEDs) of both BB-UVB and NB-UVB were determined within the vitiliginous patches (MED-VIT) prior to start of irradiation. The DuaLight™ system is equipped with an MED determination function, with set increasing doses of light for each skin type. This allows one to deliver 6 different doses of light within a period of 1–2 min. As vitiliginous lesions are commonly devoid of any pigment, we chose the pre-set doses for skin type I, i.e. 45, 60, 75, 90, 105 and 120 mJ/cm² for BB-UVB, and 90, 150, 210, 300, 360 and 420 mJ/cm² for NB-UVB. In cases where MEDs could not be determined, we gradually increased the doses to 2000 mJ/cm² for NB-UVB and 600 mJ/cm² for BB-UVB. If the MEDs still could not be determined, we commenced light treatment with the highest fluences used at MED testing. Starting fluences of both UV lights were 50% of the pre-determined MEDs. Treatments were carried out twice weekly, with at least 24 h between treatments. UV doses were increased by 10% if no erythema or discomfort developed from the prior irradiation, 5% with minor erythema not lasting longer than 24 h, and no increments if the erythema lasted more than 24 h. Treatments were to be skipped if significant erythema or blistering developed. Light fluences were increased until the first sign of repigmentation or mild erythema was observed. Treatments were continued until complete repigmentation occurred or for 12 weeks.

Evaluation of efficacy

Three investigators blinded to the treatment assignment (PA, WS and WK) independently graded the lesions through examining the digital images. The grading system for improvement, used by most investigators (18, 19) was as follows: grade 0, no change; grade 1, 1–25%; grade 2, 26–50%; grade 3, 51–75%; and grade 4, 76–100% improvements. Because we anticipated that worsening of lesions might occur, we also included 4 more grades for depigmentation, i.e. grade –1, 1–25% depigmenta-

tion; grade –2, 26–50% depigmentation; grade –3, 51–75% depigmentation and grade –4, > 75% depigmentation.

Statistical analysis

A Wilcoxon signed-rank test was used to compare the degree of repigmentation between targeted NB-UVB and targeted BB-UVB in each patient at the 4th, 8th, 12th, 16th, 20th and 24th weeks. In all instances, $p < 0.05$ was considered statistically significant. Statistical analysis was carried out with SPSS version 11.5 software (SPSS Inc., Chicago, IL, USA).

RESULTS

Ten patients, 7 women and 3 men, enrolled and completed the first 12 weeks of the study. Patients 1, 4 and 8 dropped out at the 16th, 20th and 16th weeks due to difficulties in work scheduling. Nine patients had generalized vitiligo, while one had localized disease. Past treatments included topical steroids, topical pimecrolimus, topical tacrolimus, topical meladinine plus sunlight (PUVASOL) and total body NB-UVB, with variable success. One patient had type 2 diabetes mellitus, and one had hyperthyroidism; both were well-controlled. The demographic features of the patients are shown in Table I. The skin phototype, location of lesions and MED for each patient are shown in Table II.

The MEDs-VIT for NB-UVB and BB-UVB could be detected in all but one subject (patient 2), whose lesions were primarily on the dorsum of the hands. It should also be noted that repigmentation did not occur in this patient. In all instances, as expected, the MED_{NB-UVB} of vitiliginous patches were higher than MED_{BB-UVB} with the mean MED_{NB-UVB}, excluding the only outlier value

Table I. Demographic features of the patients

Characteristics	
Sex, men/women (<i>n</i>)	3/7
Age, mean ± SD (range) (years)	41.8 ± 12.82 (22–66)
Duration of vitiligo (years), <i>n</i> (%)	
0–5	5 (50)
6–10	3 (30)
11–15	1 (10)
16–20	1 (10)
Age at onset (years), <i>n</i> (%)	
21–30	3 (30)
31–40	5 (50)
41–50	1 (10)
51–60	1 (10)
Skin phototype, <i>n</i> (%)	
III	3 (30)
IV	4 (40)
V	3 (30)
Family history of vitiligo (<i>n</i>)	
Yes	2
No	8
Underlying disease (<i>n</i>)	
Diabetes mellitus	1
Hyperthyroidism	1
None	8

SD: standard deviation

Table II. Skin phototype, location of study lesions, and minimal erythema doses (MEDs) of targeted narrowband (NB) UVB and targeted broadband (BB) UVB

Patient	Skin phototype	Location of study lesion	MED _{BB-UVB} (mJ/cm ²)	MED _{NB-UVB} (mJ/cm ²)
1	V	Feet	480	1800
2	IV	Hand	Undetectable	Undetectable
3	III	Neck	50	90
4	V	Leg	90	330
5	IV	Buttock	120	180
6	III	Face	90	150
7	III	Trunk	90	135
8	V	Leg	90	330
9	IV	Abdomen	120	330
10	IV	Forearms	150	180

in subject 1, being 185.62 ± 92.79 mJ/cm², while that of BB-UVB was 130 ± 88.96 mJ/cm².

Compliance was excellent; in fact only one patient missed 2 treatments within the first 12 weeks. All others received 24 treatments. The number of treatments, as well as cumulative doses of NB-UVB and BB-UVB received in the 12 and 24 weeks, are shown in Table III. There was also strong inter-rater agreement, with all physicians giving the same gradings for all time-points.

Overall, repigmentation from either type of light treatment was very similar (Fig. 1), with the difference never more than 1 grade. At all time-points, repigmentation during treatment between the two groups was not statistically significantly different at the 4th week ($p=0.083$), 8th week ($p=0.564$), 12th week ($p=1.000$), 16th week, ($p=0.564$), 20th week ($p=1.000$), or 24th week ($p=0.705$, Wilcoxon signed-rank test).

At 12 weeks, repigmentation occurred in 6 lesions that had received BB-UVB, and 5 that had received NB-UVB. Grade 2, namely 26–50% repigmentation, occurred in 2 patients on NB-UVB and 2 on BB-UVB. The remainder had grade 1, 1–25% repigmentation. When repigmentation occurred, it was evident within the first 4 weeks of treatment in all instances (Fig. 1).

At 24 weeks, when 7 patients were available, similar

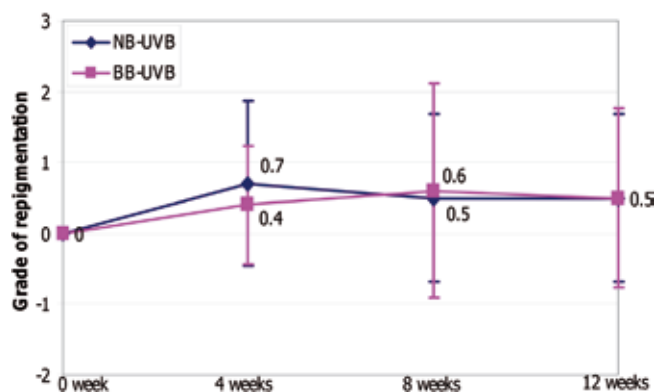


Fig. 1. Overall repigmentation at 4th, 8th and 12th week ($n=10$). NB-UVB: narrowband ultraviolet B; BB-UVB: broadband ultraviolet B.

responses to both forms of light treatment were still maintained, with no further repigmentation or depigmentation.

Two patients did not respond to either type of phototherapy (Fig. 2). In patient number 2, the lesions were on the dorsal hands, an area notorious for lack of repigmentation from all forms of UV light treatment. In yet another subject, patient 3, the lesions were located on the neck.

Depigmentation occurred in 2 patients, 2 from BB-UVB and whereof one also from NB-UVB (Fig. 2). Again, these 2 patients were non-responders to other forms of treatments including topical tacrolimus and total-body NB-UVB. In addition, in both subjects, depigmentation was noted on other parts of the body; however, no definite triggers could be elucidated.

Fig. 3 demonstrates similar repigmentation from BB-UVB and NB-UVB observed at 12 weeks in patient number 9.

Treatments were otherwise well tolerated by all subjects. Some peri-lesional pigmentation (Fig. 3) and mild to moderate erythema, not necessitating cessation of treatment, occurred in all patients. No blistering erythema occurred at any of the treated sites.

Table III. Number of treatments and cumulative ultraviolet B (UVB) doses received by subjects

Patient	Number of treatments received (in 12 weeks)	Cumulative UVB dose (mJ/cm ²)			
		Targeted broadband UVB		Targeted narrowband UVB	
		12 weeks	24 weeks	12 weeks	24 weeks
1	24	11630	11630	41730	41730
2	24	17610	69720	27895	106795
3	24	1260	3280	2235	6465
4	24	3005	5400	7185	11145
5	24	3680	8510	4840	10170
6	24	1970	3680	3600	6830
7	22	2615	2615	3985	3985
8	24	3250	10500	6460	18670
9	24	3825	7825	6980	14180
10	24	4195	8695	5640	11400

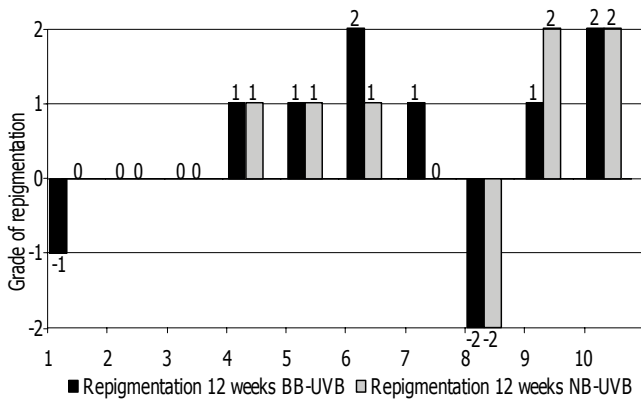


Fig. 2. Individual repigmentation gradings at 12 weeks (n=10). BB-UVB: broadband UVB; NB-UVB: narrowband UVB.

DISCUSSION

Several reports exist for 308-nm XeCl excimer laser treatment (3–13) and other targeted UVB light sources, such as monochromatic excimer light (MEL) (14) and microphototherapy (15, 15) for vitiligo, with variable results. In a study by Taneja et al. (18), some degree of repigmentation was observed in all subjects after 40–60 treatments. This repigmentation was excellent, more than 75%, on the face in all of their participants. Esposito et al. (9) achieved excellent repigmentation in 7 of 24 patients treated with the same laser system. In another study, some repigmentation occurred in 9 of 11 patients (82%) after 12 treatments. However, repigmentation of more than 75% occurred in only 2 of 11 patients (5). In yet another study, a different focus, NB-UVB system, termed “microphototherapy” by Menchini et al. (16), was used. After variable numbers of treatments given over a course of 12 months (mean 24 sessions), 510 of the 734 subjects (69.5%) achieved normal pigmentation on more than 75% of the treated areas. Of these, 112 were totally repigmented.

It is, however, difficult to compare the responses obtained from these studies, because different irradiation protocols, numbers of treatments and, importantly, different light sources, were used. Apart from the

treatment parameters, several other factors affect the therapeutic outcome, most importantly, the anatomical locations of lesions (5–11, 16, 18, 20). Skin types (5, 7, 8, 12, 20, 21), age (7, 8, 12, 20, 21), sex (7, 8, 12, 20, 21), duration of disease (7–9, 12, 20, 21), response to previous treatments including phototherapy (6, 8, 10, 14) are less predictable prognostic factors. To overcome the effects of these confounders, we performed our study in a randomized, double-blind, MED-based, equi-erythemogenic manner using the same irradiation device. We also excluded segmental vitiligo, which is notoriously difficult to treat even with targeted light sources (12, 21).

Despite the very few studies using total-body BB-UVB for vitiligo (22, 23), we were encouraged by the results from our previous study in which repigmentation was observed from targeted BB-UVB phototherapy (17). In the present report, although conducted in a small number of subjects, we demonstrated that when similar irradiation schedules are used, the efficacy of targeted BB-UVB can be similar to that of NB-UVB, such that when repigmentation occurred, it occurred to a similar degree. Importantly, when de-pigmentation occurred it did so with both types of light sources.

One advantageous feature seen with targeted UV treatment for vitiligo is the rapid onset of therapeutic results. In the study reported herein, repigmentation occurred within the first 4 weeks of treatment, i.e. 8 phototherapeutic sessions, in line with other studies in which onset of repigmentation was noted within the first 5–12 treatments (5, 10, 24). More rapid onset of repigmentation within the first 4–8 treatments has been reported with the use of MEL (14).

Although repigmentation could be seen early in the course of treatment, to achieve significant repigmentation, i.e. 75% or greater, continued treatment may be necessary. Unfortunately, we did not see further improvement in pigmentation grading when treatments were extended to 24 weeks.

The fact that the repigmentation observed in this study was not more than grade 2 warrants some discussion. First, the starting UV doses used in our study may be

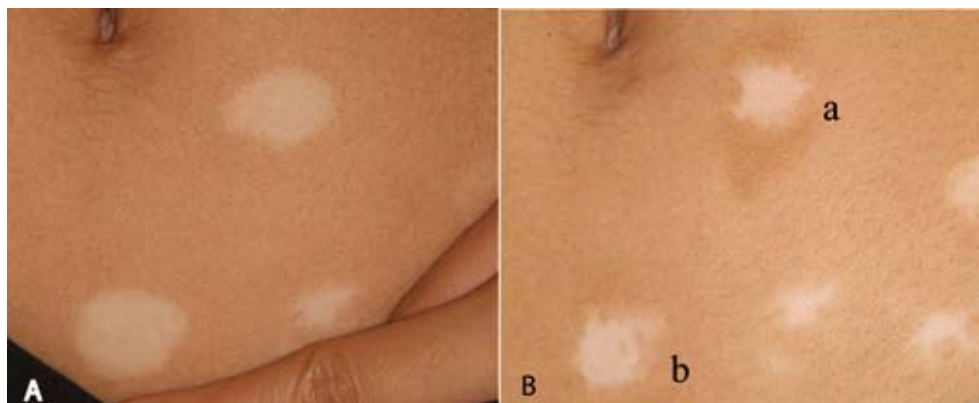


Fig. 3. Patient 9: (A) Baseline. (B) Grade 1 pigmentation at 12 weeks from targeted broadband UVB (a) and targeted narrowband UVB (b).

slightly on the lower side, compared with other studies in which starting doses at MED-VIT minus 50 mJ/cm² were used (12, 24). However, our design, which was to employ equi-erythemogenic fluences of UV light, did not allow us to use such fixed starting doses. Notably, the mean MED-VIT_{NB-UVB} of 185.62 ± 92.79 mJ/cm² in the present study, when an outlier MED in one subject (patient 1) was excluded, is in agreement with MED_{NB-UVB} detected within the lesions reported in other studies (16, 24).

Secondly, as stated above, the most important prognostic factor demonstrated from numerous studies is the location of lesions (5–11, 16, 18, 20). In general, lesions on the face and neck respond quite readily to topical treatments and UV light therapy. Truncal lesions and those on the proximal extremities do respond somewhat, while those in the peri-oral and distal extremities are most recalcitrant to all forms of treatments.

Within the so-called “UV-sensitive areas” Ostovari et al. (7) found no difference in the repigmentation response to 308-nm XeCl excimer laser. On the other hand, lesions within the UV-resistant areas can behave differently, with lesions on the dorsal hands, feet as well as ankles responding very poorly to laser treatment. In our patients half of the study patches were on the extremities (Table II), which could have affected the outcome. This is also supported by Taneja et al. (18), who reported that despite success in other parts of the body, only grade 1 repigmentation was seen in such areas and then only in a small number of study subjects.

Finally, the number as well as duration of treatment may be important to the final outcome of UV light treatment, especially for total-body NB-UVB phototherapy (1, 25). However, this did not seem to be the case in our study, as we did not observe further improvement in pigmentation grading when treatments were extended to 24 weeks. This is not surprising, as it has been shown that, at least for XeCl excimer laser and MEL, if repigmentation does not occur within the first 20 treatments, improvement beyond that time point is less likely (6, 14).

In summary, we have demonstrated that targeted BB-UVB is a useful tool for the treatment of localized vitiligo, with efficacy similar to that of NB-UVB. Whether this could be applied to total-body BB-UVB irradiation remains to be studied. Also, given the reported success of XeCl excimer laser and targeted light sources for other localized leukodermas, such as post-laser hypopigmentation (26, 27), it would be interesting to study how targeted BB-UVB fare with these difficult leukodermas.

REFERENCES

1. Westerhof W, Nieuweboer-Krobotova L. Treatment of vitiligo with UV-B radiation vs topical psoralen plus UV-A. *Arch Dermatol* 1997; 133: 1525–1528.
2. Scherschun L, Kim JJ, Lim HW. Narrow-band ultraviolet B is a useful and well-tolerated treatment for vitiligo. *J Am Acad Dermatol* 2001; 44: 999–1003.
3. Baltás E, Nagy P, Bónis B, Novák Z, Ignác F, Szabó G, et al. Repigmentation of localized vitiligo with the xenon chloride laser. *Br J Dermatol* 2001; 144: 1266–1267.
4. Baltás E, Csoma Z, Ignacz F, Dobozy A, Kemeny L. Treatment of vitiligo with the 308-nm xenon chloride excimer laser. *Arch Dermatol* 2002; 138: 1619–1620.
5. Spencer JM, Nossa R, Ajmeri J. Treatment of vitiligo with the 308-nm excimer laser: a pilot study. *J Am Acad Dermatol* 2002; 46: 727–731.
6. Choi KH, Park JH, Ro YS. Treatment of vitiligo with 308-nm xenon-chloride excimer laser: therapeutic efficacy of different initial doses according to treatment areas. *J Dermatol* 2004; 31: 284–292.
7. Ostovari N, Passeron T, Zakaria W, Fontas E, Larouy JC, Blot JF, et al. Treatment of vitiligo by 308-nm excimer laser: an evaluation of variables affecting treatment response. *Lasers Surg Med* 2004; 35: 152–156.
8. Hadi SM, Spencer JM, Lebwohl M. The use of the 308-nm excimer laser for the treatment of vitiligo. *Dermatol Surg* 2004; 30: 983–986.
9. Esposito M, Soda R, Costanzo A, Chimenti S. Treatment of vitiligo with the 308 nm excimer laser. *Clin Exp Dermatol* 2004; 29: 133–137.
10. Hong SB, Park HH, Lee MH. Short-term effects of 308-nm xenon-chloride excimer laser and narrow-band ultraviolet B in the treatment of vitiligo: a comparative study. *J Korean Med Sci* 2005; 20: 273–278.
11. Hadi S, Tinio P, Al-Ghaithi K, Al-Qari H, Al-Helalat M, Lebwohl M, Spencer J. Treatment of vitiligo using the 308-nm excimer laser. *Photomed Laser Surg* 2006; 24: 354–357.
12. Hofer A, Hassan AS, Legat FJ, Kerl H, Wolf P. The efficacy of excimer laser (308 nm) for vitiligo at different body sites. *J Eur Acad Derm Venereol* 2006; 20: 558–564.
13. Greve B, Raulin C, Fischer E. Excimer laser treatment of vitiligo – critical retrospective assessment of own results and literature overview. *J Dtsch Dermatol Ges* 2006; 4: 32–40.
14. Leone G, Iacovelli P, Paro Vidolin A, Picardo M. Monochromatic excimer light 308 nm in the treatment of vitiligo: a pilot study. *J Eur Acad Dermatol Venereol* 2003; 17: 531–537.
15. Lotti TM, Menchini G, Andreassi L. UV-B radiation micro-phototherapy. An elective treatment for segmental vitiligo. *J Eur Acad Derm Venereol* 1999; 13: 102–108.
16. Menchini G, Tsourelis-Nikita E, Hercogova J. Narrow-band UV-B micro-phototherapy: a new treatment for vitiligo. *J Eur Acad Dermatol Venereol* 2003; 17: 171–177.
17. Asawanonda P, Charoenlap M, Korkij W. Treatment of localized vitiligo with targeted broadband UVB phototherapy: a pilot study. *Photodermatol Photoimmunol Photomed* 2006; 22: 133–136.
18. Taneja A, Trehan M, Taylor C. 308-nm excimer laser for the treatment of localized vitiligo. *Int J Dermatol* 2003; 42: 658–662.
19. Natta R, Somsak T, Wisuttida T, Laor L. Narrowband ultraviolet B radiation therapy for recalcitrant vitiligo in Asians. *J Am Acad Dermatol* 2003; 49: 473–476.
20. Passeron T, Ostovari N, Zakaria W, Fontas E, Larrouy JC, Lacour JP, Ortonne JP. Topical tacrolimus and the 308-nm excimer laser: a synergistic combination for the treatment of vitiligo. *Arch Dermatol* 2004; 140: 1065–1069.
21. Lu-yan T, Wen-wen F, Lei-hong X, Yi J, Zhi-zhong Z. Topical tacalcitol and 308-nm monochromatic excimer light: a synergistic combination for the treatment of vitiligo. *Photodermatol Photoimmunol Photomed* 2006; 22: 310–314.

22. Hartmann A, Lurz C, Hamm H, Brocker EB, Hofmann UB. Narrow-band UVB311 nm vs. broad-band UVB therapy in combination with topical calcipotriol vs. placebo in vitiligo. *Int J Dermatol* 2005; 44: 736–742.
23. Don P, Iuga A, Dacko A, Hardick K. Treatment of vitiligo with broadband ultraviolet B and vitamins. *Int J Dermatol* 2006; 45: 63–65.
24. Hofer A, Hassan AS, Legat FJ, Kerl H, Wolf P. Optimal weekly frequency of 308-nm excimer laser treatment in vitiligo patients. *Br J Dermatol* 2005; 152: 981–985.
25. Nicolaidou E, Antoniou C, Stratigos AJ, Stefanaki C, Katsambas AD. Efficacy, predictors of response, and long-term follow-up in patients with vitiligo treated with narrowband UVB phototherapy. *J Am Acad Dermatol* 2007; 56: 274–278.
26. Gundogan C, Greve B, Hausser I, Raulin C. Repigmentation of persistent laser-induced hypopigmentation after tattoo ablation with the excimer laser. *Hautarzt* 2004; 55: 549–552.
27. Raulin C, Greve B, Warncke SH, Gundogan C. Excimer laser. Treatment of iatrogenic hypopigmentation following skin resurfacing. *Hautarzt* 2004; 55: 746–748.