

## Keratitis-Ichthyosis-Deafness Syndrome Lacking Subjective Hearing Impairment

Ikue Nemoto-Hasebe<sup>1</sup>, Masashi Akiyama<sup>1</sup>, Nanako Yamada<sup>2</sup>, Yoshitsugu Inoue<sup>3</sup>, Chizu Touge<sup>3</sup> and Hiroshi Shimizu<sup>1</sup>

<sup>1</sup>Department of Dermatology, Hokkaido University Graduate School of Medicine, Sapporo, and Departments of <sup>2</sup>Dermatology and <sup>3</sup>Ophthalmology and Visual Science, Faculty of Medicine, Tottori University, Yonago, Tottori, Japan. E-mail: i-nemoto@med.hokudai.ac.jp  
Accepted January 23, 2008.

Sir,

Keratitis-ichthyosis-deafness syndrome (KID; MIM #148210) is a congenital ectodermal dysplasia characterized by the association of hyperkeratotic skin lesions with vascularizing keratitis and sensorineural hearing loss. The sensorineural hearing loss in KID syndrome is generally prelingual and profound. We report here a patient with KID syndrome who had typical cutaneous and ocular symptoms, but who showed remarkably mild hearing impairment.

### CASE REPORT

The patient was a 55-year-old Japanese woman with no family history of skin disorders or auditory dysfunction. She had been treated by ophthalmologists for 17 years for decreased vision. Her ophthalmological examination showed thickened lids without trichiasis in the upper lids, superficial corneal stromal vascularization and keratoconjunctivitis. She had severe skin dryness, hyperkeratotic plaques on her extremities, reticulated leather-like hyperkeratosis on the palms and soles and sparse hair. At 54 years of age, she was diagnosed with KID syndrome from her ocular and skin involvement. Although she has no subjective hearing dysfunction, detailed auditory examinations including pure-tone audiometry revealed mild bilateral neurosensory high-frequency hearing impairment.

With informed consent, the patient's peripheral blood samples were obtained and genomic DNA was extracted from the peripheral blood leukocytes using an extraction kit (Qiagen, Hilden, Germany). Genomic DNA samples from 50 healthy Japanese individuals were used as controls. The entire coding region and exon/intron boundaries of *GJB2* were amplified by PCR using the specific primers described previously (1). PCR products were purified using a QIAquick PCR purification kit (Qiagen) and were subject to direct sequencing using an ABI PRISM 3100 genetic analyser (ABI Advanced Biotechnologies, Columbia, MD, USA). All products were sequenced in the forward and reverse orientations.

Direct sequencing of genomic DNA revealed that the patient was heterozygous for a missense mutation c.148G>A, which results in an amino acid substitution from aspartic acid to asparagine (p.Asp50Asn). This mutation is known to be a recurrent mutation that is frequently associated with KID syndrome. In addition, we demonstrated that the patient was homozygous for a polymorphism, p.Val27Ile, and heterozygous for another polymorphism, p.Glu114Gly (2). We studied allele frequency of these 2 polymorphisms in 100 normal unrelated alleles (50 Japanese individuals) and the allele frequencies of p.Val27Ile and p.Glu114Gly were 0.76 and 0.32, respectively. In order to clarify whether the missense mutation and 2 polymorphisms occur in a single allele, TA cloning of the patient's *GJB2* was performed using the PCR product from the patient as a template for cDNA cloning, as described previously (3). The mutant allele with c.148G>A (p.Asp50Asn) subcloned in the pcDNA2.1 vector also had the 2 polymorphisms p.Val27Ile and p.Glu114Gly.

### DISCUSSION

Dominant mutations in the connexin 26 gene, *GJB2* have been shown to cause KID syndrome (1). Connexins are integral membrane proteins forming aqueous gap junction channels that allow the diffusional exchange of ions and small metabolites between cells. In human skin, only the expression patterns of Cx26 and Cx43 have been studied in detail to date. In ocular epithelium and the epidermis, Cx43 and other connexins are expressed (4). In the skin, connexins form heteromeric structures and mutations in Cx26 act as trans-dominant inhibitors of gap junction channels (5), although wild-type Cx43 and Cx26 do not form heteromeric channels (6). Cx26 and Cx30 form heteromeric connexons in the cochlea (7). There may be certain differences in the dominant-negative effects of Cx26 mutations on the function of gap junctions between the skin, the ocular epithelium and the inner ear.

The aspartic acid residue altered by the mutation p.Asp50Asn is located in extracellular loop1 (E1), a domain that seems to be involved in the interaction between connexons and in the control of the voltage gating of the channel.

The majority of KID syndrome cases suffer from profound hearing loss, although several cases with mild hearing loss have been reported (8, 9). In the present case, the patient did not claim any significant hearing inconvenience until her fifties and her hearing impairment was only detected after thorough auditory examination after the diagnosis of KID syndrome had been made.

As far as we know, 37 patients with p.Asp50Asn have been reported in KID syndrome cases or cases with hystrix-like ichthyosis with deafness (HID; MIM#602540), a syndrome which has been shown to be identical to KID syndrome (8–12). Only 3 patients with KID syndrome with the p.Asp50Asn mutation have shown mild to moderate hearing loss (10, 11). However, even in those 3 cases, their hearing loss was apparent from early childhood. No tandem polymorphism was described in those cases except for one case which had a polymorphism –31C>T in the non-coding region of *GJB2* (12).

The present patient was homozygous for one polymorphism, p.Val27Ile, and had another polymorphism, p.Glu114Gly, on the mutant allele. Both variants are known to be common among individuals of Asian populations and can be found in cis-configuration on the same *GJB2* allele (13). The present study confirmed that

the 2 polymorphism are frequently seen in the Japanese population (14). The amino acid altered by the polymorphism p.Val27Ile was located in the transmembrane domain (Fig. 1A) and is highly conserved among the human connexins (Fig. 1B) and among Cx26 between diverse species (Fig. 1C). Thus, the amino acid Val27 may be an important residue and this polymorphism may have a significant effect on the conformational structure and/or function of Cx26 peptide. The other polymorphism p.Glu114Gly is located in the intercellular loop, not in the extracellular loops or transmembrane domains, although the altered amino acid is also conserved among species (Fig. 1C).

In this context, we speculate that the homozygous polymorphism p.Val27Ile in the present case may affect the conformational structure of mutant Cx26 and reduce the dominant-negative effect on the gap junction function in the inner ear.

p.Val27Ile in Cx26 was represented as a common polymorphism (14). However, there is a report of KID syndrome with heterozygous Cx30 (*GJB6*) mutation p.Val37Glu and homozygous Cx26 (*GJB2*) polymorphism p.Val27Ile (15). In that case, Cx26 with p.Val27Ile polymorphism might affect a gap junction function incorporated with p.Val37Glu mutation in Cx30, resulting in congenital bilateral sensorineural hearing loss. The present case with a single mutation and 2 polymorphisms on one *GJB2* allele, showed severe skin and ocular involvement, but mild hearing impairment. The genetic background in the different populations may be associated with unique clinical features of the present case, as previously suggested by Janecke et al. (10).

REFERENCES

- Richard G, White TW, Smith LE, Bailey RA, Compton JG, Paul DL, et al. Functional defects of Cx26 resulting from a heterozygous missense mutation in a family with dominant deaf-mutism and palmoplantar keratoderma. *Hum Genet* 1998; 103: 393–399.
- Kudo T, Ikeda K, Kure S, Matsubara Y, Oshima T, Watanabe K, et al. Novel mutations in the connexin 26 Gene (*GJB2*) responsible for childhood deafness in the Japanese population. *Am J Med Genetics* 2000; 90: 141–145.
- Andres DA, Seabra MC, Brown MS, Armstrong SA, Smeland TE, Cremers FP, et al. cDNA Cloning of component A of Rab geranylgeranyl transferase and demonstration of its role as a Rab escort protein. *Cell* 1993; 73 1091–1099.
- Richard G. Connexin gene pathology. *Clin Exp Dermatol* 2003; 28: 397–409.
- Rouan F, White TW, Brown N, Taylor AM, Lucke TW, Paul DL, et al. Trans-dominant inhibition of connexin-43 by mutant connexin-26: implications for dominant connexin disorders affecting epidermal differentiation. *J Cell Sci* 2001; 114: 2105–2113.
- Thomas T, Telford D, Laird DW. Functional domain mapping and selective trans-dominant effects exhibited by Cx26 disease-causing mutations. *J Biol Chem* 2004; 279: 19157–19168.
- Marziano NK, Casalotti SO, Portelli AE, Becker DL, Forge A. Mutations in the gene for connexin 26 (*GJB2*) that cause hearing loss have a dominant negative effect on connexin 30. *Hum Mol Genet* 2003; 12: 805–812.
- Bygum A, Betz RC, Kragballe K, Steiniche T, Peeters N, Wuyts W, et al. KID Syndrome: report of a Scandinavian patient with connexin-26 gene mutation. *Acta Derm Venereol* 2005; 85: 152–155.
- Bondeson ML, Nyström AM, Gunnarsson U, Vahlquist A. Connexin 26 (*GJB2*) mutations in two Swedish patients with atypical Vohwinkel (mutilating keratoderma plus deafness)

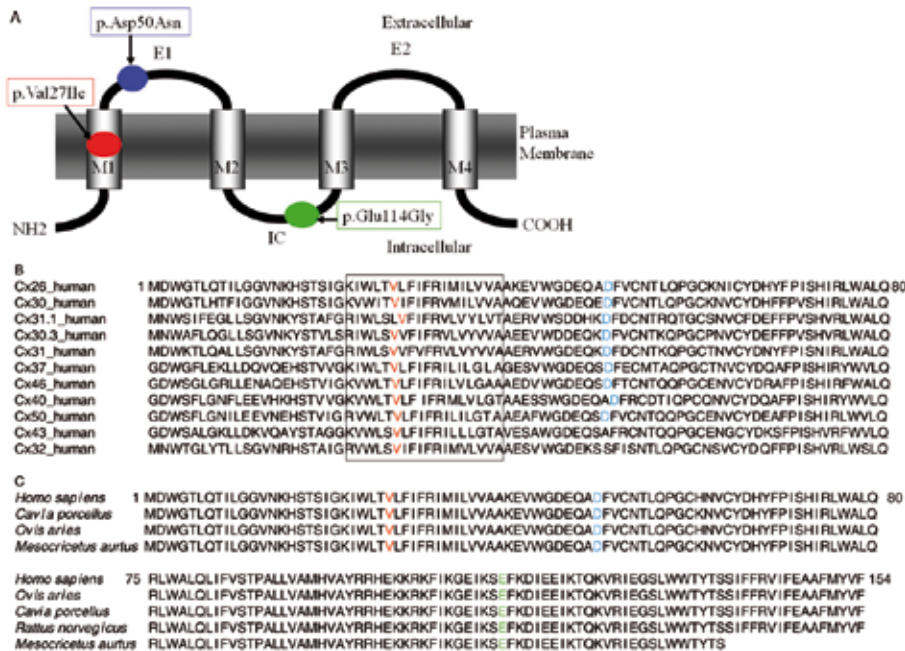


Fig. 1. *GJB2* mutation in the present patient: conserved region analysis of the altered amino acid and molecular structure of Cx26. (A) Scheme of the Cx26 molecular structure and location of the present mutation and polymorphisms. M1–M4 = transmembrane domains 1–4, respectively; E1 and E2 = extracellular domains 1 and 2, respectively; intracellular domain. (B) Comparison of sequences for 11 members of the human connexin family. Residues equivalent to p.Val27 and p.Asp50 in connexins are highlighted in red and blue. The transmembrane domain is boxed. Note the high level of conservation of both p.Val27 and p.Asp50 residues among human connexin family. (C) Comparison of amino acid sequence alignment of the human and other species. Residues equivalent to p.Val27, p.Asp50 and p.Glu114 in connexin-26 are highlighted in red, blue and green. Note, p.Val27, p.Asp50 and p.Glu114 are conserved among diverse species.

- and KID syndrome both extensively treated with acitretin. *Acta Derm Venereol* 2006; 86: 503–508.
10. Janecke AR, Henies HC, Günther B, Gansel G, Smolle J, Messmer EM, et al. GJB2 mutations in keratitis-ichthyosis-deafness syndrome including its fatal form. *Am J Med Genet A* 2005; 133: 128–131.
  11. Mazereeuw-Hautier J, Bitoun E, Chevrant-Breton J, Man SY, Bodemer C, Prins C, et al. Keratitis-ichthyosis-deafness syndrome: disease expression and spectrum of connexin 26 (GJB2) mutations in 14 patients. *Br J Dermatol* 2007; 156: 1015–1019.
  12. Maintz L, Betz RC, Allam JP, Wenzel J, Jaksche A, Friedrichs N, et al. Keratitis-ichthyosis-deafness syndrome in association with follicular occlusion triad. *Eur J Dermatol* 2005; 15: 347–352.
  13. Posukh O, Pallares-Ruiz N, Tadinova V, Osipova L, Claustres M, Roux AF. First molecular screening of deafness in the Altai Republic population. *BMC Med Genet* 2005; 6: 12.
  14. Abe S, Usami S, Shinkawa H, Kelley PM, Kimberling WJ. Prevalent connexin 26 gene (GJB2) mutations in Japanese. *J Med Genet* 2000; 37: 41–43.
  15. Jan AY, Amin S, Ratajczak P, Richard G, Sybert VP. Genetic heterogeneity of KID syndrome: identification of a Cx30 gene (GJB6) mutation in a patient with KID syndrome and congenital atrichia. *J Invest Dermatol* 2004; 122: 1108–1113.