

## Successful Treatment of an Elderly Patient with Refractory Ultraviolet-A-sensitive Atopic Eczema with Mycophenolic Acid

Michael Bär, Jochen Schmitt, Andrea Bauer, Gottfried Wozel and Michael Meurer

Department of Dermatology, Medizinische Fakultät Carl Gustav Carus Dresden, DE-01309 Dresden, Germany.

E-mail: Michael.Baer@uniklinikum-dresden.de

Accepted January 10, 2008.

Sir,

Atopic eczema (AE) is a frequent condition in children and adults and imposes a substantial burden in terms of morbidity and economic impact (1, 2). Most patients can be treated effectively with emollients and topical anti-inflammatory agents, such as corticosteroids and the calcineurin inhibitors pimecrolimus and tacrolimus. However, in many, mostly adult, patients with AE the activity of skin manifestations and associated symptoms necessitates intermittent or permanent systemic treatment (3). A recent systematic review has shown that data from randomized controlled trials (RCT) in severe AE exist only for cyclosporine, azathioprine and IF- $\gamma$  (4, 5). In everyday clinical practice, cyclosporin is frequently contraindicated due to hypertension or renal disease, IF- $\gamma$  is rarely applied because it is not very well tolerated, and azathioprine may not be favoured because of its limited effectiveness and the possibly required dose adaptation owing to genetic polymorphism in thiopurine methyltransferase (5–8). The management of severe AE in older patients with co-morbidities is particularly challenging and advice cannot be inferred from published RCTs or treatment guidelines (3, 8).

Two uncontrolled open studies, including a total of 20 adults and a recently published case series reporting about 14 children, provide some evidence for a favourable benefit-to-risk ratio of a newer immunosuppressive drug, mycophenolate mofetil, in severe AE (4, 9–11).

### CASE REPORT

At first presentation in January 2007, an 82-year-old man had a one-year history of an extremely itchy, light-sensitive, eczematous rash involving his face, trunk and upper extremities. Clinical symptoms were resistant to topical corticosteroids and oral antihistamines. A transient benefit was seen during systemic therapy with prednisolone, but acute exacerbation followed after prednisolone had been tapered off. Personal and family history was positive for AE, but not for respiratory atopy. Owing to arterial hypertension with incipient hypertensive nephropathy the patient was treated with daily doses of ramipril 5 mg, valsartan 80 mg, and hydrochlorothiazide 12.5 mg.

On examination he presented with a widespread infiltrated, erythematous, scaly rash on the light-exposed areas of the face, trunk and extensor parts of the arms. The lesions were partly lichenified and excoriated. Laboratory investigations revealed anaemia (haemoglobin 8.18 mmol/l, normal 8.6–12.1 mmol/l), lymphopaenia (11%, 20–49%), discrete elevation of renal function (creatinine 135  $\mu$ mol/l, <124  $\mu$ mol/l), proteinuria (0.57 g/l after collection of urine for 24 h, <0.12 g/l), and a marked elevation of total IgE 3 543.0 kU/l (<20 kU/l), total specific IgE against inhalative allergens 25.9 kU/l (<0.35 kU/l), total specific IgE against food allergens 9.1 kU/l (<0.35 kU/l), Dermatophages pteronyssinus CAP class 2, timothy CAP class 3, alder CAP class 3, birch CAP class 3. Swabs were taken and *Staphylococcus aureus* colonization was diagnosed.

The initial skin biopsy in January 2007 showed superficial perivascular and interstitial dermatitis consisting of a lymphohistiocytic and eosinophilic infiltration with little spongiosis suggestive for subacute or chronic dermatitis without signs of cutaneous lymphoma. Ultraviolet (UV) light testing revealed a pronounced UVA hypersensitivity with the development of

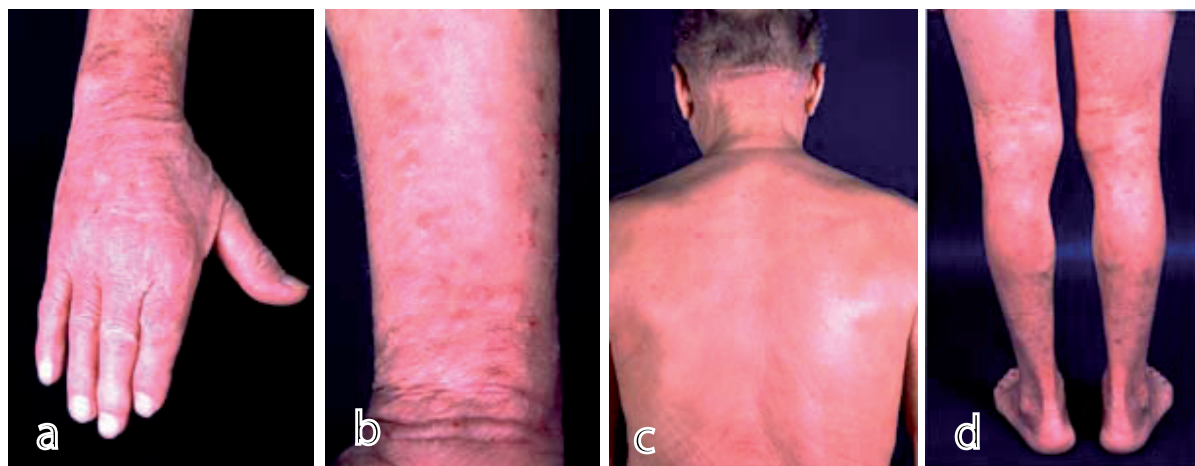


Fig. 1. (a–d) Widespread and infiltrated, in part lichenified and excoriated erythematous scaly rash, particularly on light-exposed areas, shown before systemic treatment with mycophenolic acid (January 2007).

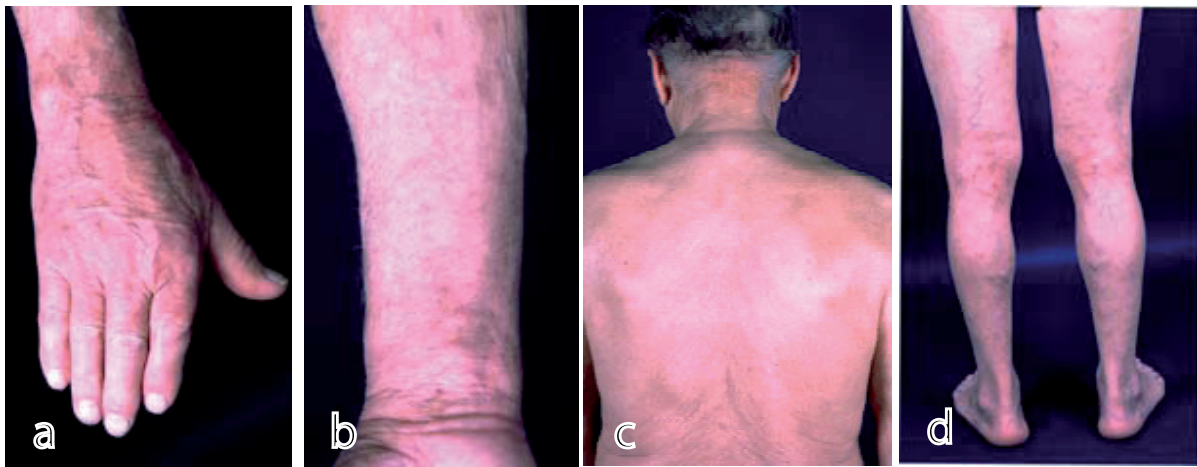


Fig. 2. (a–d) Persistent clinical remission showing only residual sebastosis after 5 months of systemic treatment with mycophenolic acid, here documented after discontinuation of topical corticosteroids for 2 months (July 2007).

an extensive itchy rash in the UVA-irradiated areas frustrating the determination of the corresponding UVA dose. Late-onset UVA-sensitive AE was diagnosed. Due to the refractory course, systemic therapy was necessary. Standard options were contraindicated because of hypertensive nephropathy and anaemia. Thus, the patient was started off-label on mycophenolic acid, at a daily dose of 1440 mg. Owing to staphylococcal superinfection, topical treatment was initially supplemented by an oxychinoline 0.25% ointment. Topical treatment with betamethasone 0.1% was continued until the end of March and the patient was informed about consequent textile and chemical light protection.

After 2 months of treatment, an almost complete resolution of the eczema was seen. Only residual erythema on the chest, discrete hyperpigmentation and epidermal atrophy were affecting about 5% of body surface. Mycophenolic acid treatment was reduced stepwise since April and stopped in June 2007. Laboratory investigations showed no relevant changes. Topical treatment with betamethasone 0.1% was discontinued 10 weeks after initiation of mycophenolic acid. Today, about 8 months after initiation of treatment with mycophenolic acid, the patient is still in complete remission, only showing residual sebastosis without the need for further systemic treatment so far.

## DISCUSSION

This case confirms the effectiveness of mycophenolic acid as the active metabolite of mycophenolate mofetil in an enteric-coated formulation in an elderly Caucasian man with late-onset light-sensitive AE. Although this patient was not the first to be treated successfully with mycophenolic acid, this case shows that this treatment option may be considered in elderly patients, as well as in patients with UVA-sensitive disease. Controlled studies will be necessary to evaluate the subset of patients with severe AE who benefit most from this drug.

## REFERENCES

1. Williams HC. Clinical practice. Atopic dermatitis. *N Engl J Med* 2005; 352: 2314–2324.
2. Kemp AS. Cost of illness of atopic dermatitis in children: a societal perspective. *Pharmacoeconomics* 2003; 21: 105–113.
3. Ellis C, Luger T, Abeck D, Allen R, Graham-Brown RA, De Prost Y, et al. International Consensus Conference on Atopic Dermatitis II (ICCAD II): clinical update and current treatment strategies. *Br J Dermatol* 2003; 148 Suppl 63: 3–10.
4. Schmitt J, Schakel K, Schmitt N, Meurer M. Systemic treatment of severe atopic eczema: a systematic review. *Acta Derm Venereol* 2007; 87: 100–111.
5. Meggitt SJ, Gray JC, Reynolds NJ. Azathioprine dosed by thiopurine methyltransferase activity for moderate-to-severe atopic eczema: a double-blind, randomized controlled trial. *Lancet* 2006; 367: 839–846.
6. Schmitt J, Schmitt NM, Meurer M. Cyclosporin in the treatment of patients with atopic eczema – a systematic review and meta-analysis. *JEADV* 2007; 21: 606–619.
7. Berth-Jones J, Takwale A, Tan E, Barclay G, Agarwal S, Ahmed I, et al. Azathioprine in severe adult atopic dermatitis: a double-blind, placebo-controlled, crossover trial. *Br J Dermatol* 2002; 147: 324–330.
8. Hanifin JM, Cooper KD, Ho VC, Kang S, Krafchik BR, Margolis DJ, et al. Guidelines of care for atopic dermatitis, developed in accordance with the American Academy of Dermatology (AAD)/American Academy of Dermatology Association “Administrative Regulations for Evidence-Based Clinical Practice Guidelines”. *J Am Acad Dermatol* 2004; 50: 391–404.
9. Grundmann-Kollmann M, Podda M, Ochsendorf F, Boehncke WH, Kaufmann R, Zollner TM. Mycophenolate mofetil is effective in the treatment of atopic dermatitis. *Arch Dermatol* 2001; 137: 870–873.
10. Heller M, Shin HT, Orlow SJ, Schaffer JW. Mycophenolate mofetil for severe childhood atopic dermatitis: experience in 14 patients. *Br J Dermatol* 2007; 157: 127–132.
11. Neuber K, Schwartz I, Itschert G, Dieck AT. Treatment of atopic eczema with oral mycophenolate mofetil. *Br J Dermatol* 2000; 143: 385–391.