

## Coexistence of Diffuse Reactive Angioendotheliomatosis and Neutrophilic Dermatitis heralding Primary Antiphospholipid Syndrome

John Kawaoka<sup>1</sup>, Jason McBean<sup>1</sup>, Hongmei Li<sup>2</sup>, Martin C. Mihm Jr<sup>3</sup> and George Kroumpouzou<sup>1\*</sup>

<sup>1</sup>Department of Dermatology, Brown Medical School, Providence, <sup>2</sup>DermPath New England, Boston and <sup>3</sup>Departments of Dermatology and Pathology, Massachusetts General Hospital, Harvard Medical School, Boston, USA. \*9 Hawthorne Place, Suite 6D, Boston, MA 02114, USA. \*E-mail: george.kroumpouzou@GKderm.com

Accepted January 10, 2008.

Sir,

Reactive angioendotheliomatosis (RAE) is a rare entity characterized by a massive proliferation of endothelial cells in patients with coexistent systemic disease in which occlusive or vasculopathic processes occur leading to reactive endothelial cell proliferation, such as infectious, lymphoproliferative, autoimmune and peripheral vascular disease, cryoproteinemia and amyloidosis. RAE (1) has not been associated with primary antiphospholipid syndrome (APS). We report here the first case in which RAE and a neutrophilic dermatitis developed simultaneously and prior to clinical manifestations of primary APS.

### CASE REPORT

A 51-year-old woman presented with a 6-month history of asymptomatic persistent violaceous lesions. There were no constitutional symptoms, her past medical history was unremarkable, and she was not taking any oral medications. Skin examination revealed several well-demarcated, flat-topped or dome-shaped, purple or purpuric papules and plaques over the elbows, thighs and buttocks (Fig. 1). The erythrocyte sedimentation rate was 100 mm/h (normal: <20 mm/h), anticardiolipin antibody (aCL) of IgG isotype was persistently elevated (14–45; normal: <10), partial thromboplastin time was 45 sec (normal: 1–40 sec) and gamma globulin polyclonal was 2.8 (normal: 0.6–1.6). The following laboratory parameters were within normal limits: complete blood cell count, antibody profile for autoimmune disease, cryoglobulin, cryofibrinogen, C and S functional proteins, lupus anticoagulant and dilute Russell viper venom time. Biopsy findings showed a dermal proliferation of closely packed, predominantly capillary-sized vessels lined by bland, but plump, endothelial cells without significant atypia (Fig. 2). Variably dilated vascular spaces surrounded by pericytes were also present. There were no intravascular thrombi to suggest a pre-existing coagulopathy. Stains for endothelial markers (CD31 and factor VIII) were positive. The features were consistent with diffuse RAE.

Two months later the patient developed new erythematous or urticarial-looking asymptomatic plaques on her arms, hands and thighs, and she mentioned that she had had similar lesions in the past. There were no clinical features of Sweet's syndrome. A skin biopsy revealed features of florid interstitial neutrophilic dermatitis indistinguishable from those of rheumatoid neutrophilic dermatitis; there were no histopathological features of leukocytoclastic vasculitis. Interestingly, several lesions showed features of both RAE and neutrophilic dermatitis. Three months later the patient developed a necrotic, non-inflamed plaque on her left leg that resulted in a punched-out ulcer. The lesion was not caused by trauma, and coincided with a positive aCL IgG (25; normal <10) and IgA (18; normal <10) and, for the first time, an antinuclear antibody positivity (1:320). In the following 6 months the patient developed three more ulcers on the left ankle and left medial malleolus. Biopsies of the ulcers showed fibrinous material in numerous vessels and focal intravascular thrombi formation; there

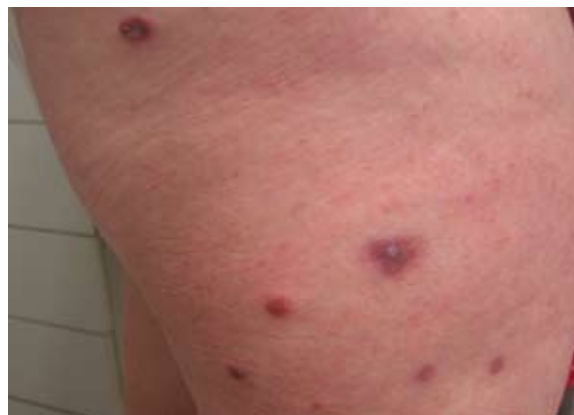

Fig. 1. Flat-topped or dome-shaped violaceous or purpuric papules and plaques distributed over the buttock and thigh.

were no histopathological features of vasculitis. Patient fulfilled two classification criteria for APS<sup>2</sup> (small vessel thrombosis and aCL). The ulcers healed slowly with meticulous wound care and intake of aspirin 321 mg orally daily.

The RAE lesions did not respond to oral steroids, cryotherapy and treatment with alitretinoin 0.1% (Panretin) gel. Some improvement was noticed with intralesional triamcinolone acetonide 40 mg/ml. The RAE lesions were finally treated twice with purpuric doses of long-pulsed pulsed dye laser (595 nm) (Vbeam; Candela Corp., Wayland, MA, USA). The treatments were performed one month apart. After the laser treatments some lesions resolved, while others became soft, flat and grey or tan instead of purple or bright red; changes that satisfied the patient.

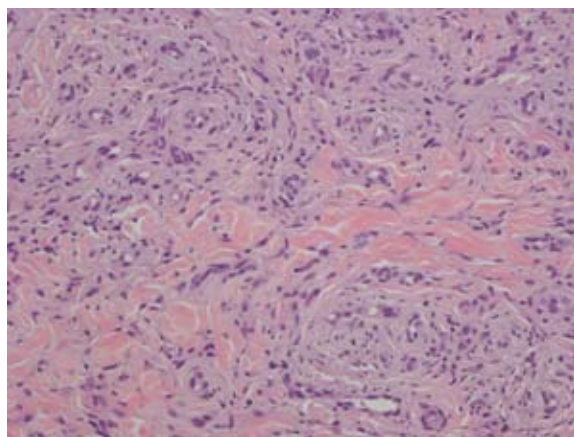


Fig. 2. Biopsy specimen from the lesions shown in Fig. 1 reveals a proliferation of closely packed, predominantly capillary-sized vessels as well as variably dilated vascular spaces lined by bland but plump endothelial cells and surrounded by pericytes; there are no intravascular thrombi to suggest a pre-existing coagulopathy (hematoxylin-eosin stain  $\times 20$ ).

## DISCUSSION

RAE is usually self-limited, affecting mostly the middle-aged, and can be associated with constitutional symptoms. The skin lesions have a propensity to involve the limbs, and include erythematous to violaceous patches, papules or plaques that can ulcerate or blister and may mimic angiosarcoma or Kaposi's sarcoma (1, 3). RAE has been classified into several histopathological types (4), including diffuse dermal, intravascular, tufted angioma-like and glomeruloid types – the case described in this report is a diffuse RAE. No specific treatment is available, since RAE may respond to treatment of the underlying disorder. Antibiotics for occult infections and systemic steroids have been used with variable results.

Some authors have suggested that RAE may be a stage in the revascularization process of the thrombotic vessel (4). Potential etiologic factors include immune complexes, bacterial antigens, cryoproteins, venous stasis and local hypoxia. RAE in our case is secondary to aCL, which fits with the proposed mechanism of vasculopathy. Two RAE cases (3, 5) have been associated with APS in the setting of systemic lupus and showed histopathological evidence of thrombosis in the RAE lesions. Contrary to those two cases, the present case did not satisfy criteria for systemic lupus and showed evidence of thrombosis only in lesions that ulcerated.

A review of the literature shows two case reports (6, 7) of small vessel atypical proliferative vasculopathy associated with thrombus formation in APS. These two cases did not show features of RAE, but approximate to our case in that they indicate that not only thrombosis but also endothelial cell proliferation can play a role in the occlusive pathology of APS. The microvascular occlusion that caused extensive cutaneous necrosis and ulcer formation in the present case of APS most likely resulted from both endothelial cell proliferation and thrombosis. The present case clearly illustrates that reactive vascular processes, such as RAE and neutrophilic dermatosis, can predate APS. These associations mandate a thorough laboratory work-up including aCL in patients presenting with RAE and/or neutrophilic dermatosis and a clinical investigation and increased surveillance for signs of APS.

Coexistence of RAE with a neutrophilic dermatosis has not been reported (8). The neutrophilic dermatosis in our patient has striking similarities to rheumatoid neutrophilic dermatosis, but cannot be classified as such based on the criteria proposed by Ackerman (9) who defined the entity. Both RAE (1, 5) and neutrophilic vascular reactions such as rheumatoid neutrophilic dermatosis (10) are thought to be caused by immune complex formation with subsequent cell adhesion and release of chemotactic cytokines. A recent study (11) showed that even low titers of aCL, such as those seen

in our case, can cause immune complex-related vascular changes. There are two pathogenetic mechanisms associated with the presence of aCL (11): one related to abnormal coagulation, which may account for the thrombosis/ulcer in our patient, and the other to immune complex formation/endothelial cell injury, which, in the present case, may have caused subsequent endothelial cell proliferation (development of RAE) and a neutrophilic vascular reaction. The latter is also supported by the suggestion of Magro & Crowson (12), who proposed that aCL is one of the co-factors involved in neutrophilic vascular processes such as rheumatoid neutrophilic dermatosis. It is also supported by the fact that several lesions in our patient showed histopathological features of both RAE and neutrophilic dermatosis. We believe that the associations among RAE, neutrophilic dermatosis and APS in our patient are caused by aCL through the mechanisms outlined above.

## REFERENCES

1. McMenamin ME, Fletcher C. Reactive angioendotheliomatosis: a study of 15 cases demonstrating a wide clinicopathologic spectrum. *Am J Surg Pathol* 2002; 26: 685–687.
2. Miyakis S, Lockshin MD, Atsumi T, Branch DW, Brey RL, Cervera R, et al. International consensus statement on an update of the classification criteria for definite antiphospholipid syndrome (APS). *J Thromb Haemost* 2006; 4: 295–306.
3. Thai K, Barrett W, Kossard S. Reactive angioendotheliomatosis in the setting of antiphospholipid syndrome. *Australas J Dermatol* 2003; 44: 151–155.
4. Rongioletti F, Rebora A. Cutaneous reactive angiomatoses: patterns and classification of reactive vascular proliferation. *J Am Acad Dermatol* 2003; 49: 887–896.
5. Creamer D, Black MM, Calonje E. Reactive angioendotheliomatosis in association with the antiphospholipid syndrome. *J Am Acad Dermatol* 2000; 42: 903–906.
6. Reyes E, Alarcon-Segovia D. Leg ulcers in the primary antiphospholipid syndrome: report of a case with a peculiar proliferative small vessel vasculopathy. *Clin Exp Rheum* 1991; 9: 63–66.
7. Westerman EM, Miles JM, Backonja MV, Sundstrom WR. Neuropathologic findings in multi-infarct dementia associated with anticardiolipin antibody. *Arth Rheum* 1992; 35: 1038–1041.
8. Defaria D, Kroumpouzou G. Rheumatoid neutrophilic dermatitis as the only presenting sign of seronegative rheumatoid arthritis. *Acta Derm Venereol* 2004; 84: 236–237.
9. Ackerman AB, editor. *Histologic diagnosis of inflammatory skin diseases: a method of pattern analysis*. Philadelphia: Lea & Febiger, 1978: p. 449–451.
10. Yamamoto T, Ohukubo H, Nishioka K. Rheumatoid neutrophilic dermatitis. *Int J Dermatol* 1994; 11: 798–800.
11. Sipek-Dolnicar A, Hojnik M, Bozic B, Vizjak A, Rozman B, Ferluga D. Clinical presentations and vascular histopathology in autopsied patients with systemic lupus erythematosus and anticardiolipin antibodies. *Clin Exp Rheumatol* 2002; 20: 335–342.
12. Magro CM, Crowson AN. The spectrum of cutaneous lesions in rheumatoid arthritis: a clinical and pathological study of 43 patients. *J Cutan Pathol* 2003; 30: 1–10.