

A *BHD* Germline Mutation Identified in an Asian Family with Birt-Hogg-Dubé Syndrome

Noriyuki Misago¹, Keiichiro Joh², Hitomi Yatsuki², Hidenobu Soejima² and Yutaka Narisawa¹

¹Department of Internal Medicine, Division of Dermatology, and ²Department of Biomolecular Sciences, Division of Molecular Biology & Genetics, Faculty of Medicine, Saga University, Nabeshima 5-1-1, Saga JP-849-8501, Japan. E-mail: misago@post.saga-med.ac.jp

Accepted December 21, 2007.

Sir,

Birt-Hogg-Dubé syndrome (BHD, OMIM 135150) is an autosomal dominant genodermatosis characterized clinically by multiple occurrence of fibrofolliculoma or trichodiscoma, and associated with an increased risk of developing renal neoplasms and lung cysts/spontaneous pneumothorax (1). The responsible gene has been mapped on chromosome 17p11.2 encoding folliculin, a cytoplasmic protein with unknown functions (2). Various different *BHD* germline mutations have been reported; most of which were identified in Caucasian families (2–6). However, there have been recent reports of such *BHD* mutations in Asian families, although the number of such reports is still small (7–9). We report here an Asian family with BHD with a *BHD* germline mutation, demonstrating the importance of *BHD* gene analysis.

CASE REPORT

The proband, a 67-year-old Japanese woman, presented with a 10-year history of multiple papules on her face and neck. A clinical examination revealed numerous, smooth, dome-shaped, white to skin-coloured papules, measuring 2–4-mm in diameter on her face and neck (Fig. 1A). The medical histories of her family members (Fig. 1B) and of the patient herself did not reveal any incidences of renal and other visceral neoplasms or of pneumothorax, and she was also not aware of other family members who had similar papules on the face and neck. A subsequent, careful examination of her 2 daughters (aged 38 and 35 years, respectively), however, revealed several, scattered, white to skin-coloured, small papules on the face and neck in her oldest daughter and only a few skin-coloured, small papules on the neck in her second daughter. Neither daughter had noticed the papular lesions. No other family members could be examined. Biopsy specimens of 8, 2 and 1 papule were removed from the proband, her oldest daughter, and her second daughter, respectively. Histopathological examination revealed the 8 papules from the proband to be 3 fibrofolliculomas (Fig. 1C) and 5 trichodiscomas. The histopathological features of both papules from the oldest daughter and one papule from the second daughter showed a superficial, dilated or cystic infundibulum with a small amount of perifollicular connective tissue and the sebaceous lobules below the infundibulum despite examination of many serial sections; these features were not sufficient to diagnosis fibrofolliculoma or trichodiscoma. Based on these clinical and histopathological findings of the papules, the proband was diagnosed with BHD, while her daughters were suspected to have BHD. Renal ultrasound as well as chest and abdominal computed tomography (CT) scans for the proband and her daughters demonstrated no renal neoplasms, but revealed a lung cyst on the left lung in the oldest daughter and multiple bilateral lung cysts in the second daughter (but no lung cysts in the proband). Colonoscopy for the proband revealed a single adenomatous polyp.

A DNA sequence analysis of the *BHD* gene was performed for the proband and her 2 daughters after obtaining informed consent.

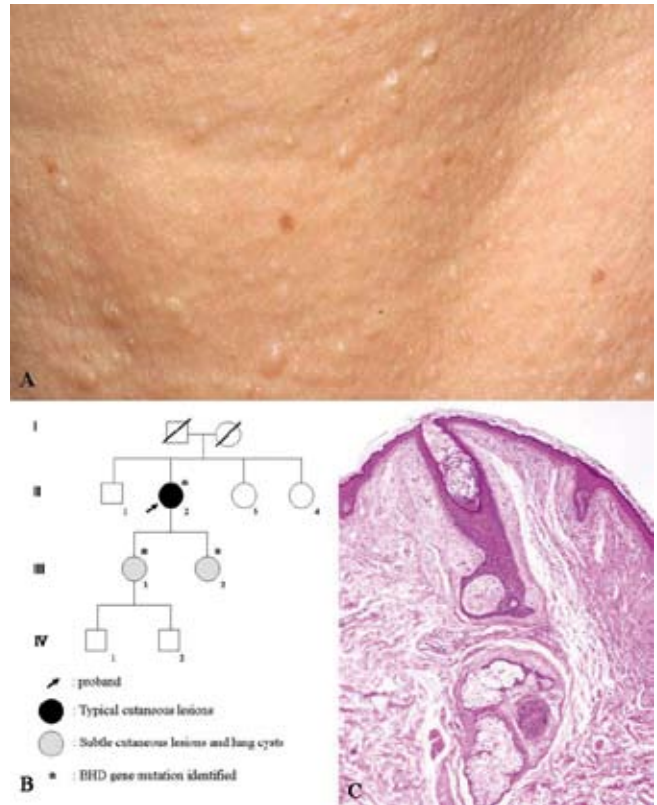


Fig. 1. (A) Multiple, smooth, dome-shaped, white to skin-coloured papules, on the face. (B) The family pedigree. (C) Histopathology of one of the papules in the proband, showing the features of fibrofolliculoma.

Her brother, 2 sisters, and 2 grandsons were not available for testing. DNA was extracted from peripheral blood leukocytes, and subjected to mutation screening. All the exons of the *BHD* gene were amplified by PCR using pairs of oligonucleotide primers synthesized according to a previous report (2). The sequencing analyses of the PCR products revealed a deletion of guanine/adenine/thymine/guanine in exon 13 (c.1988delGATG) in the proband and both her daughters (Figs 1 and 2). This deletion causes the formation of a stop codon, TGA at the deletion site in exon 13. No further analyses were performed to determine whether this mutation results in nonsense-mediated mRNA decay or the production of a truncated protein. This deletion mutation was found in one allele, while another allele had the wild-type sequence in all the individuals. No mutation analysis has yet been performed on the papules of the patients.

DISCUSSION

Various types of germline *BHD* mutations in Caucasian patients have been reported, although a mutational hotspot, a C insertion/deletion in exon 11, is frequently

(40–50%) observed in BHD-affected families (2–4). The recent reports of mutations of the *BHD* gene in Japanese patients demonstrated either a hot spot mutation of a C insertion in exon 11 or novel mutations in exons 6, 12, 13 and in intron 5 (7–9). These recent reports showed that the hot spot mutation in exon 11, as well as genetic heterogeneity, in *BHD* gene mutations tends to be observed worldwide despite differing ethnic backgrounds. The mutation (c.1988delGATG) in exon 13 described herein corresponds with a recently reported, novel *BHD* gene mutation in a Japanese family (9). It is unclear whether the presented proband is a BHD sporadic case, because neither a genetic analysis nor a clinical examination was conducted for her deceased parents and her siblings (one brother and 2 sisters).

The clinical phenotypic features of BHD vary among family members; some individuals show cutaneous lesions associated with renal neoplasms and/or lung cysts/pneumothorax, and others harbour only one of the 3 types of lesions (cutaneous, renal and lung lesions) (1, 9). A recent investigation, however, revealed no correlation between the clinical phenotypic features of BHD and location of mutations (4). Significantly fewer renal neoplasms are observed, however, in patients with the C-deletion than those with the C-insertion mutations, in patients with a mutation in the exon 11 hot spot (4). The reported Japanese family of BHD with a mutation in exon 13 clinically showed only lung cysts without cutaneous and renal lesions (9). However, the Japanese family presented herein, with the same type of mutation in exon 13, has shown either typical cutaneous lesions only or subtle cutaneous lesions in association with lung cysts to date.

Cutaneous lesions generally appear in the third and fourth decades in patients with BHD (10), and spontaneous pneumothorax may occur in younger patients (11). The renal neoplasms typically develop from the

fifth decade of life onward (12). However, the renal neoplasms may occur as early as 20 years of age (3, 11). The proband's 2 daughters with subtle cutaneous lesions (aged 38 and 35 years) as well as the proband (aged 67 years) with typical cutaneous lesions will require follow-up especially to check the future development of renal neoplasms. The possibility of the development of spontaneous pneumothorax should also be carefully kept in mind regarding the 2 daughters who were shown to have lung cysts.

It is notable that the 2 proband's daughters with subtle cutaneous lesions proved to have a mutation in *BHD* gene as well as lung cysts. It was easy to overlook the cutaneous lesions, i.e., only a few or several scattered papules on the face and/or neck, and they had not noticed the lesions at all. Similarly, a more recent report described that none or less than 10 cutaneous lesions were observed in 2 mutation carriers at the age of 67 and 29 years, respectively (6). The present study further demonstrated that these inconspicuous cutaneous lesions were also histopathologically subtle and insufficient for the diagnosis of fibrofolliculoma or trichodiscoma. These subtle clinicopathological features of the cutaneous lesions are considered to be caused by the incipient stage of fibrofolliculoma or trichodiscoma. It has been suggested, however, that there are individuals with *BHD* gene mutations in their 30s or 40s, and sometimes in their 50s or 60s, who have no clinical evidence of BHD syndrome (3). These findings have been explained by the late age onset of BHD or by the possibility that BHD has reduced penetrance in some people (3).

REFERENCES

1. Toro JR, Glenn G, Duray P, Darling T, Weirich G, Zbar B, et al. Birt-Hogg-Dube syndrome: a novel marker of kidney neoplasia. *Arch Dermatol* 1999; 135: 1195–1202.
2. Nickerson ML, Warren MB, Toro JR, Matrosova V, Glenn G, Turner ML, et al. Mutations in a novel gene lead to kidney tumors, lung wall defects, and benign tumors of the hair follicle in patients with the Birt-Hogg-Dube syndrome. *Cancer Cell* 2002; 2: 157–164.
3. Khoo SK, Giraud S, Kahnoski K, Chen J, Motorna O, Nikolov R, et al. Clinical and genetic studies of Birt-Hogg-Dube syndrome. *J Med Genet* 2002; 39: 906–912.
4. Schmidt LS, Nickerson ML, Warren MB, Glenn GM, Toro JR, Merino MJ, et al. Germline BHD-mutation spectrum and phenotype analysis of a large cohort of families with Birt-Hogg-Dube syndrome. *Am J Hum Genet* 2005; 76: 1023–1033.
5. van Steensel MA, Verstraeten VL, Frank J, Kelleners-Smeets NW, Poblete-Gutierrez P, Marcus-Soekarman D, et al. Novel mutations in the BHD gene and absence of loss of heterozygosity in fibrofolliculomas of Birt-Hogg-Dube patients. *J Invest Dermatol* 2007; 127: 588–593.
6. Leter EM, Koopmans AK, Gille JJ, van Os TA, Vitzto GG, David EF, et al. Birt-Hogg-Dubé syndrome: clinical and genetic studies of 20 families. *J Invest Dermatol* 2008; 128: 45–49.
7. Kawasaki H, Sawamura D, Nakazawa H, Hattori N, Goto

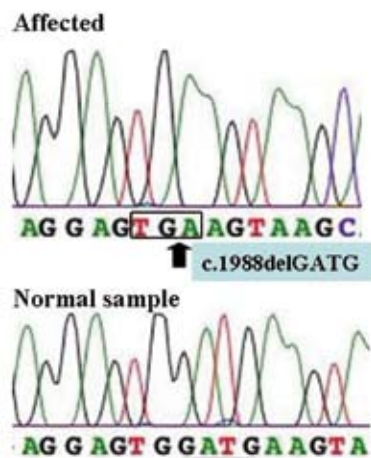


Fig. 2. The sequences of the mutated and wild-type *BHD* gene alleles. The proband and her 2 daughters showed a deletion of GATG in exon 13 (c.1988delGATG). The deleted sequence is underlined in the wild-type sequence. The created stop codon, TGA, is boxed in the mutated sequence.

- M, Sato-Matsumura KC, et al. Detection of 1733insC mutations in an Asian family with Birt-Hogg-Dube syndrome. *Br J Dermatol* 2005; 152: 142–145.
8. Murakami T, Sano F, Huang Y, Komiya A, Baba M, Osada Y, et al. Identification and characterization of Birt-Hogg-Dube associated renal carcinoma. *J Pathol* 2007; 211: 524–531.
 9. Gunji Y, Akiyoshi T, Sato T, Kurihara M, Tominaga S, Takahashi K, et al. Mutations of the Birt Hogg Dube gene in patients with multiple lung cysts and recurrent pneumothorax. *J Med Genet* 2007; 44: 588–593.
 10. Welsch MJ, Kronic A, Medenica MM. Birt-Hogg-Dube Syndrome: *Int J Dermatol* 2005; 44: 668–673.
 11. Zbar B, Alvord WG, Glenn G, Turner M, Pavlovich CP, Schmidt L, et al. Risk of renal and colonic neoplasms and spontaneous pneumothorax in the Birt-Hogg-Dube syndrome. *Cancer Epidemiol Biomarkers Prev* 2002; 11: 393–400.
 12. Pavlovich CP, Grubb RL 3rd, Hurley K, Glenn GM, Toro J, Schmidt LS, et al. Evaluation and management of renal tumors in the Birt-Hogg-Dube syndrome. *J Urol* 2005; 173: 1482–1486.