

## Eosinophilic Fasciitis and Combined UVA1 – Retinoid – Corticosteroid Treatment: Two Case Reports

Hans O. Weber, Martin Schaller, Gisela Metzler, Martin Röcken and Mark Berneburg\*

Department of Dermatology, Eberhard Karls University, Liebermeisterstr. 25, DE-72076 Tübingen, Germany.

\*E-mail: mark.berneburg@med.uni-tuebingen.de

Accepted November 12, 2007.

Sir,

Eosinophilic fasciitis (EF) is a rare disorder of unknown aetiology, first described by Shulman in 1974 (1). Typical symptoms include sclerosis of the skin and painful swelling of the joints at the distal extremities, often leading to complete joint immobility. Skin changes occur in 3 different phases: (i) oedematous diffuse phase; (ii) distinct peau d'orange appearance; and (iii) skin sclerosis. The symptoms typically develop rapidly within weeks. Characteristic, but not mandatory, symptoms include peripheral blood eosinophilia (63% of cases) and hypergammaglobulinaemia (34%) (2). The histology is characterized by an inflammatory infiltrate consisting of lymphocytes, plasma cells and eosinophils in the subcutaneous fat with broadened interlobular septae reaching the fascia. Due to major histological similarities with deep morphea (increase of collagen tissue in the panniculus with thickened interlobular septa and inflammatory infiltration), EF can be seen as an acute variant of morphea. Major complications include arthritis, myositis and carpal tunnel syndrome (2). There are several reports on the association between EF and certain haematological disorders, such as aplastic anaemia, thrombocytopenic purpura and lymphoma. There is no association between EF and particular HLA types (2).

The gold standard of therapy is treatment with high-dose corticosteroids, which has been reported to be effective in up to 70% of cases (2). Other treatments include D-penicillamine, chloroquine, cimetidine, methotrexate, cyclosporin A, infliximab and extracorporeal photopheresis. There is a need for a therapy that can reduce the steroid dose and treatment time.

### CASE REPORTS

#### Case 1

A male patient (age 66) presented with oedematous skin sclerosis on his forearms, lower legs and thighs. He suffered from joint swelling and almost complete joint immobility of both ankles and wrists.

There was no history of Raynaud's syndrome, dysphagia, or dyspnoea. Chest X-ray and abdominal ultrasound were normal. There were no antinuclear, c-ANCA and p-ANCA antibodies. This patient was seropositive for *Borrelia burgdorferi* antibodies (positive IgG and IgM antibodies).

Blood tests revealed a peripheral blood eosinophilia (30.0%, range: 0.0–4.0%), leukocytosis (12270/ $\mu$ l; range: 4000–10000/ $\mu$ l) and hypergammaglobulinaemia (20.6%; range: 9.5–18.0%).

Deep skin biopsies demonstrated an inflammatory infiltrate consisting of lymphocytes and eosinophils in the corium and the

septae of the subcutaneous tissue. In addition, interlobular septae were oedematously broadened. Polymerase chain reaction (PCR) analysis of *B. burgdorferi* antigen was negative. Magnetic resonance imaging of the patient revealed a generalized thickening of fascial tissue and signs of myositis.

Typical skin sclerosis, histology and blood eosinophilia together with the absence of visceral symptoms led to a diagnosis of EF. The time between onset of symptoms and diagnosis was about 9 months.

In order to minimize steroid doses the patient was treated with a combination therapy of UVA1 phototherapy (60 J/cm<sup>2</sup> 3–5 times a week), isotretinoin (20 mg/day) and prednisone (75 mg/day). This was flanked by continuous compression and physical therapy. Due to the positive serology for *B. burgdorferi* antibodies, the patient also received ceftriaxone (2 g/day over 2 weeks) although due to negative PCR a *Borrelia* infection as a cause for the EF appears unlikely. Within 3 weeks there was marked improvement of the oedematous sclerosis and joint mobility. Over the course of the next weeks, the prednisone dose could be reduced to 7.5 mg/day. The sclerosis on the legs responded well to the treatment, with symptoms almost completely cleared, while sclerosis on the arms responded only partially.

#### Case 2

A male patient (age 39) presented with oedematous skin sclerosis on his forearms and lower legs, and multiple, confluent vesicles and erosive skin lesions on both lower legs (Fig. 1a). He suffered from joint swelling and almost complete joint immobility of both ankles.

There was no history of Raynaud's syndrome, dysphagia, or dyspnoea. Chest X-ray and abdominal ultrasound were normal. Serology was negative for *B. burgdorferi* antibody titres and for antinuclear, c-ANCA and p-ANCA antibodies.

Blood tests revealed a peripheral blood eosinophilia (20.6%) and hypergammaglobulinaemia (21.1%).

A deep skin biopsy showed a diffuse dermal inflammatory infiltrate consisting of lymphocytes and eosinophils. Collagen bundles were thickened and compact. Adnexal structures were reduced. The interlobular septae of subcutaneous tissue were broadened. Septae and fascial tissue were also infiltrated by lymphocytes and eosinophils (Fig. 2). PCR analysis for *B. burgdorferi* antigen was negative.

The MRI of the patient revealed pretibial oedema on both lower legs. Typical skin sclerosis, histology and blood eosinophilia, together with the absence of visceral symptoms, led to the diagnosis of EF. The presence of vesicles and erosive lesions within the skin sclerosis on both lower legs are unusual in EF. However, skin sclerosis and laboratory findings supported the diagnosis EF. Time between onset of symptoms and diagnosis was about 10 months. Similar to patient 1, patient 2 was treated by a combination therapy of UVA1 phototherapy (60 J/cm<sup>2</sup> 3–5 times a week), isotretinoin (20 mg/day) and prednisone (60 mg/day). This was flanked by continuous compression and physical therapy. Within 2 weeks (UVA1 cumulative dose 430 J/cm<sup>2</sup>), a favourable response of oedematous dermal scler-

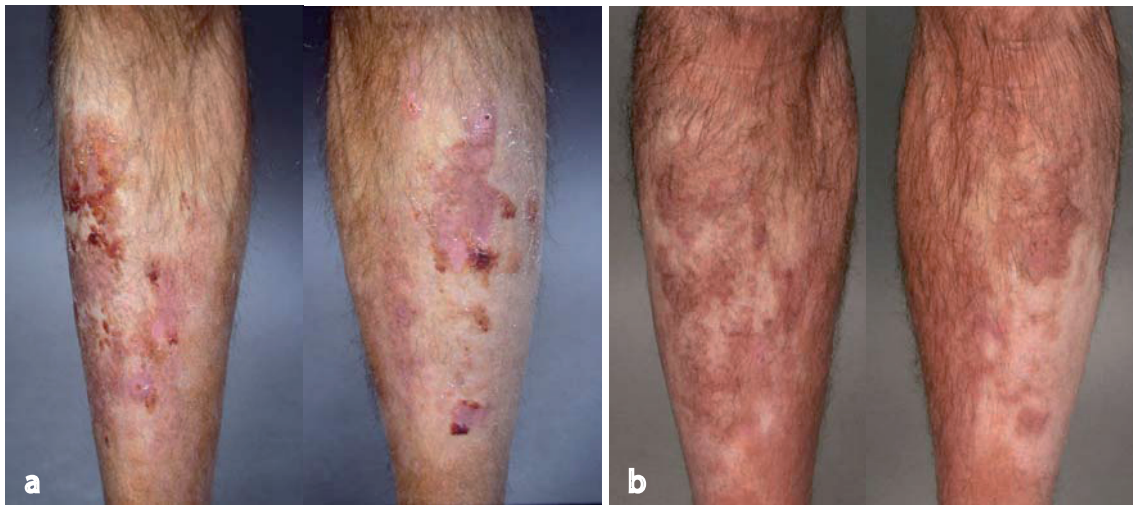


Fig. 1. Case 2. (a) Oedematous skin sclerosis, multiple confluent vesicles and erosive lesions on skin of the lower legs. (b) Six months after combination therapy with UVA1 phototherapy, isotretinoin and low-dose prednisone. Complete remission of erosive skin lesions and almost complete softening of the oedematous sclerosis.

rosis was attained. Joint mobility was improved and peripheral blood eosinophilia normalized. Over the course of the following

weeks, the prednisone dose could be reduced to a maintenance dose of 10 mg/day. After 2 months of therapy (UVA1 cumulative dose 1390 J/cm<sup>2</sup>), erosive skin lesions disappeared. After 8 months of therapy (UVA1 dose 3940 J/cm<sup>2</sup>), almost complete softening of oedematous sclerosis and complete restoration of joint mobility was attained (Fig. 1b).

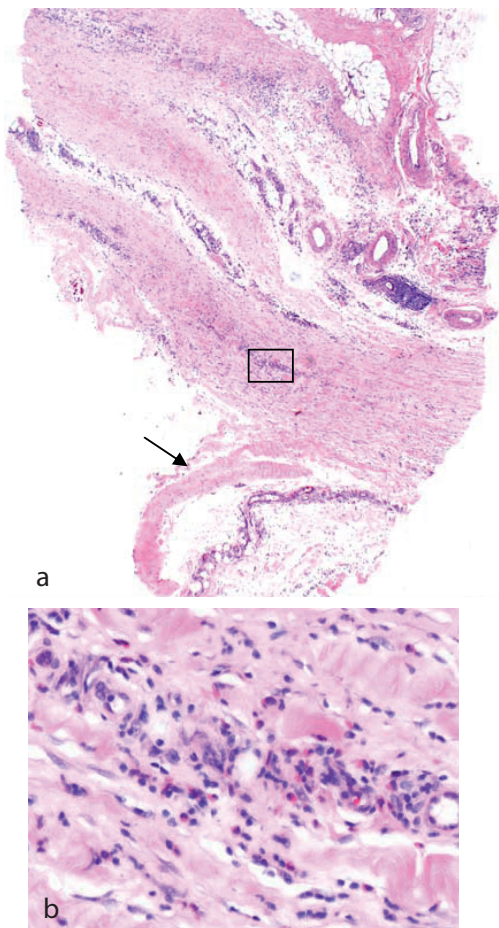


Fig. 2. Deep skin biopsy. (a) Broadened interlobular septae of subcutaneous tissue and replacement of subcutaneous fat by collagen tissue. Diffuse infiltration of eosinophils and lymphocytes reaching the fascia (arrow). (b) Detail: eosinophils and lymphocytes.

## DISCUSSION

Phototherapy (UVA1 and bath-PUVA) has been shown to be an effective treatment for sclerotic skin conditions (3–7). Etretnate therapy has been shown to be an effective treatment for sclerodermatous chronic graft-versus-host disease (8). Possible mechanisms are the inhibition of fibroblast growth and decreased collagen production in dermal fibroblasts (8).

Since UVA1-phototherapy also induces matrix metalloproteinase-1 (9, 10), we treated 2 patients with EF with a combination of UVA1 phototherapy, isotretinoin and corticosteroids. The aim was to keep the necessary steroid dose low. This regimen led to a good clinical response within weeks. After 6–8 months, patient 1 showed good clinical improvement, especially at both lower legs and patient 2 with a more severe form of EF recovered almost completely from EF. This allowed the prednisone dose to be reduced from 60 mg/day to 10 mg/day within weeks.

The supposed effects of isotretinoin on fibroblast function (inhibition of fibroblast growth and decreased collagen production in dermal fibroblasts), the probable effects of UVA1 phototherapy on MMP1, and of prednisone as an anti-inflammatory agent make this combination treatment an attractive consideration in EF. We chose isotretinoin as opposed to etretinate or acitretin due to tolerability reasons. However, our results should be confirmed in larger studies.

*The authors declare no conflicts of interest.*

## REFERENCES

- 1 Shulman LE. Diffuse fasciitis with hypergammaglobulinaemia and eosinophilia: a new syndrome? *J Rheumatol* 1974; 1: 46 (abstract).
- 2 Lakhanpal S, Ginsburg WW, Michet CJ, Doyle JA, Moore SB. Eosinophilic fasciitis: clinical spectrum and therapeutic response in 52 cases. *Semin Arthritis Rheum* 1988; 17: 221–231.
- 3 Kersch M, Volkenandt M, Meurer M, Lehmann P, Plewig G, Rocken M. Treatment of localised scleroderma with PUVA bath photochemotherapy. *Lancet* 1994; 343: 1233.
- 4 Schiener R, Behrens-Williams SC, Gottlober P, Pillekamp H, Peter RU, Kersch M. Eosinophilic fasciitis treated with psoralen-ultraviolet A bath photochemotherapy. *Br J Dermatol* 2000; 142: 804–807.
- 5 Stege H, Berneburg M, Humke S, Klammer M, Grewe M, Grether-Beck S, et al. High-dose UVA1 radiation therapy for localized scleroderma. *J Am Acad Dermatol* 1997; 36: 938–944.
- 6 Kersch M, Dirschka T, Volkenandt M. Treatment of localised scleroderma by UVA1 phototherapy. *Lancet* 1995; 346: 1166.
- 7 Breuckmann F, Gambichler T, Altmeyer P, Kreuter A. UVA/UVA1 phototherapy and PUVA photochemotherapy in connective tissue diseases and related disorders: a research based review. *BMC Dermatol* 2004; 4: 11.
- 8 Marcellus DC, Altomonte VL, Farmer ER, Horn TD, Freemer CS, Grant J, Vogelsang GB. Etretinate therapy for refractory sclerodermatous chronic graft-versus-host disease. *Blood* 1999; 93: 66–70.
- 9 Gruss C, Reed JA, Altmeyer P, McNutt NS, Kersch M. Induction of interstitial collagenase (MMP-1) by UVA-1 phototherapy in morphea fibroblasts. *Lancet* 1997; 350: 1295–1296.
- 10 Yin L, Yamauchi R, Tsuji T, Krutmann J, Morita A. The expression of matrix metalloproteinase-1 mRNA induced by ultraviolet A1 (340–400 nm) is phototherapy relevant to the glutathione (GSH) content in skin fibroblasts of systemic sclerosis. *J Dermatol* 2003; 30: 173–180.