

## REVIEW ARTICLE

# Congenital Ichthyosis: An Overview of Current and Emerging Therapies\*

Anders VAHLQUIST, Agneta GÅNEMO and Marie VIRTANEN

Department of Medical Sciences, Section of Dermatology, Uppsala University, Uppsala, Sweden

**Congenital ichthyosis is a collective name for a group of monogenetic disorders of cornification, sometimes associated with systemic symptoms. There may be an abnormal quality or quantity of scale produced, abnormal thickness of stratum corneum or abnormal keratinocyte kinetics, often associated with skin inflammation. Pruritus, skin fragility, ectropion and anhidrosis are sometimes associated with the rare types of ichthyosis.**

Three important mechanisms are involved in the action of topical agents used in the treatment of ichthyosis: hydration, lubrication and keratolysis. The latter effect can also be achieved with systemic retinoids. For ichthyosis with an increased tendency towards skin infections, antimicrobials are another group of widely used agents.

Considering that patients with ichthyosis are potential mega-users of topical therapy, with an estimated lifetime consumption of approximately one tonne cream per capita, surprisingly few controlled trials of the various treatments have been performed. Moreover, nearly all therapeutic principles were established long before the recent increase in knowledge about the aetiology and pathophysiology of ichthyosis. This calls for new ideas and intensified efforts to develop future ichthyosis therapies. **Key words:** *ichthyosis; genodermatosis; keratolytic agents; retinoids; collodion baby; gene therapy.*

(Accepted October 30, 2007.)

Acta Derm Venereol 2008; 88: 4–14.

Anders Vahlquist, Department of Dermatology, Uppsala University Hospital, SE-751 85 Uppsala, Sweden. E-mail: anders.vahlquist@medsci.uu.se

The term “ichthyosis” encompasses a wide range of keratinizing disorders with different aetiologies, but with the common feature of more or less generalized epidermal hyperkeratosis and a dry, scaly skin. Depending on the type of ichthyosis and the variable influences of individual and environmental factors, the severity of the skin symptoms may range from mild xerosis and scaling on

the extremities, appearing mainly in the winter months (as in ichthyosis vulgaris), to massive hyperkeratosis and scaling all over the body (as in lamellar ichthyosis). The more severe forms are frequently associated with erythema, palmo-plantar keratoderma, ectropion, hypohidrosis with heat intolerance, and alopecia. Some patients also experience skin erosions and blisters, as in bullous ichthyosis, or epidermolytic hyperkeratosis.

A separate group of patients also have non-cutaneous symptoms due to the same genetic defect that is causing the skin problems. Indeed, the medical problems in such syndromic ichthyoses may be dominated by symptoms from the central nervous system, immune system, skeleton, or other non-cutaneous tissues.

Over the last decade, many new aetiologies have been elucidated, making it easier to identify correctly various subtypes of ichthyosis and to provide proper genetic counselling to the patients and/or their parents. However, therapy of ichthyosis remains mainly symptomatic and is empirically based on the use of topical emollients, various keratolytic agents and, in more severe cases, oral retinoids (vitamin A analogues). It is the purpose of this review to discuss the current therapy of ichthyosis and to highlight the need for new and more specific treatments. First, however, we give a short description of various subtypes and causes of ichthyosis.

## CLASSIFICATION OF THE ICHTHYOSSES

### *Common ichthyosis*

The two most common forms of ichthyosis, autosomal (pseudo-)dominant ichthyosis vulgaris (IVU) and X-linked recessive ichthyosis (XRI), occur at frequencies of about 1/300 and 1/2500 (in males), respectively (1) (Table I). Indeed, the genetic traits for IVU and XRI are so common that the two diseases occasionally co-exist in one and the same family, which may cause confusion as to the inheritance pattern. Although the incidence of IVU and XRI is probably similar around the world, climate differences in particular will affect the severity of the disease. In both types of common ichthyosis scaling is usually most apparent on the extensor surfaces of the extremities, but it may also appear on the trunk, especially in XRI (Fig. 1a–b). Xerosis of the skin is a prominent feature in most patients, but there is no

\*Since the Editor-in-Chief is a co-author of this paper he has not had responsibility for the evaluation of this article and it has been handled fully by the Co-Editor, who made the decision for acceptance.

Table I. Common vs. rare forms of non-syndromic ichthyosis

	Ichthyosis vulgaris	X-linked ichthyosis	Lamellar ichthyosis (or CIE/CIFS)	Bullous ichthyosis (or EHK)
Appr. incidence	1/300	1/2500 (in boys)	1/100,000	1/300,000
Inheritance	AD/AR	XR	AR	AD
First appearance	Early childhood	Infancy (at birth)	At birth	At birth
Affected gene(s)	<i>FLG</i>	<i>STS</i>	<i>TGMI</i> , <i>Ichthyin</i> , <i>ALOXE3/12B</i> , <i>FLJ39501</i> , <i>ABCA12</i> , etc.	<i>KRT</i> 1, 2, 10
Pathomechanism	Retention hyperkeratosis		Hyperproliferative hyperkeratosis	
Typical symptoms	Dry, scaly skin mostly on the extremities; better in summer	Brown scales also on the trunk	Collodion baby; dry, scaly skin; ectropion; hypohidrosis, erythema	Intense blistering at birth, verrucous hyperkeratosis and erythema

AD: autosomal dominant; XR: X-linked recessive; AR: autosomal recessive; CIE: congenital ichthyosiform erythroderma; CIFS: congenital ichthyosis with fine/focal scaling; EHK: epidermolytic hyperkeratosis; *FLG*: filaggrin gene; *STS*: steroid sulphatase gene; *TGMI*: transglutaminase 1 gene; *KRT*: keratin gene; *ALOX*: lipoxygenase gene(s); *ABCA*: ATP-binding cassette A gene.

skin inflammation unless ichthyosis is complicated by microbial infection or atopic eczema (a common finding, especially in IVU).

XRI usually starts earlier in life and is more severe than IVU (1). On skin histology, stratum granulosum appears normal in XRI, but is thin or completely absent in IVU (2). Furthermore, monitoring of surface pH shows lower values in XRI compared with IVU (3). These discrepancies adequately reflect the different pathomechanisms in XRI and IVU (Table I). In the former disease deficient steroid sulphatase activity causes acidic cholesterol sulphate to accumulate in the horny layer, which renders corneocytes more cohesive than normal (4, 5). In IVU, on the other hand, a deficiency of filaggrin due to homozygous or heterozygous mutations in the profilaggrin (*FLG*) gene (6) prevents the formation of keratohyaline granules, the acidic breakdown products of which are important both for the humidification and shedding of corneocytes and for maintaining a normal skin pH of about 4–5 (3, 7, 8). In both cases a normoproliferative retention hyperkeratosis will ensue with slightly impaired barrier function (4, 9).

A diagnosis of IVU is supported by a skin histology showing attenuation or absence of stratum granulosum, whereas XRI shows no distinguishing features other than a thick horny layer. A diagnosis of XRI can, however, be ascertained by performing a simple polymerase chain reaction (PCR) analysis, which often shows a complete deletion of the *STS* gene (encoding for steroid sulphatase) that is located at the terminus of the X chromosome (10).

#### Rare types of ichthyosis

Lamellar ichthyosis (LI) and the closely related variants non-bullous ichthyosiform congenital erythroderma (CIE) and congenital ichthyosis with fine/focal scaling (CIFS), also known as “non-LI/non-CIE ichthyosis” (8, 11), occur at much lower frequencies than IVU and XRI (incidence approximately 1/100 000) and are invariably present at birth (Fig. 1c–e). Collectively

known as autosomal recessive congenital ichthyosis (ARCI), these rare diseases may be awkward to classify because different genotypes produce overlapping clinical pictures and, conversely, identical mutations in two individuals can produce different phenotypes (8, 11–13). Pathogenetically they have in common a severely disturbed barrier function due either to abnormal corneocytes or to a defective deposition of stratum corneum lipids (Table I). The leading causes of LI are truncating or missense mutations in the gene encoding keratinocyte transglutaminase type 1 (*TGMI*), which inactivate the enzyme and result in a deficient cross-linking of cornified cell envelope proteins (14, 15). The second most common cause of ARCI, at least in Europe, appears to be *ichthyin* mutations (16). *Ichthyin* is a transmembrane protein presumably involved in the lipid transport and function of lamellar granules; its deficiency leads to an accumulation of membrane-like structures in granular cells and corneocytes recognized on electron microscopy as EM type III (17). In addition, several other “ARCI genes” encoding various transport proteins and enzymes essential for the production of specialized lipid components in the horny layer have been identified, including *ALOX12B*, *ALOXE3* and *CGI-58* (18, 19). Furthermore, truncating mutations in *ABCA12* gene, which encodes for an ATP-binding cassette transporter protein, explain the most severe phenotype of ARCI, harlequin ichthyosis, in which neonates are covered with plate-like scales and massive hyperkeratosis (20, 21). Harlequin babies who survive usually develop a severe CIE phenotype, whereas neonates with collodion presentation can develop into a wide spectrum of ichthyoses, ranging from a mild, self-healing phenotype with little residual skin problems (10–20% of all cases) to more severe forms of LI and CIE.

Epidermolytic hyperkeratosis (EHK) has a pathophysiology that in several ways resembles epidermolysis bullosa simplex and pachonychia congenita; i.e. dominant negative mutations in keratins 1, 2 and 10 result in suprabasal cytolysis (22). The abnormal

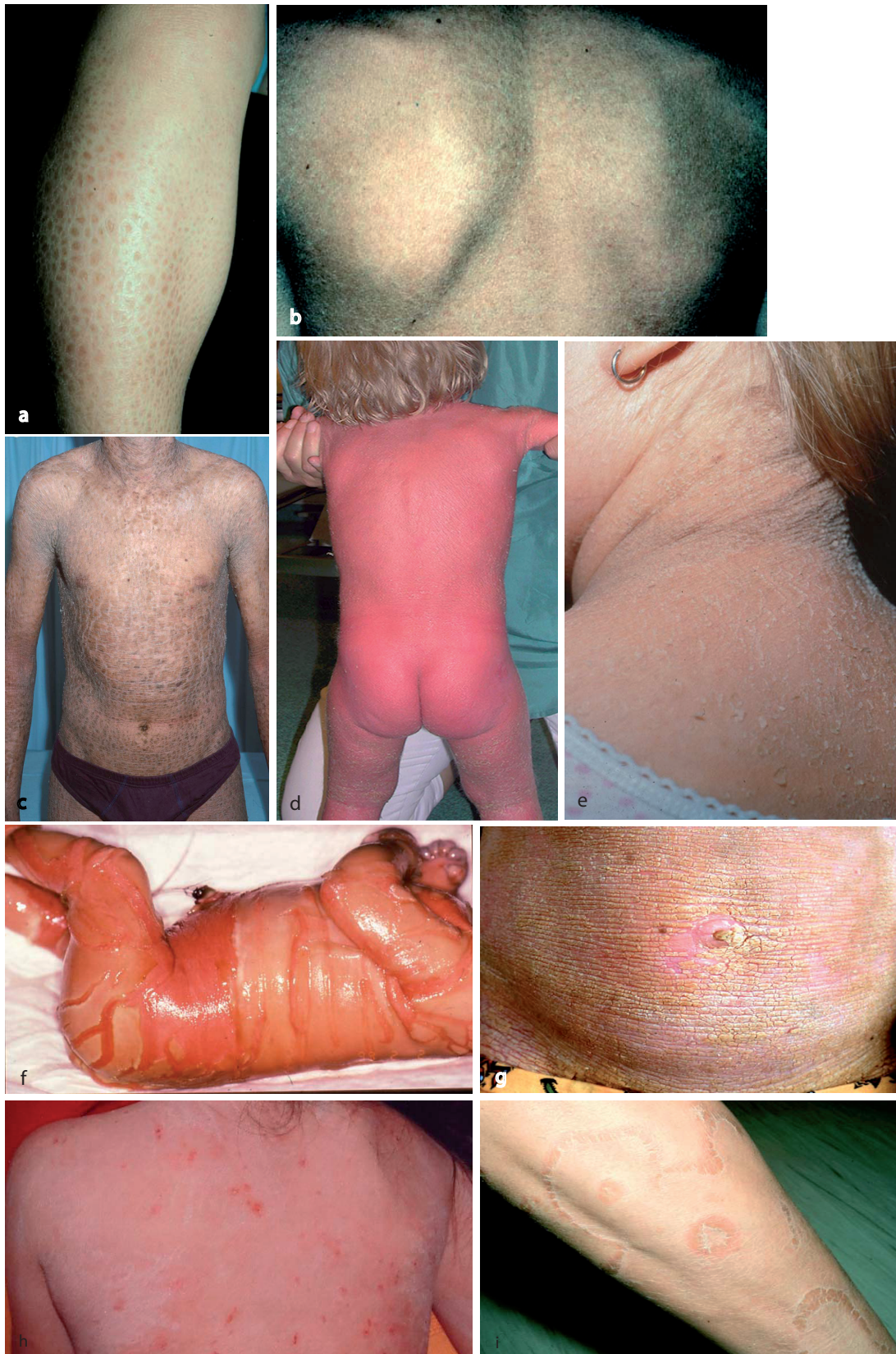

Fig. 1. Clinical appearance of various subtypes of ichthyosis: (a) ichthyosis vulgaris, (b) X-linked ichthyosis, (c) lamellar ichthyosis (LI) due to *TGMI* mutations, (d) congenital ichthyosiform erythroderma (CIE), (e) congenital ichthyosis with fine/focal scaling (CIFS), (f) severe case of collodion baby with associated features of harlequin ichthyosis, (g) epidermolytic hyperkeratosis due to a *KRT10* mutation, (h) Sjögren-Larsson syndrome with excoriations, and (i) Netherton syndrome in an adult person showing typical ichthyosis linearis circumflexa. Pictures from the authors file; Some have been previously published (13); Reproduced with permission from Acta Dermato-Venereologica.

keratins also interfere with the movement of lamellar bodies toward the cell periphery, resulting in defective intercorneocyte lipids, as in CIE (23). This probably explains the coexistence of hyperkeratosis and epidermolysis (Fig. 1g; Table I).

Syndromic ichthyosis is an even larger and more heterogeneous group of usually recessively inherited diseases. Only two types will be discussed here: Sjögren-Larsson syndrome (SLS), which is characterized by a pruritic ichthyosis, mental retardation and spastic diplegia (Fig. 1h), and Netherton syndrome (NS), characterized by a severe failure of the skin barrier, especially at birth, hair shaft abnormalities, atopy, pruritus and ichthyosis linearis circumflexa (Fig. 1i).

SLS is due to inactivating mutations in the *FALDH* gene (which encodes for a fatty aldehyde dehydrogenase), leading to a toxic accumulation of arachidonic acid-derived metabolites in the skin and brain (24). NS, on the other hand, is due to a deficiency of *LEKTI*, a protease inhibitor normally expressed in the horny layer as well as in the thymus (25). The scaly skin in NS is due to enhanced degradation of corneosomes and increased shedding of corneocytes. Thus there is a thinning of the horny layer instead of hyperkeratosis; however, in the adult skin ichthyosis may become more apparent probably as a consequence of compensatory hyperproliferation.

MANAGEMENT OF ICHTHYOSIS

General considerations

In addition to cosmetic problems, ichthyosis patients usually suffer from a series of medical problems that are directly or indirectly related to pathomechanisms which are also potential targets for therapy (Table II). The symptoms include: pruritus, painful fissuring of the thickened skin, decreased range of motion at joints, decreased tactile sensitivity especially of the fingers, hypohidrosis with heat intolerance, a liability to skin irritation, and, in some cases, an increased tendency to skin infection. The range and severity of symptoms usually vary considerably from one patient to another and may also change over time in one and the same patient. This makes it essential always to adjust therapy

Table II. Primary targets for ichthyosis therapy

Pathomechanism	Symptoms
<ul style="list-style-type: none"> <li>• Abnormal quality or quantity of scales</li> <li>• Abnormal thickness of stratum corneum</li> <li>• Skin inflammation</li> <li>• Barrier failure</li> <li>• Secondary infections</li> <li>• Obstruction of adnexal ducts</li> <li>• Stiffness of the skin</li> </ul>	<ul style="list-style-type: none"> <li>• Dryness (xerosis)</li> <li>• Scales</li> <li>• Fissures and erosions</li> <li>• Keratoderma</li> <li>• Erythema</li> <li>• Pruritus</li> <li>• Anhidrosis</li> <li>• Ectropion</li> </ul>

Table III. Therapy of ichthyosis – General considerations

Matters of concern when prescribing therapy
Children vs. adults
Common vs. rare type of ichthyosis
Mild vs. severe disease
Extent and location of the skin lesions
Transcutaneous absorption
Topical vs. systemic therapy
Patient adherence to therapy (compliance)
New therapies in the pipeline

according to the patient’s individual and current needs. Because most patients require life-long treatment, with daily applications of emollients all over the body, they are potential mega consumers of such products (estimated lifetime consumption of approximately onetonne of cream). In most cases, adult patients as well as adolescents soon become experts on how to treat their own skin.

A primary objective in ichthyosis therapy is to remove scales and to reduce uncomfortable dryness of the skin (xerosis) without causing too much irritation. To accomplish this, the following aspects have to be taken into consideration before prescribing a treatment (Table III): (i) the age and sex of the patient (children have a thinner skin and a higher skin surface area/body weight ratio, thus increasing the risk for systemic toxicity; females of child-bearing age should not be exposed to potentially teratogenic compounds), (ii) the type and severity of the disease (thick scales require keratolytic agents, xerosis requires only emollients, fissures and erosions may preclude the use of keratolytics and require antimicrobial therapy), (iii) the extent and location of the skin lesions (whole body application increases the risk for systemic toxicity; face and flexural sites usually require less potent therapy and are more at risk of skin irritation).

It is also essential for a health provider to discuss the patient’s willingness and ability to apply creams all over the body 1–3 times daily for long periods of time, and to keep an open mind regarding individual preferences about cream formulations. It should be borne in mind that cosmetic acceptability of a cream is a *sine qua non* for good compliance and that there are probably as many opinions about “the best cream formulation” as there are patients. Finally, it is important to keep the patient alert about new therapies that might be around the corner, always trying to maintain an optimistic attitude about future remedies.

Hydration, lubrication, keratolysis and antimicrobials

The therapeutic armature for treating ichthyoses extends from simple balneo-therapy and mechanical removal of scales to highly effective topical formulations and systemic therapy requiring strict medical attention. For

Table IV. Mechanisms of action of common additives in creams and ointments

Examples
Hydration – NaCl, urea, glycerol
Lubrication – Petrolatum and other lipids
Keratolysis – $\alpha$ -hydroxyacids (AHA), urea (>5%), propylene glycol, salicylic acid, N-acetylcysteinamide
Modulators of differentiation – Retinoids, calcipotriol
Antimicrobials

most types of ichthyoses, a first-line therapy includes hydration and lubrication, in order to improve the barrier function and facilitate desquamation. This can be accomplished by creams and ointments containing low concentrations of salt, urea or glycerol, which increase the water-binding capacity of the horny layer (Table IV). For ichthyoses with thick scaling and markedly increased stratum corneum thickness, addition of one or more keratolytic agents is needed to decrease corneocyte cohesiveness, to promote desquamation and to dissolve keratins and lipids. A wide variety of topical keratolytics can be used, including the  $\alpha$ -hydroxy acids (e.g. lactic acid and glycolic acid), salicylic acid, high dose urea, propylene glycol, N-acetylcysteine and retinoids. Some of these agents also have the ability to modulate keratinocyte differentiation. For example, topical retinoids including tretinoin (all-trans retinoic acid), adapalene and tazarotene, all have anti-keratinizing properties (26), and calcipotriol, a vitamin D derivative, retards epidermal hyperproliferation. Only when topical agents fail to induce a sufficient improvement should an introduction of systemic retinoids be considered (see below).

#### Treatment of mild disease (as in common ichthyosis)

The most rational way of treating IVU and XRI would be to compensate for missing or surplus components in the horny layer, viz. deficient breakdown products of filaggrin and excessive cholesterol sulphate, respectively. However, while some success has been reported using cholesterol-containing creams to counterbalance the high cholesterol sulphate levels in XRI skin (27), and creams containing a physiological mixture of ceramides and other skin lipids have been advocated to restore the skin barrier in other conditions (28), there is no solid evidence that substitution therapy is more effective than ordinary emollients in ichthyoses.

The current standard for treating mild to moderate IVU and XRI is therefore daily applications of emollients containing 2–10% urea (29), 5–15% lactic acid or glycolic acid (30), or 10–25% propylene glycol (31) (Table V).

Urea-containing creams seem to be more popular in Europe than in the USA, where mixtures containing propylene glycol or  $\alpha$ -hydroxy acids (AHA) are apparently a first-line choice (32). In a German study of children with ichthyosis, urea in a new lotion base was found to be a highly effective and well-tolerated topical therapy (33). Other treatment options include regular baths (salt and oil), ultraviolet irradiation, and climate therapy in the winter. Oral retinoid therapy is rarely indicated for common ichthyoses, but topical tazarotene has been advocated for XRI (see below). Topical corticosteroids and calcipotriol are usually contraindicated when, as in IVU and XRI, there is no hyperproliferation and inflammation involved. As such, these agents do not alleviate the disease process (34) and, moreover, they are associated with a significant risk for systemic absorption and side-effects when used extensively on large areas of the body.

#### Treatment of severe disease (as in lamellar ichthyosis and epidermolytic hyperkeratosis)

By combining two or more keratolytic agents and moisturizers in the same lipophilic cream base it is often possible to achieve additive or even synergistic effects in LI without the need to use irritating concentrations of either agent alone (Table VI). In a double-blind trial of 4 different cream mixtures in 20 patients with LI, a mixture of 5% lactic acid and 20% propylene glycol in a semi-occlusive cream for 4 weeks twice daily was significantly more effective than 20% propylene glycol or 5% urea alone in the same vehicle (35) (Fig. 2). Although the treatments were well tolerated, an efficient removal of hyperkeratosis without correcting the underlying biochemical defect in LI is likely to deteriorate the patient's intrinsic barrier problem, because an excessive production of corneocytes probably represents a homeostatic response to an ineffective barrier. Indeed, transepidermal water loss increased after successful treatment of LI with either topical keratolytics (35) or oral retinoid (36). Although this may not be noticeable by the patient, even minor deteriorations in the barrier function can enhance

Table V. Suggested therapeutic strategies in common ichthyoses (ichthyosis vulgaris and X-linked recessive ichthyosis)

Clinical symptoms	Adults	Children	Neonates
Mild	Emollients with urea	Emollients with glycerol	Pure emollients
Moderate	Simple keratolytics	Emollients with urea or PG	P/P
Severe	Keratolytics with a combination of AHA, PG or urea, Tazarotene	Keratolytics with combinations of AHA, PG or urea	P/P

AHA:  $\alpha$ -hydroxy acids; PG: propylene glycol; P/P: paraffin/petrolatum.

Table VI. Therapeutic strategies in rare, congenital ichthyosis (non-bullous, non-syndromic autosomal recessive congenital ichthyosis)

Symptoms	Adults	Children	Neonates
Mild	Simple keratolytics	Emollients with urea	Emollients with glycerol
Moderate	Keratolytics with a combination of AHA, PG or urea	Emollients with urea Keratolytics with PG	P/P Keratolytics with PG
Severe	Keratolytics as above plus salicylic acid N-acetylcysteineamide Calcipotriol, tazarotene Oral acitretin or isotretinoin	Keratolytics with a combination of AHA, PG or urea (calcipotriol, tazarotene) (Oral retinoids)	P/P in combination with a mild keratolytic (PG or urea) (Retinoids only exceptionally)

AHA:  $\alpha$ -hydroxy acids; PG: propylene glycol; P/P: paraffin/petrolatum.

transcutaneous penetration of active cream ingredients or other topically applied chemicals, which is a matter of special concern in children. Accordingly, AHAs and salicylic acid should not be used at all in babies, and only with great caution when treating large, eroded skin areas in adult patients (37, 38).

Many patients with LI use pumice, foot files or gentle rubbing of the skin after a hot bath or a shower to remove scales and hyperkeratosis. Overnight occlusion of problematic skin areas with plastic sheets after applying a thick layer of emollient or keratolytic agents is another way of potentiating therapy, especially on the scalp, which is notoriously difficult to treat. Although usually effective, all these remedies may further damage the skin barrier and lead to exaggerated epidermal proliferation, erythema, painful erosions and increased transcutaneous penetration.

The treatment of EHK is even more challenging in this respect. On the one hand, hyperkeratosis must be

reduced to minimize the disfiguring and foul-smelling scales, which harbour many micro-organisms. On the other hand, a too potent keratolytic treatment will aggravate the condition by disrupting the epidermal barrier and increasing the risk of painful blisters and skin erosions prone to infection. It is therefore important that treatment is individualized and that different body areas are treated differently depending on whether hyperkeratosis or erosions predominate. Therapy of EHK also relies on the use of bland emollients and a liberal prescription of antiseptics and antibiotics to prevent bacterial infection. Only occasionally is retinoid therapy indicated (see below).

Apart from emollients and keratolytic agents, topical applications of more specific drugs, such as tazarotene (39), N-acetylcysteine (40, 41), liarozole (see below) and calcipotriol (42–44) have also been tried in LI and EHK with variable success (Table VI). Some of these drugs probably act through reducing epidermal hyperproliferation associated with certain forms of LI. Others affect keratinocyte differentiations and hence corneocyte function.

#### *Adverse effects of topical therapy and reasons for non-compliance*

Except for a transient stinging, pruritus or skin irritation when applying the creams, the immediate local side-effects of topical therapy are usually minimal and any long-term toxic effects can usually be minimized if the topical remedies are used correctly. However, there are many other reasons why a therapy may fail. First of all topical treatment takes time and often has to be repeated many times per day. In children, although most parents try hard to convert the treatment sessions into something relaxing and positive for both parties, a rushed and too aggressive therapy may end in a fight between the child and his or her carer. By and large creams or ointments that are greasy, smell unpleasant, do not remain long on the skin, or are difficult to apply are likely to be underconsumed or even rejected by the patient. The selection of a suitable cream base (hydrophilic or lipophilic, non-occlusive or semi-occlusive) is thus of importance not only for optimal pharmacological effects of the active ingredients, including their pharmacokinetics and trans-

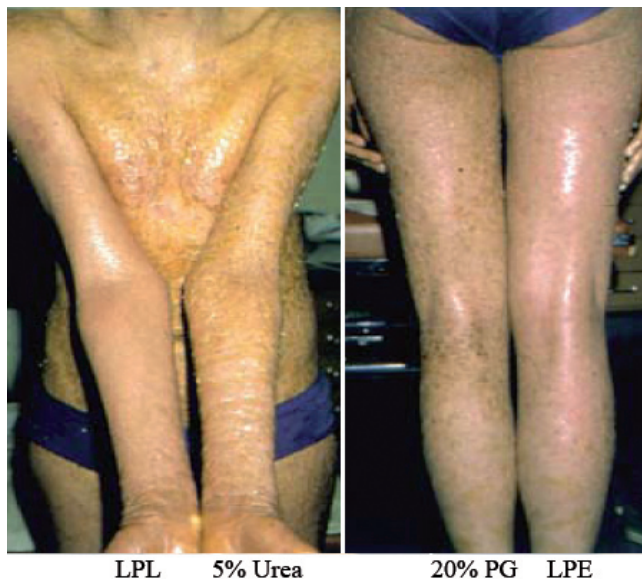


Fig. 2. Topical therapy of lamellar ichthyosis: effects of 4 different cream formulations applied to the extremities twice-daily for 4 weeks (from Gånemo et al. (35) with permission from Blackwell Publishing Inc.). LPL: 5% lactic acid and 20% propylene glycol in Locobase cream; LPE: 5% lactic acid and 20% propylene glycol in Essex cream; PG: propylene glycol only in Locobase cream.

cutaneous penetration (45), but also for the patient's adherence to therapy.

#### Oral retinoids and retinoic acid metabolism blocking agents (RAMBAs)

Retinoids have keratolytic effects that facilitate the shedding of scales from the surface and prevent excessive hyperkeratosis, thus leading to a more normal thickness and improved function of the horny layer (26). It is amazing that ichthyoses with such a broad spectrum of diverse aetiologies can respond to the same few systemic retinoid drugs. While the spectrum of efficacy and toxicity of different retinoids are similar and overlap, they are not identical. In different clinical situations there may be advantages of one retinoid over another. In the case of LI, both isotretinoin and the aromatic retinoids (etretinate, acitretin) have been found to be efficacious (46–48). The aromatic retinoids have a relatively greater effect on volar skin leading to an advantage in the treatment of palmoplantar hyperkeratosis. In Europe, acitretin is used almost exclusively in the systemic therapy of congenital ichthyosis with particularly good effects in LI, provided doses of 0.5–1 mg/kg/day are used (Fig. 3). But acitretin has a longer half-life of elimination than isotretinoin and may persist in the body for months after discontinuation of the drug. Isotretinoin, therefore, would pose a shorter duration of teratogenic risk and therefore may be preferred in female patients considering a future pregnancy.

Another side-effect of systemic retinoid therapy is skin fragility (49). Especially when the skin is prone to blistering, as in EHK, this tendency can be enhanced by retinoids. It is therefore important to start at low doses of retinoids in order to avoid exacerbation of the blistering in patients with EHK. It has been found that retinoid therapy, given topically as tretinoin, tazarotene, or adapalene, and systemically as acitretin, is more effective in patients with mutations in KRT10 compared with those with mutations in KRT1, probably because the former patients can better tolerate the inevitable down-regulation of KRT2 by retinoids (50). KRT2 and KRT1 appear to be mutually replaceable in the heterodimerization of keratin filaments, explaining why the presence of the former protein might reduce the negative impact of KRT1 mutations. Conversely, a down-regulation of KRT2 is the most likely explanation to why ichthyosis bullosa of Siemens (IBS), a superficial variant of EHK due to dominant KRT2 mutations (51), responds so well to low doses of retinoids (52). In essence retinoid treatment of IBS can be regarded as a case of pharmacological gene silencing.

In all types of ichthyosis retinoid therapy induces a decrease in skin thickness and scaling, which begins about 1–2 weeks after the initiation of therapy. Thickening recurs after the retinoid is discontinued. Com-

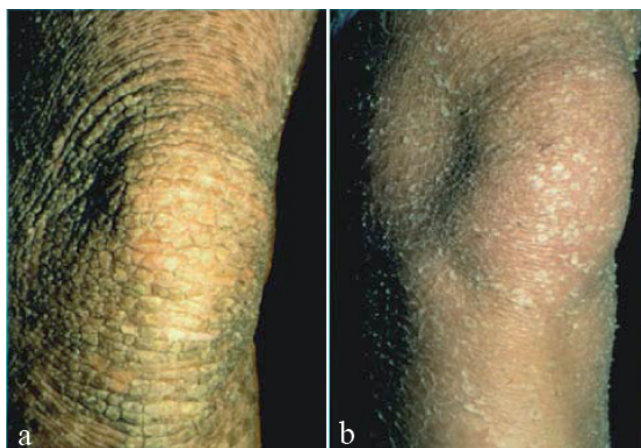

Fig. 3. Effects of systemic retinoid therapy in lamellar ichthyosis. Before (a) and after (b) one month of acitretin 1 mg/kg/day.

pared with LI, some patients with CIE may respond more completely and at lower doses (26, 47). Since the systemic retinoid therapy is likely to be used long-term, it is wise to keep the dose as low as is practical.

While blepharitis and conjunctivitis are well-known retinoid side-effects, these drugs are usually well tolerated by patients with ectropion (26, 46). The ability of systemic retinoids to decrease scale thickness often leads to a decreased tendency for ectropion to progress. Patients with ectropion should pay careful attention to eye care, with liquid tears and eye lubricants, particularly at night, when failure of the lids to close fully during sleep can lead to exposure keratitis. Topical ophthalmological antibiotics may be necessary for episodes of bacterial conjunctivitis.

An alternative to synthetic retinoid treatment is to manipulate the endogenous level of all-trans retinoic acid (tretinoin) by blocking its cellular catabolism in the skin with retinoic acid metabolism blocking agents (RAMBAs). The therapeutic effects (and side-effects) will then be restricted to tissues, which express enzymes involved in vitamin A metabolism (53). Various inhibitors of cytochrome P 450 (CYP) 26, the rate-limiting enzyme(s) in the catabolism of retinoic acid, have been developed as RAMBAs. Two such compounds, liarozole and rambazole, have been tested extensively in various skin diseases, including ichthyosis (54). Oral administration of liarozole in doses of about 0.1 g/day has a proven efficacy in LI (55; Vahlquist et al.<sup>1</sup>). Although the risk of teratogenicity must still be considered during RAMBA therapy, other retinoidal side-effects appear to be minimal and there is no carry-over effect of the drug

<sup>1</sup>Vahlquist A, Blockhuys S. Oral liarozole in lamellar ichthyosis (LILI): a multinational, double-blind, placebo-controlled trial evaluating safety and efficacy of 75 mg/day and 150 mg/day for 12 weeks. First World Conference on Ichthyosis, Münster, Germany, 2007.

after cessation of therapy. Liarozole has been granted orphan drug status in the treatment of congenital ichthyosis, but is presently not available on the market (Barrier Therapeutics, data on file).

### *Special considerations*

The birth of a child with severe congenital ichthyosis usually represents a first event in that family and regularly elicits a shock for the parents (and for the nursing staff). The psychological aspects must be dealt with promptly, preferably by professionals who know a lot about the disease. It is a great advantage if a specialized team, including a dermatological nurse, can visit the ward soon after the baby has been born. Education of the parents and the staff must start as soon as possible. It is essential that the parents also get involved in the daily care of the baby in the neonatal period. Skin contact should be encouraged provided good hand hygiene can be ascertained.

*Neonatal care of severe ichthyosis.* The collodion baby is born encased in a transparent, parchment-like membrane, which can interfere with respiration and sucking. Over the first 2 weeks of life, the membrane breaks up and desquamates. During this time, management should include careful monitoring of body temperature, hydration and blood electrolytes. Therapy should be aimed at keeping the skin soft and pliable, to reduce pain, e.g. from deep skin fissures, and to promote desquamation by using a humidified incubator and liberal application of lubricants. The same basic regimen, although more rigorously exercised, also applies to babies suffering from the harlequin phenotype or EHK, two forms of ichthyosis which are potentially lethal in the neonatal period. It is recommended that babies suffering from severe congenital ichthyosis should be treated only with baths and bland, semi-occlusive emollients, because application of occlusive ointments, such as petrolatum, may increase the risk of bacterial skin infections and septicaemia (56). Addition of glycerol to a cream mixture is probably safe, but more powerful agents, such as salicylic acid, urea and lactic acid, can easily cause systemic toxicity.

In rare cases, neonates with the most severe type of collodion or harlequin presentation have been treated with systemic acitretin to facilitate shedding of the membrane and to enhance survival of the babies (57–59).

*Netherton syndrome.* Due to a severely compromised skin barrier, these babies are at high risk of developing dehydration, hypernatraemia and septicaemia, which was often lethal in the past. With modern intensive care and antibiotic therapy the survival of these babies has increased dramatically (60). Again, topical application of occlusive creams should probably be avoided when

babies are kept in an incubator, and the vastly increased transcutaneous penetration of anything applied to the skin must always be remembered. Principally, substitution of the missing anti-protease (LEKTI) in the skin by applying an artificial inhibitor should be feasible, but so far no clinical trials have been commenced using this approach (61). Meanwhile, it is imperative to use frequent applications of bland emollients and non-toxic antiseptics. If pruritus and erythema become severe in older children, it may be necessary to prescribe short courses of a mild corticosteroid or the lowest concentrations of a calcineurin inhibitor (e.g. pimecrolimus) on limited body areas despite the risk of systemic toxicity (62–63). Adult patients with predominantly ichthyosis circumflexa often benefit from petrolatum-based ointments. Other standard treatments for ichthyosis may also be used, but potent keratolytics should be avoided. Retinoids, given either orally or topically, are more or less contraindicated because they induce skin irritation and may precipitate a flare of atopic eczema (64).

*Sjögren-Larsson syndrome.* This rare neuro-cutaneous genodermatosis often displays a characteristic skin phenotype in the first months of life. Although there is no skin erythema, the patients often suffer from pruritus, which may be severe and lead to excoriations in the midst of ichthyosis. This has been speculatively attributed to the accumulation of leukotriene-related metabolites in the skin. Accordingly, systemic treatment with a leukotriene antagonist, zileuton, has been tried in a few patients with SLS and reportedly reduced both pruritus and ichthyosis (65). However, the standard treatment of ichthyosis in SLS is no different from that in lamellar ichthyosis, with the possible exception that oral acitretin should be used more liberally (66). In a recent survey of 34 patients with SLS in Sweden we found a combination of lactic acid and propylene glycol in a semi-occlusive cream base to be particularly helpful in patients who had also been taking acitretin for many years and who could reduce the dosage to minimize the risk of retinoid-associated pruritus (Gånemo et al.<sup>2</sup>).

### UNMET NEEDS AND PROSPECTS FOR GENE THERAPY

At present there is no curative therapy for ichthyosis and some may argue that current therapies are tedious, only moderately effective and involve significant risks of side-effects. However, therapy for ichthyosis has improved considerably over the years and this is par-

<sup>2</sup>Gånemo A, Jagell S, Vahlquist A. Clinical characteristics and dermatology therapy in 34 cases of Sjögren-Larsson syndrome in Sweden (submitted).



ticularly true in the care of severe neonatal ichthyosis. Regrettably, two of the most troublesome symptoms associated with ichthyosis, anhidrosis and ectropion, are still quite resistant to therapy. Anhidrosis (or more correctly hypohidrosis, since sweating is often retained in a small spot on the forehead or upper lip) is very common among patients with ARCI (11). It is thought to reflect a functional inhibition of the sweat glands, because glands are normally present in the patient's skin. Obstruction of the sweat ducts as they pass through a hyperkeratotic stratum corneum is the preferred hypothesis, but this does not explain why efficiently treated patients may remain anhidrotic (36). Nor does it explain why occasional patients suddenly start sweating despite no change whatsoever in therapy or in the environment (AV, unpublished observation). More research and new therapies are clearly needed for this obscure and problematic symptom.

Ectropion, which can be massive at birth, usually persists to some degree in up to 70% of patients with LI (11). The severity of ectropion does not always correlate to the severity of the other skin symptoms and one eye may be more severely affected than the other, probably because conjunctivitis and/or keratitis worsens the ectropion and fluctuates in response to mechanical injury and infections. Although ichthyosis therapy and eye drops may improve ectropion to some degree (see above), skin transplantation from the neck or from behind the ear is often tried in severe cases. However, even when performed by an experienced eye surgeon, the results of transplantation are far from perfect and the effect usually lasts only a few years (AV, unpublished observation). There is an obvious need for more research on the mechanisms behind ichthyosis-associated ectropion and how best to restore the normal function of the eyelids.

The most severe forms of ichthyosis represent a serious handicap, requiring life-long therapy and affecting the patient's whole life situation. Associated complications, such as heat intolerance due to anhidrosis, eye disease, hearing problems due to debris in the external ear ducts, finger contractions, chronic skin infections, etc., add to the patients' morbidity and often require medical attention. Thus both medical and ethical considerations support the attempt to develop more "experimental" treatments, including cutaneous gene transfer, to help this group of patients. Clearly, many different approaches must be tried. For example, in the case of dominant negative gene mutations, such as in EHK, it should, at least in theory, be possible to silence a mutated keratin allele by applying RNAi technology. It is hoped that some encouraging *in vitro* results will soon lead to clinical trials (67). In the case of recessive disorders where an enzyme or transporter protein is missing, the principle of *ex vivo* gene transfer using cultured keratinocytes that are re-transplanted to the

patient might be possible (Fig. 4) (68). Promising results using experimental models suggest that, e.g. transglutaminase 1, might be restituted in this way (69). However, cutaneous gene therapy based on re-transplanted cells is a cumbersome procedure, especially if large areas of skin are to be treated. Therefore, although systemic gene therapy exploiting viral vectors is more risky, it probably represents the way forward, especially in syndromic forms of ichthyosis, such as SLS where the *FALDH* gene also needs to be replaced in the nervous system (70). It will certainly be exciting to follow the progress in this field over the next 5–10 years.

## CONCLUSION

Our understanding of how various genes are involved in causing ichthyosis has increased enormously over the last decade, revealing a spectrum of diverse pathogenic mechanisms that extend from abnormal structural proteins (keratins, filaggrin, loricrin, cornified cell envelope, etc.) to deficient enzymes or transport proteins essential for the lipid metabolism in the epidermis (cholesterol sulphatase, lipoxygenases, ABCA12, etc.). It is hoped that this new knowledge will lead to many novel therapies for specific subtypes of ichthyosis, including perhaps somatic gene therapy for the most severely affected patients.

Ichthyosis can indeed be a very disabling condition requiring laborious treatment several times a day, but it may also be a relatively mild disorder that only occasionally requires application of emollients. From both a diagnostic and therapeutic point of view, the many different subtypes of ichthyosis represent a challenge for a caring physician, who must learn to understand the underlying pathology. For instance, a paradoxical combination of barrier failure and massive hyperkeratosis in some types of ichthyosis requires special attention when prescribing therapy. It is likely that the choice

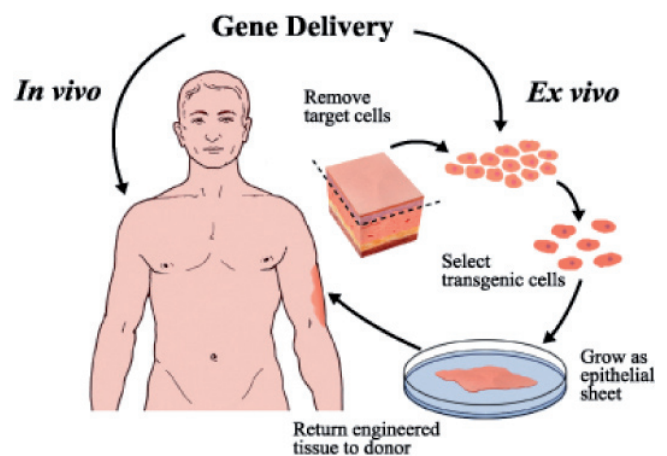


Fig. 4. Cutaneous gene therapy: basic principles (from (68) with permission from Blackwell Publishing Inc.).

of the best treatment for each individual will become increasingly important as more high-tech products appear on the market.

**Conflicts of interest:** The authors' research unit receives royalties from Astellas Pharma a/s for the sale of Locobase-LPL.

## REFERENCES

- Bousema M, van Diggelen O, van Joost T, Stolz E, Naafs F. Ichthyosis: reliability of clinical signs in the differentiation between autosomal dominant and sex-linked forms. *Int J Dermatol* 1989; 28: 240–242.
- Fleckman P, Brumbaugh S. Absence of the granular layer and keratohyaline define a morphologically distinct subset of individuals with ichthyosis vulgaris. *Exp Dermatol* 2002; 11: 327–336.
- Öhman H, Vahlquist A. The pH gradient over the stratum corneum differs in x-linked recessive and autosomal dominant ichthyosis: a clue to the molecular origin of the acid skin mantle? *J Invest Dermatol* 1998; 111: 674–677.
- Elias P, Crumrine D, Rassner U, Hachem J-P, Menon GK, Man W, et al. Basis for abnormal desquamation and permeability barrier dysfunction in RXLI. *J Invest Dermatol* 2004; 122: 314–319.
- Sato J, Denda M, Nakanishi J, Nomura J, Koyama J. Cholesterol sulfate inhibits proteases that are involved in desquamation of stratum corneum. *J Invest Dermatol* 1998; 111: 189–193.
- Smith FJ, Irvine AD, Terron-Kwiatkowski A, Sandilands A, Campbell LE, Zhao Y, et al. Loss-of-function mutations in the gene encoding filaggrin cause ichthyosis vulgaris. *Nat Genet* 2006; 38: 337–342.
- Scott I, Harding C, Barrett J. Histidine-rich protein of the keratohyalin granules. Source of the free amino acids, urocanic acid and pyrrolidone carboxylic acid in the stratum corneum. *Biochim Biophys Acta* 1982; 719: 110–117.
- DiGiovanna JJ, Robinson-Bostom L. Ichthyosis. Etiology, diagnosis and management. *Am J Clin Dermatol* 2003; 4: 81–95.
- Lavrijsen A, Oestmann E, Hermans J, Bodde H, Vermeer B, Ponc M. Barrier function parameters in various keratinization disorders: transepidermal water loss and vascular response to hexyl nicotinate. *Br J Dermatol* 1993; 129: 547–554.
- Nomura K, Nakano H, Umeki K, Harada K, Kon A, Tamal D, et al. A study of the steroid sulfatase gene in families with x-linked ichthyosis using polymerase chain reaction. *Acta Derm Venereol* 1995; 75: 340–342.
- Gånemo A, Pigg M, Virtanen M, Kukk T, Raudsepp H, Rossman-Ringdahl I, et al. Autosomal recessive congenital ichthyosis in Sweden and Estonia: clinical, ultrastructural and genetic findings in 83 patients. *Acta Derm Venereol* 2003; 83: 24–30.
- Oji V, Traupe H. Ichthyosis: differential diagnosis and molecular genetics. *Eur J Dermatol* 2006; 16: 349–359.
- Vahlquist A, Gånemo A, Pigg M, Virtanen M, Westermarck P. The clinical spectrum of congenital ichthyosis in Sweden: a review of 127 cases. *Acta Derm Venereol* 2003; Suppl. 213: 34–47.
- Huber M, Rettle I, Berbasconi K, Frenk E, Lavrijsen S, Ponc M, et al. Mutations of keratinocyte transglutaminase in lamellar ichthyosis. *Science* 1995; 267: 525–528.
- Ishida-Yamamoto A, Iizuka H. Structural organization of cornified cell envelopes and alterations in inherited skin disorders. *Exp Dermatol* 1998; 7: 1–10.
- Lefèvre C, Bouadjar B, Karaduman A, Jobard F, Saker S, Ozguz M, et al. Mutations in ichthyin a new gene on chromosome 5q33 in a new form of autosomal recessive congenital ichthyosis. *Hum Mol Genet* 2004; 13: 2473–2482.
- Dahlqvist J, Klar J, Hausser I, Anton-Lamprecht I, Hellström-Pigg M, Gedde-Dahl, Jr, et al. Congenital ichthyosis: mutations in ichthyin associated with specific structural abnormalities in the granular layer of epidermis. *J Med Genet* 2007; 44: 615–620.
- Jobard F, Lefèvre C, Karaduman A, Blanchet-Bardon C, Emre S, Weissenbach J, et al. Lipoxygenase-3 (ALOXE3) and 12(R)-lipoxygenase (ALOX12B) are mutated in non-bullous congenital ichthyosiform erythroderma (NCIE) linked to chromosome 17p13.1. *Hum Mol Genet* 2002; 11: 107–113.
- Lefèvre C, Jobard F, Caus F, Bouadjar B, Karaduman A, Heilig R, et al. Mutations in CGI-58, the gene encoding a new protein of the esterase/lipase/thioesterase subfamily, in Chanarin-Dorfman syndrome. *Am J Hum Genet* 2001; 69: 1002–1012.
- Akiyama M, Sugiyama-Nakagiri Y, Sakai K, McMillan JR, Goto M, Arita K, et al. Mutations in lipid transporter ABCA12 in harlequin ichthyosis and functional recovery by corrective gene transfer. *J Clin Invest* 2005; 115: 1777–1784.
- Kelsell DP, Norgett EE, Unsworth, The MT, Cullup T, Mein CA, et al. Mutations in ABCA12 underlie the severe congenital skin disease Harlequin ichthyosis. *Am J Hum Genet* 2005; 76: 794–803.
- Smith FJD. The molecular genetics of keratin disorders. *Am J Clin Dermatol* 2003; 4: 347–364.
- Schmuth M, Yosipovitch G, Williams ML. Pathogenesis of the permeability barrier abnormality in epidermolytic hyperkeratosis. *J Invest Dermatol* 2001; 117: 837–847.
- DeLaurenzi V, Rogers G, Hamrock D, Marekov LN, Steinert PM, Compton JG, et al. Sjögren-Larsson syndrome is caused by mutations in the fatty aldehyde dehydrogenase gene. *Nat Genet* 1996; 12: 52–57.
- Chavanas S, Bodemer C, Rochat A, Hamel-Teillac D, Ali M, Irvine AD, et al. Mutations in SPINK5, encoding a serine protease inhibitor, cause Netherton syndrome. *Nature Genetics* 2000; 25: 141–142.
- DiGiovanna JJ. Retinoid treatment of the disorders of cornification. In: Vahlquist A, Duvic M, editors. *Retinoids and carotenoids in dermatology*. New York: Informa Healthcare Inc., 2007; p. 153–169.
- Lykkesfeldt G, Hoyer H. Topical cholesterol treatment of recessive x-linked ichthyosis. *Lancet* 1983; 2: 1337–1338.
- Chamlin SL, Kao J, Frieden IJ, Sheu MY, Fowler, Fluhr JW, et al. Ceramide-dominant barrier repair lipids alleviate childhood atopic dermatitis: changes in barrier function provide a sensitive indicator to disease activity. *J Am Acad Dermatol* 2002; 47: 198–208.
- Pope FM, Rees JK, Wells RS, Lewis KGS. Out-patient treatment of ichthyosis: a double-blind trial of ointments. *Br J Dermatol* 1972; 86: 291–296.
- van Scott E, Yu R. Control of keratinization with alpha-hydroxy acids and related compounds. *Arch Dermatol* 1974; 110: 586–590.
- Rubeiz N, Kibbi A-G. Management of ichthyosis in infants and children. *Clinics Dermatol* 2003; 21: 325–328.
- Buxman M, Hickman J, Ragsdale W, Stretcher G, Krochmal L, Wehr RF. Therapeutic activity of lactate 12% lotion in the treatment of ichthyosis. *J Am Acad Dermatol* 1986; 15: 1253–1258.

33. Küster W, Bohnsack K, Rippke F, Upmeyer H, Groll S, Traupe H. Efficacy of urea therapy in children with ichthyosis. *Dermatology* 1998; 196: 217–222.
34. Okano M. Assessment of the clinical effect of topical tacalcitol on ichthyoses with retentive hyperkeratosis. *Dermatology* 2001; 202: 116–118.
35. Gånemo A, Virtanen M, Vahlquist A. Improved topical treatment of lamellar ichthyosis: a double-blind study of four different cream mixtures. *Br J Dermatol* 1999; 141: 1027–1032.
36. Kiistala R, Lauharanta J, Kanerva L. Transepidermal water loss and sweat gland response in lamellar ichthyosis before and during treatment with etretinate: report of three cases. *Acta Derm Venereol* 1982; 62: 268–269.
37. Ramirez ME, Youseef WF, Romero RG, Martinez JM, Gonzalez-Esenat MA, Vilaplana XS, et al. Acute percutaneous lactic acid poisoning in a child. *Ped Dermatol* 2006; 23: 282–285.
38. Chiaretti A, Schembri D, Tortorolo L, Piastra M, Polidori G. Salicylate intoxication using a skin ointment. *Acta Paediatr* 1997; 86: 330–331.
39. Stege H, Hofmann B, Ruzicka T, Lehmann P. Topical application of tazarotene in the treatment of nonerythrodermic lamellar ichthyosis. *Arch Dermatol* 1998; 134: 640.
40. Redondo P, Bauzá A. Topical N-acetylcysteine for lamellar ichthyosis. *The Lancet* 1999; 354: 1880.
41. Sarici SU, Sahin M, Yurdakök M. Topical N-acetylcysteine treatment in neonatal ichthyosis. *Turk J Pediatr* 2003; 45: 245–247.
42. Van de Kerkhof PCM. Biological activity of vitamin D analogues in the skin, with special reference to antipsoriatic mechanisms. *Br J Dermatol* 1995; 132: 675–682.
43. Lucker GPH, van de Kerkhof PCM, van Dijk MR, Steijlen PM. Effect of topical calcipotriol on congenital ichthyosis. *Br J Dermatol* 1994; 131: 546–550.
44. Borgenrieder T, Landthaler M, Stolz W. Bullous congenital ichthyosiform erythroderma: safe and efficient topical treatment with calcipotriol ointment on a child. *Acta Derm Venereol* 2003; 83: 52–54.
45. Vahlquist A. Ichthyosis – an inborn dryness and scaliness of the skin. In: Lodén M, Maibach HI, editors. *Dry skin and moisturizers*. New York: CRC Press, Informa, 2006: p. 83–94.
46. Blanchet-Bardon C, Nazzaro V, Rognin C, Geiger, J-M, Puissant A. Acitretin in the treatment of severe disorders of keratinization. *J Am Acad Dermatol* 1991; 24: 982–986.
47. Steijlen PM, van Dooren-Greebe RJ, van de Kerkhof PC. Acitretin in the treatment of lamellar ichthyosis. *Br J Dermatol* 1994; 130: 211–214.
48. Peck GL, Gross EG, Butkus D. Comparative analysis of two retinoids in the treatment of disorders of keratinization. In: Orfanos CE, editor. *Retinoids: advances in basic research and therapy*. New York: Springer Verlag, 1981: p. 279–286.
49. Sorg O, Kuenzli S, Saurat JH. Side effects and pitfalls in retinoid therapy. In: Vahlquist A, Duvic M, editors. *Retinoids and carotenoids in dermatology*. New York: Informa Healthcare Inc., 2007: p. 225–248.
50. Virtanen M, Gedde-Dahl T, Mörk N-J, Leigh I, Bowden PE, Vahlquist A. Phenotypic/genotypic correlations in patients with epidermolytic hyperkeratosis and the effects of retinoid therapy on keratin expression. *Acta Derm Venereol* 2001; 81: 163–170.
51. Kremer H, Zeeuwen P, McLean WH, Mariman EC, Lane EB, van de Kerkhof CM, et al. Ichthyosis bullosa of Siemens is caused by mutations in the keratin 2e gene. *J Invest Dermatol* 1994; 103: 286–289.
52. Steijlen PM, Vandoorengreebe RJ, Happel R, Vandekerckhof PCM. Ichthyosis bullosa of Siemens responds well to low-dosage oral retinoids. *Br J Dermatol* 1991; 125: 469–471.
53. van Wauwe J, Vannyen G, Coene MC, Stoppie P, Cools W, Goossens J, et al. Liarozole, an inhibitor of retinoic acid metabolism, exerts retinoid-mimetic effects in vivo. *J Pharmacol Exp Ther* 1992; 261: 773–779.
54. Lucker GP, Verfaillie CJ, Heremans AM, Vanhoutte FP, Boegeheim JP, Steijlen PM. Topical liarozole in ichthyosis: a double blind, left-right comparative study followed by a long-term open maintenance study. *Br J Dermatol*, 2005; 152: 566–569.
55. Lucker GP, Heremans AM, Boegeheim PJ, van de Kerkhof PC, Steijlen PM. Oral treatment of ichthyosis by the cytochrome P-450 inhibitor liarozole. *Br J Dermatol* 1997; 136: 71–75.
56. Van Gysel D, Lijnen RLP, Moekti SS, de Laat PCJ, Oranjet AP. Colloidion baby: a follow-up study of 17 cases. *J Eur Acad Derm Venereol* 2003; 16: 472–475.
57. Lawlor F, Peiris S. Harlequin fetus successfully treated with etretinate. *Br J Dermatol* 1985; 112: 585–590.
58. Rogers M, Scraf C. Harlequin baby treated with etretinate. *Pediatr Dermatol* 1989; 6: 216–221.
59. Bojs G, Vrana I, Gånemo A, Vahlquist A. Neonatal acitretin treatment of harlequin ichthyosis. *Retinoids* 2001; 39: 300–306.
60. Van Gysel D, Koning H, Basert MRM, Savelkoul HFJ, Neijens HJ, Oranje AP. Clinico-Immunological heterogeneity in Comél-Netherton Syndrome. *Dermatology* 2001; 202: 99–107.
61. Mazereeuw-Hautier J, Cope J, Ong C, Green A, Hovnanian A, Harper JJ. Topical recombinant alpha 1-antritypsin: a potential treatment for Netherton syndrome? *Arch Dermatol* 2006; 142: 396–398.
62. Allen A, Siegfried E, Silverman R, Williams ML, Elias PM, Szabo SK, et al. Significant absorption of topical tacrolimus in 3 patients with Netherton syndrome. *Arch Dermatol* 2001; 137: 747–750.
63. Oji V, Beijan G, Beier K, Traupe H, Luger TA. Topical pimecrolimus: a novel therapeutic option for Netherton syndrome. *Br J Dermatol* 2005; 153: 1067–1068.
64. Fritsch P. Oral retinoids in Dermatology. *Int J Dermatol* 1981; 20: 314–329.
65. Willemsen M, Lutt M, Steijlen PM, Cruysberg J, van der Graaf M, Nijhuis-van der Sanden, et al. Clinical and biochemical effects of zileuton in patients with the Sjögren-Larsson syndrome. *Eur J Pediatr* 2001; 160: 711–717.
66. Jagell S, Lidén S. Treatment of the ichthyosis of the Sjögren-Larsson syndrome with etretinate (Tigason®). *Acta Derm Venereol* 1983; 3: 89–91.
67. Hickerson RP, Smith FJ, McLean WH, Landthaler M, Leube RE, Kaspar RL. SiRNA-mediated selective inhibition of mutant keratin mRNAs responsible for the skin disorder pachyonychia congenita. *Ann N Y Acad Sci* 2006; 1082: 56–61.
68. Khavari PA, Rollman O, Vahlquist A. Cutaneous gene transfer for skin and systemic diseases. *J Intern Med* 2002; 252: 1–10.
69. Deng H, Choate KA, Lin Q, Khavari PA. High-efficiency gene transfer and pharmacological selection of genetically engineered human keratinocytes. *Biotechniques* 1998; 25: 274–280.
70. Huang S, Braun-Falco M. Restoration of fatty aldehyde dehydrogenase deficiency in Sjögren-Larsson syndrome. *Gene Ther* 2006; 13: 1021–1026.