

Calcipotriol Used as Monotherapy or Combination Therapy with Betamethasone Dipropionate in the Treatment of Nail Psoriasis

Tien-Yi Tzung^{1,2}, Ching-Yin Chen¹, Chia-Yi Yang³, Pei-Yu Lo¹ and Ya-Hui Chen¹

¹Department of Dermatology, Kaohsiung Veterans General Hospital, 386 Ta-Chung 1st Rd, Kaohsiung 813, ²Department of Dermatology and Institute of Biophotonics, National Yang Ming University, Taipei, and ³Department of Dermatology, Taipei City Hospital, Taipei, Taiwan.

*E-mail: tytzung@isca.vghks.gov.tw

Accepted October 24, 2007.

Sir,

Nail psoriasis is estimated to affect 80–90% of psoriatic patients at some point in their lives (1). Psoriatic patients with more severe nail disease tend to have a worse skin condition, a higher rate of unremitting and progressive arthritis, and more associated anxiety and depression (2, 3). In addition, nail psoriasis may considerably impair manual dexterity and foot biomechanics. However, management of nail psoriasis is often overlooked.

The most practicable management of nail psoriasis involves the use of topical vitamin D analogues and corticosteroids (1, 4), usually applied twice daily. Alternative treatments, such as topical 5-fluorouracil, tazarotene, and systemic acitretin, cyclosporine, and infliximab, have also been reported with some success (5–9). Compared with calcipotriol monotherapy, combination therapy using calcipotriol on weekdays and clobetasol on weekends provided better control of nail psoriasis (10). In plaque psoriasis, Guenther et al. (11) demonstrated that even once-daily combination therapy sufficed. The purpose of the present study was to compare the efficacy and safety of once-daily calcipotriol combination therapy with betamethasone dipropionate and twice-daily calcipotriol monotherapy in the treatment of nail psoriasis.

SUBJECTS AND METHODS

This randomized, investigator-blind, actively controlled, parallel group comparison study was approved by the local medical ethics committee. Patients of at least 20 years of age with finger nail psoriasis were allocated randomly to 2 groups (A and B) for 12-week treatment. Patients in group A applied 0.005% calcipotriol plus 0.05% betamethasone dipropionate ointment (Daivobet®, Leo Pharma Ltd, Ballerup, Denmark) once daily, while patients in group B applied 0.005% calcipotriol ointment (Daivonex®, Leo Pharma Ltd) twice daily. Those who had received topical anti-psoriatic treatment for nails within the previous 2 weeks were excluded. However, continuance of systemic anti-psoriatic medications was allowed if no improvement of nail psoriasis was found after 12 months of treatment.

In addition to an investigator's global assessment (0: worse; 1: no change; 2: slight improvement; 3: moderate improvement; 4: marked improvement; 5: clearance), the most severely affected fingernail was chosen as the target nail and evaluated every 4 weeks using the nail psoriasis severe index (NAPSI) (12). Briefly, each quadrant of the selected target fingernail was assessed for the presence or absence of nail matrix (pitting, leuconychia, red spots on lunula, and plate crumbling) or nail bed (oil drop discoloration, onycholysis, hyperkeratosis, and splinter haemorrhage) involvement. At the end of the study, patients were

asked to rate the improvement with their treatment (0: worse; 1: no change; 2: improved; 3: cleared). The difference in the therapeutic efficiency between calcipotriol monotherapy and combination therapy with betamethasone dipropionate at the baseline and across 4 time-points (0, 4, 8, and 12 weeks) were compared using Wilcoxon rank-sum tests and Student's *t*-tests. A *p*-value < 0.05 was considered statistically significant.

RESULTS

At baseline, patients in groups A and B had similar severity in terms of total scores (*p* = 0.649) and each of 8 nail features in NAPSI (*p* ≥ 0.180). Of 40 enrolled patients, 7 women and 25 men (age 53.2 ± 19.1 years) completed the study. Five patients in group A and 3 in group B dropped out for reasons unrelated to the treatment. No adverse event was found in either group throughout the study.

Compared with the baseline, 53% of the patients treated with either calcipotriol monotherapy or combination therapy with betamethasone dipropionate showed at least moderate improvement after 12-weeks of treatment by means of investigator's global assessment (Fig. 1). In addition, reduction of total scores using NAPSI was noted in both treatments (*p* ≤ 0.045). However, there was no statistically significant difference between the 2 treatments using either investigator's global assessment (*p* = 0.071) or NAPSI (*p* = 0.649). The result of patient's self-evaluation revealed a similar trend to the investigator's global assessment.

As for individual nail feature, both treatments were effective in improving oil drop discoloration (*p* ≤ 0.039). Other nail bed features as well as nail matrix features failed to show significant improvement regardless of the treatment (*p* ≥ 0.131). Nail crumbling worsened during the treatment course.

DISCUSSION

Unlike plaque psoriasis, once-daily combination therapy was as effective as, but not better than, twice-daily calcipotriol monotherapy in the treatment of nail psoriasis. However, once-daily application of combination therapy did have an advantage in terms of compliance. Indeed, compliance behaviour plays an important role in chronic cutaneous disease and nail psoriasis is no exception. Approximately 51% of

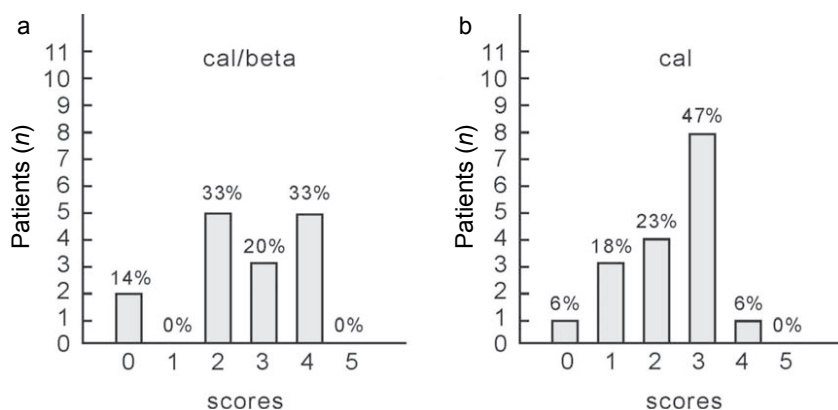


Fig. 1. Efficacy analysis based on the investigator's global evaluation after 12-weeks of treatment using combination therapy with (a) once-daily betamethasone dipropionate or (b) twice-daily calcipotriol monotherapy. Scores: 0: worse; 1: no change; 2: slight improvement; 3: moderate improvement; 4: marked improvement; 5: clearance.

the patients with psoriasis vulgaris in the Netherlands were advised to apply the topical treatment twice daily. However, only 26% of the patients did so (13). The main reason for deviation from instructions was that the patients preferred a lower frequency of application, namely, once daily.

Safety issues usually arise with long-term use of topical corticosteroids. Although no adverse event was found during the 12-week treatment course in our study, there was no direct evidence supporting the long-term safety of combination therapy in treating nail psoriasis. However, the results from plaque psoriasis indicated that combination therapy was safe for up to 52 weeks' use without an increase in the incidence of steroid-induced side-effects, such as skin atrophy and hypertrichosis (14).

In conclusion, despite similar efficacy in nail psoriasis, once-daily calcipotriol combination therapy might provide a better compliance for patients than twice-daily calcipotriol monotherapy, and therefore a better choice in managing nail psoriasis.

The authors declare no conflicts of interest.

REFERENCES

- de Berker D. Management of nail psoriasis. *Clin Exp Dermatol* 2000; 25: 357–362.
- Williamson L, Dalbeth N, Dockerty J, Gee BC, Weatherall R, Wordsworth BP. Nail disease in psoriatic arthritis-clinically important, potentially treatable and often overlooked. *Rheumatology* 2004; 43: 790–794.
- de Jong EM, Seegers BA, Gulink MK, Boezeman JB, van de Kerkhof PCM. Psoriasis of the nails associated with disability in a large number of patients: results of a recent interview with 1728 patients. *Dermatology* 1996; 193: 300–303.
- Sanchez Regaña M, Martin Ezquerro G, Umbert Millet P, Llambi Mateos F. Treatment of nail psoriasis with 8% clobetasol nail lacquer: positive experience in 10 patients. *J Eur Acad Dermatol Venereol* 2005; 19: 573–577.
- de Jong EM, Menke HE, van Praag MC, van de Kerkhof PCM. Dystrophic psoriatic fingernails treated with 1% 5-fluorouracil in a nail penetration enhancing vehicle: a double blind study. *Dermatology* 1999; 199: 313–318.
- Bianchi L, Soda R, Diluvio L, Chimenti S. Tazarotene 0.1% gel for psoriasis of the fingernails and toenails: an open, prospective study. *Br J Dermatol* 2003; 149: 193–227.
- Brazzelli V, Martinoli S, Prestinari F, Borroni G. An impressive therapeutic result of nail psoriasis to acitretin. *J Eur Acad Dermatol Venereol* 2004; 18: 229–230.
- Feliciani C, Zampetti A, Forleo P, Cerritelli L, Amerio P, Proietto G, et al. Nail psoriasis: combined therapy with systemic cyclosporine and topical calcipotriol. *J Cutan Med Surg* 2004; 8: 122–125.
- Reich K, Nestle FO, Papp K, Ortonne JP, Evans R, Guzzo C, et al. Infliximab induction and maintenance therapy for moderate-to-severe psoriasis: a phase III, multicentre, double-blind trial. *Lancet* 2005; 366: 1367–1374.
- Rigopoulos D, Ioannides D, Prasitis N, Katsambas A. Nail psoriasis: a combined treatment using calcipotriol cream and clobetasol propionate cream. *Acta Derm Venereol* 2002; 82: 140.
- Guenther L, Cambazard F, van de Kerkhof PCM, Snellman E, Kragballe K, Chu AC, et al. Efficacy and safety of a new combination of calcipotriol and betamethasone dipropionate (once or twice daily) compared to calcipotriol (twice daily) in the treatment of psoriasis vulgaris: a randomized, double-blind, vehicle-controlled clinical trial. *Br J Dermatol* 2002; 147: 316–323.
- Rich P, Scher RK. Nail Psoriasis Severity Index: a useful tool for evaluation of nail psoriasis. *J Am Acad Dermatol* 2003; 49: 206–212.
- van de Kerkhof PCM, de Hoop D, de Korte J, Cobelens SA, Kuipers MV. Patient compliance and disease management in the treatment of psoriasis in the Netherlands. *Dermatology* 2000; 200: 292–298.
- Kragballe K, Austad J, Barnes L, Bibby A, de la Brassinne M, Cambazard F, et al. A 52-week randomized safety study of a calcipotriol/betamethasone dipropionate two-compound product (Dovobet®/Daivobe®/Taclonex®) in the treatment of psoriasis vulgaris. *Br J Dermatol* 2006; 154: 1155–1160.