

Chronic Urticaria and Angioedema with Concomitant Eosinophilic Vasculitis due to *Trichinella* Infection

Regina Renner¹, Anne Fleck², Stefan Schubert³, Christoph Baerwald², Jörg Beer⁴, Ralf Schober⁵, Konstanze Holl-Ulrich⁶ and Michael Sticherling⁷

¹Clinic of Dermatology, Venereology und Allergology, ²Medical Clinic IV of Internal Medicine, Department of Rheumatology, ³Medical Clinic IV of Internal Medicine, Department of Infectiology and Tropical Medicine, ⁴Institute of Medical Microbiology, ⁵Department of Neuropathology, University of Leipzig, Leipzig, ⁶Centre of Consultation and Reference of Vasculitis Diagnostics, Institute of Pathology, University of Schleswig-Holstein, Campus Lübeck and ⁷Clinic of Dermatology, University of Erlangen, Erlangen, Germany. E-mail: regina.renner@medizin.uni-leipzig.de
Accepted May 24, 2007.

Sir,

Acute and chronic urticaria are very common. Underlying causes can be highly heterogeneous. Various drugs, physical factors, auto-immunological factors, allergic and pseudoallergic reactions or infections can result in the clinical manifestation of urticaria, which is a symptom rather than a distinct disease. The most common infections are *Helicobacter pylori*, streptococcal or viral infections (1). Rare causes are protozoa, helminths or other parasitic infections (2). We report here a very rare case of eosinophilic vasculitis in urticaria associated with trichinella infection.

CASE REPORT

A 63-year-old woman had had severe attacks of urticaria for months with coexistent facial and pharyngeal angioedema, persisting for more than 24 h. As a consequence she had been treated several times by an emergency physician and at an inpatient clinic. Searching for underlying causes, an eosinophilic cell count up to 60.9% (normal range 0–7%) with accompanying leukocytosis of 20.5 exp⁹/l (normal range 4.0–9.0 exp⁹/l) and moderately increased levels of C-reactive protein (CRP) of 18 mg/l (normal range <5 mg/l) was found, in addition to moderate pleural effusions. Allergological or neoplastic foci could be excluded by screening examinations and blood tests. Skin biopsies showed eosinophilic perivascular and interstitial dermatitis, which was interpreted as an early sign of eosinophilic vasculitis (Fig. 1). Neither leukocytoclasia nor abundant neutrophilic granulocytes were found.

Following oral dapsone, 50 mg/day, and oral histamine receptor blocker (fexofenadine 180 mg/day), the patient recovered temporarily, followed by a severe relapse of urticaria, progressive myasthenia and distinctly deteriorated general condition. The peripheral eosinophilic cell count eventually increased to well over 60%, with accompanying leukocytosis of 29.2 exp⁹/l. Further clinical examination excluded hemato-oncological disease, intestinal helminths or bacterial infection. However, a distinctly elevated antibody titre of 1:1024 to *trichinella spiralis* was found by immunofluorescence test. A detailed re-anamnesis showed that the patient had sometimes eaten home-slaughtered pork. Myasthenia and muscle pain correlated with pathological electromyography and unspecific myopathic changes in the muscle biopsy, but muscle biopsy failed to detect encysted trichinosis. Creatine kinase was in the normal range. Neurological or ocular manifestations of trichinosis could be excluded. Based on the diagnosis of acute trichinosis, oral prednisolone pulse in combination with mebendazole and a second course of albendazole was initiated. Laboratory parameters and overall clinical symptoms both improved, with persistent absence of urticaria and other symptoms, after a second course of treat-

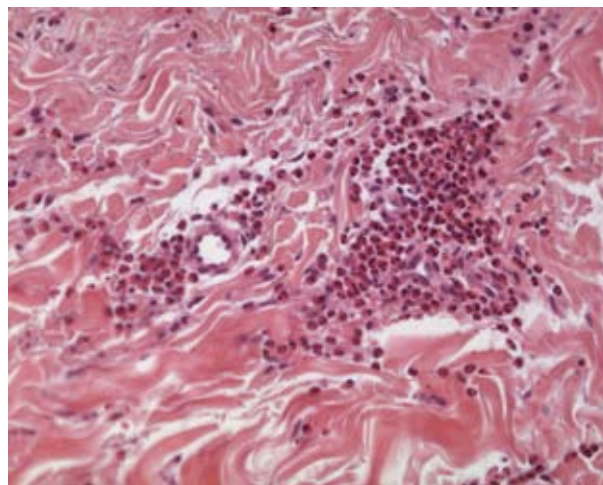


Fig. 1. Skin biopsy showing dense perivascular cuffing of eosinophils with prominent endothelial cells of capillaries and venules as well as scarce diffuse interstitial eosinophilia (H&E $\times 200$).

ment 4 weeks later, accompanied by complete normalization of eosinophilic cell count in the peripheral blood. Local health authorities were informed (§7(Infection Protection Act, IPA) and involved in the evaluation.

DISCUSSION

Urticaria has an estimated prevalence of 1.3% in the general population (3). Among patients with urticaria, at least 2% have urticaria vasculitis (4). The differential diagnosis of urticaria with eosinophilic dermatitis and eosinophilic vasculitis includes hypersensitivity reactions as well as Churg-Strauss syndrome, other hyper-eosinophilic syndromes and parasitic infections. Vasculitis associated with parasitosis is an isolated event and has very rarely been described (5). Histological descriptions include vasculitis of polyarteriitis nodosa type with perivascular and dermal eosinophilia. The simultaneous occurrence of vasculitis and parasitosis may result from: (i) direct effects of parasites on the vasculature, as seen by histologically altered vascular walls; or (ii) immunopathological phenomena occurring during the anti-parasite immune response. Deposition of circulating immune complexes, cross-reactivity of anti-helminthic IgE with parasitic and human vessel

wall antigens, or hyper-eosinophilia-induced tissue damage (6) may be involved. In the case described here, vasculitis might have been induced by overwhelming immune response due to low numbers of trichinae larvae. Accordingly, muscle biopsy was negative, but IIFT was strongly positive. This could also explain the high titres of eosinophils in the peripheral blood.

Trichinosis is caused by nematodes of *Trichinella* spp. *T. spiralis*, representing the most frequently food-transmitted helminthic zoonosis (7). Pigs are the most commonly infected domestic animals. In humans, the incidence of infection depends on the number of ingested vital *Trichinella* larvae in raw or undercooked meat. Gastric acid liberates the larvae from ingested cysts, which develop into adults. Newborn larvae of the adults penetrate the intestinal wall and move via the bloodstream. They can be found in cardiac and brain tissue as well as in striated muscles. The life cycle is completed when the larvae become encysted at the implantation area.

Initial clinical symptoms are related to the gastrointestinal tract (40–60%), for example vomiting, diarrhoea and gastrointestinal pain. Clinically unspecific symptoms, such as weakness (75%) or fever (60–75%) can result, as well as myalgias or arthralgias (75%) or even acute myocardial injury. Focal neurological deficits, diffuse encephalopathy or headache (50–60%) can develop. Additionally, peripheral hyper-eosinophilia may be seen (8).

Dermatological symptoms include periorbital oedema, urticaria, conjunctival petechiae, splinter haemorrhages of the fingernails and non-specific skin rashes or palmar rash (9, 10). The latter has been described in approximately 10% of patients with trichinosis. The rash consisted of bilateral hand swelling and macular erythema primarily along the perimeters of the palms and volar side of the digits, followed by desquamation. Angioedema is an uncommon complaint of helminthic infections (11), and vasculitis associated with trichinosis is very rarely described (5).

Definite diagnosis depends on finding the encysted cell-parasite complex in muscle biopsy by microscopic examination or detection of *Trichinella*-specific DNA by PCR. Muscle biopsy can be negative due to a low number of larvae or an early stage of the disease. Indirect evidence of the infection can be made by history, clinical symptoms, peripheral blood hyper-eosinophilia, elevated muscle enzymes and serological tests, such as enzyme-linked immunosorbent assay (ELISA) (12).

Specific treatment is not necessary in mild cases. In moderate or severe cases, mebendazole or albendazole are the drugs of choice, sometimes in combination with anti-inflammatory prednisolone to reduce host inflammatory responses (e.g. Jarisch-Herxheimer reaction)

or anti-pyretic and analgetic medicaments during myopathic signs.

The incidence of trichinosis varies worldwide, depending on dietary habits and legal controls. In Germany, the incidence has been very low since veterinarian controls of meat were instigated more than 100 years ago. The Robert-Koch Institute registered a total of 27 cases of trichinosis between 2000 and 2005. The last cluster detected, of 17 cases with trichinosis, was seen in Mecklenburg-Vorpommern between December 2005 and March 2006 (13). The legal requirements for veterinarian controls in commercial or home-slaughtered animals may, however, not always be followed, particularly in the case of home-slaughtered animals, wild pigs or imported meat.

In our case the patient developed trichinosis despite the correct and inconspicuous meat inspection. Although several members of the patient's household had eaten the same meat, no other person developed trichinosis.

Conflict of interest: This work was not supported by any funding sources and has not been presented previously. The authors have no conflict of interest to disclose.

REFERENCES

1. Wedi B, Raap U, Kapp A. Chronic urticaria and infections. *Curr Opin Allergy Clin Immunol* 2004; 4: 387–396.
2. Nenoff P, Domula E, Willing U, Herrmann J. Giardia lamblia: Ursache von Urticaria und Pruritus oder zufällige Assoziation? *Hautarzt* 2006; 57: 518–522.
3. Paul E, Greilich KD. Zur Epidemiologie der Urtikariaerkrankungen. *Hautarzt* 1991; 366–375.
4. O'Donnell B, Black AK. Urticarial vasculitis. *Int Angiol* 1995; 14: 166–174.
5. Lhote F. Systemic vasculitis during parasitosis. *Presse Med* 2004; 33: 1389–1401.
6. Frayha RA. Trichinosis-related polyarteritis nodosa. *Am J Med* 1981; 71: 307–312.
7. Neafie RC, Marty AM, Andersen EM. Trichinosis. In: Meyers WM, editor. Pathology of infectious diseases vol. 1. Helminthiasis, Armed Forces Institute of Pathology, American Registry of Pathology, Washington, 2000: p. 407–422.
8. Arnold LK. Trichinosis. 2005. Available from: www.emedicine.com
9. Walsh DS, Jongsakul K, Watt G. Hand rash in trichinosis. *Clin Exp Dermatol* 2001; 26: 272–273.
10. Chaudhry AZ, Longworth DL. Cutaneous manifestations of intestinal helminthic infections. *Dermatol Clin* 1989; 7: 275–290.
11. Van Dellen RG, Maddox DE, Dutta EJ. Masqueraders of angioedema and urticaria. *Ann Allergy Asthma Immunol* 2002; 88: 10–14.
12. Despommier DD, Gwadz RW, Hotez PJ, Knirsch CA. *Trichinella Spiralis*. In: Parasitic diseases, fifth edition. Apple Trees Productions, NY: LLC, p. 135–142.
13. Robert-Koch-Institut: Trichinellose: zu einer Häufung in Mecklenburg-Vorpommern. *Epidemiologisches Bulletin* 2006; 18: 139–140.