

## Cetuximab-induced Acneiform Eruption and the Response to Isotretinoin

Pamela Vezzoli<sup>1</sup>, Angelo Valerio Marzano<sup>1</sup>, Francesco Onida<sup>2,3</sup>, Elvio Alessi<sup>1</sup>, Barbara Galassi<sup>2</sup>, Maurizio Tomirotti<sup>2</sup> and Emilio Berti<sup>4</sup>

<sup>1</sup>Institute of Dermatological Sciences, University of Milan – Fondazione IRCCS Ospedale Maggiore Policlinico, Mangiagalli e Regina Elena, Via Pace 9, IT-20122 Milan, <sup>2</sup>Oncology Unit, Fondazione IRCCS Ospedale Maggiore Policlinico, Mangiagalli e Regina Elena and University of Milan, <sup>3</sup>Department of Medical Sciences, University of Milan, Italy, and <sup>4</sup>Dermatology, University of Milano Bicocca, Milan, Italy. E-mail: pamela.vezzoli@libero.it  
Accepted May 24, 2007.

Sir,

Epidermal growth factor receptor (EGFR) is commonly over-expressed in tumours. Its main function is to promote the growth and division of cells by the activation of various intracellular signalling pathways. The monoclonal human-murine chimeric antibody cetuximab is a member of a new family of anti-neoplastic agents that specifically targets and locks on to the EGFR, causing receptor internalization and preventing ligand-mediated receptor activation (1). Clinical trials with cetuximab, as a single therapeutic agent or in combination with other drugs, have demonstrated significant activity in several EGFR-expressing tumours, notably in patients previously resistant to chemotherapy (2). Unlike conventional cytotoxic agents, cetuximab does not cause myelosuppression, neuropathy, significant constitutional symptoms, or alopecia (3). In contrast, cutaneous side-effects are common, the most frequent of which is an acneiform eruption, usually observed within 1–3 weeks after the onset of treatment (4–7). The question of whether this disorder is responsive to classical anti-acne treatments, remain poorly elucidated. We report here typical acneiform eruption in 2 patients with metastatic colorectal cancer treated with cetuximab and their responses to antibiotics and isotretinoin, respectively.

### PATIENTS AND METHODS

#### Case 1

A 52-year-old woman under treatment with cetuximab was referred to our dermatology clinic for an acneiform eruption that had appeared approximately one week earlier and was associated with mild itching. The patient had undergone surgery for a metastatic colorectal adenocarcinoma (CCR) 4 years previously, and since that time had been treated by different polychemotherapy regimens. In January 2006, because of disease progression, a combined therapy was initiated, consisting of cetuximab at a dosage of 400 mg/m<sup>2</sup> for the first administration followed by 250 mg/m<sup>2</sup> from the second administration on, and irinotecan (90 mg/m<sup>2</sup>) both given intravenously every week. Three days after the second administration of cetuximab, the patient experienced a diffuse acneiform eruption on the face, neck, trunk and upper extremities. Physical examination showed a diffuse facial erythema associated with slightly itchy erythematous papules and pustules, with no visible comedones (Fig. 1). At that time, the patient was not receiving any other drug. The acneiform eruption was classified according to the National Cancer Institute Common Terminology Criteria for Adverse Events version 3.0 as grade 2. Neither bacteria nor fungi were found on culture of pustular lesions. Histopatholo-

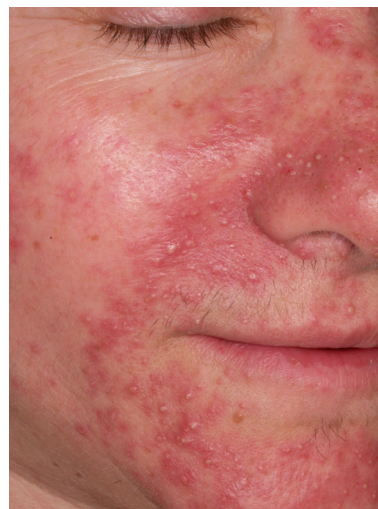

Fig. 1. Case 1: diffuse facial erythema associated with papulopustular lesions, with no comedones.

gical examination of a pustular lesion on the face revealed a neutrophilic folliculitis and a perifollicular dense inflammatory infiltrate of neutrophils and lymphocytes; focally, rupture of the epithelial lining of follicles was documented. Moreover, there was a foreign-body reaction with multinucleated giant cells (Fig. 2). Special stains for bacteria or fungi were negative. Systemic antibiotic therapy with claritromycin 500 mg twice daily for 7 days, combined with application of boric acid solution 2% and zinc oxide cream, was given. Moreover, cetuximab infusion was interrupted for 2 weeks. Acneiform rash almost completely resolved with no scarring within 2 weeks, no local or systemic adverse effects being observed during the above treatment. The therapy with cetuximab was then restarted at the same dosage, with no further cutaneous adverse effects.

#### Case 2

A 64-year-old man presented with a slightly pruritic acneiform rash that had developed suddenly 5 days earlier, the day after the second infusion of cetuximab as part of treatment for a chemotherapy-refractory metastatic CCR. Since the diagnosis of such malignancy, which was made 6 years previously, and treated initially with surgery in combination with local radiotherapy, the patient had received various chemotherapy regimens. In September 2006, due to disease progression, treatment with cetuximab and irinotecan (at the same doses and schedule as in patient 1) was started. The patient's acneiform eruption was similar to that seen in case 1, being localized on the same sites (Fig. 3). Also, in this case histology revealed neutrophilic folliculitis and perifolliculitis with multinucleated giant cells and follicle destruction. Temporary cetuximab withdrawal was subsequently decided on, and treatment including oral doxycycline (100 mg twice daily for 10 days) in association with topical preparations

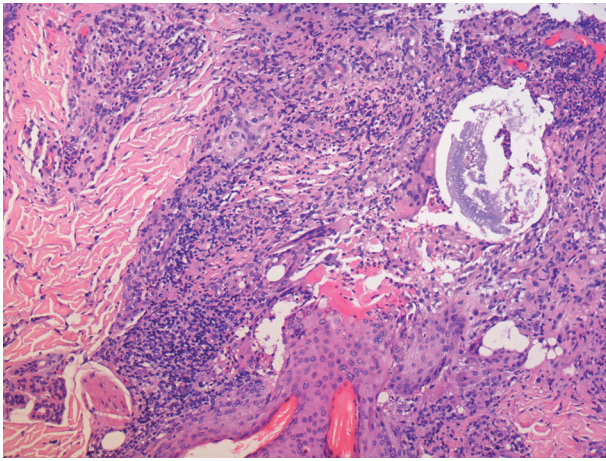


Fig. 2. The neutrophilic inflammatory infiltrate revealing focal rupture of the epithelial lining of a follicle and a mixed neutrophilic and lymphocytic infiltrate (H&E stain; original magnification  $\times 200$ ).

(boric acid solution 2% and mupirocin) was administered, with no response. Thus, oral isotretinoin 30 mg daily for 20 days was given, inducing good improvement of the acneiform lesions, but leading to formation of milia. Isotretinoin dose was then lowered to 20 mg daily and cetuximab therapy was restarted concurrently at the initial dosage, with no relapses of acneiform eruption. The patient tolerated isotretinoin very well and, in April 2007, he was free of dermatological lesions with no therapy.

## DISCUSSION

EGFR is expressed in the epidermis, the sweat gland apparatus and hair follicle epithelium (6), playing a central role in the normal differentiation and development of the hair follicle (8). Because EGFR is expressed in epidermal and follicular keratinocytes, EGFR-blocking agents, such as cetuximab, promote the development of cutaneous side-effects, notably acneiform eruptions, which are reported as occurring in up to 90% of patients (9). Failure of hair follicles to enter the catagen stage observed in transgenic mice expressing an EGFR dominant-negative mutation in the basal layer of the epidermis and the follicular outer root sheath, which

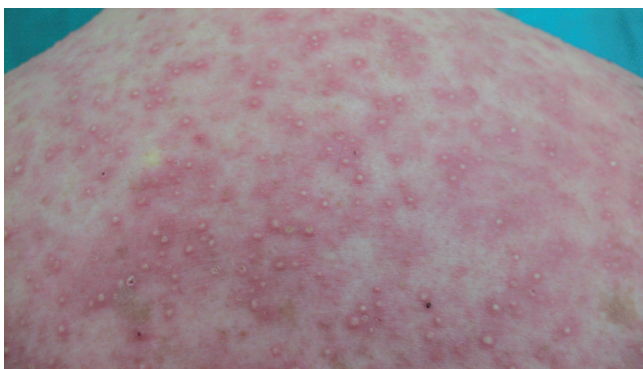

Fig. 3. Case 2: monomorphic cetuximab-induced acneiform eruption on the back.

causes follicular rupture accompanied by severe inflammatory reaction (10). Indeed, rupture of the follicular epithelial lining with involvement of hair follicle by a florid, mainly neutrophilic inflammatory infiltrate is regarded as the histopathological hallmark of cetuximab-induced acneiform eruption (6, 7), as confirmed by our 2 cases. The precise mechanism by which inhibition of EGFR leads to acneiform eruption is unknown. Upregulation of p27Kip1 protein, a negative cell cycle regulator, has been observed recently during cetuximab treatment, suggesting that p27Kip1 could play a part in mediating the post-receptor effects of this drug (6). The clinical features of cetuximab-induced acne are regarded as distinctive, this form being marked by sudden onset and a more widespread and monomorphous distribution of the lesions compared with classical acne (11). Notably, the lesions may affect sites not usually involved in classical acne, such as the extremities and lower part of the back. Moreover, cetuximab-induced acne is characterized by purely inflammatory lesions, i.e. papules and pustules, with no retentional lesions such as comedones or cysts (11). Finally, the lesions are sometimes pruritic. All of the above clinical findings were also seen in our 2 patients.

The time to appearance of lesions is typically very short, with a mean of 10 days after initiation of the therapy with cetuximab (11). Interestingly, several reports indicate a correlation between the intensity of the acneiform rash and anti-neoplastic efficacy of cetuximab, the rash being a marker of clinical benefit. Moreover, a positive correlation between the degree of rash and the time of survival in patients treated with cetuximab has been found (4, 5). The therapeutic management of cetuximab-induced acne remains controversial. Some authors recently suggested that grading of acneiform rash is an essential step toward determining what management strategies are most appropriate (12). For grade 1 rash, it is recommended to use topical antibiotics. Grade 2 rash should also be treated with topical antibiotic preparations. Systemic antibiotics, notably oral doxycycline, may be added mainly for anti-inflammatory effect. Patients at grade 3 should follow the same treatment, increasing the dosage of systemic antibiotics and delaying therapy with cetuximab. Finally, patients at grade 4 should stop treatment. High-potency topical steroids and oral antihistamines may be added to increase the anti-inflammatory effect and to relieve itching, respectively. Preventive treatment with systemic tetracycline proved effective in blocking the emergence of cetuximab-induced acneiform eruption in an anecdotal report (13). Because of the high frequency of acneiform eruptions associated with EGFR-targeted chemotherapy, we suggest that a preventive regimen should be evaluated. Recent observations (14, 15) suggest that treatment with isotretinoin may result in an overall improvement of cetuximab-induced skin

lesions, while several authors do not recommend its use as the pathophysiology of EGFR-inhibitor rash and acne vulgaris differ. We obtained good results using this drug in one of our two cases in which doxycycline had previously failed to induce clinical remission.

## REFERENCES

- Mendelsohn J, Baselga J. Status of epidermal growth factor receptor antagonists in the biology and treatment of cancer. *J Clin Oncol* 2003; 21: 2787–2799.
- Salomon DS, Brandt R, Ciardiello F, Normanno N. Epidermal growth factor-related peptides and their receptors in human malignancies. *Crit Rev Oncol Hematol* 1995; 19: 183–232.
- Shepherd FA, Pereira J, Ciuleanu TE, Tan EH, Hirsh V, Thongprasert S, et al. A randomized placebo controlled trial of erlotinib in patients with advanced non-small cell lung cancer (NSCLC) following failure of first line or second line chemotherapy: a National Cancer Institute of Canada clinical trials group (NCIC CTG) trial. *J Clin Oncol* 2004; 22: 7022.
- Cunningham D, Humblet Y, Siena S, Khayat D, Bleiberg H, Santoro A, et al. Cetuximab monotherapy and cetuximab plus irinotecan in irinotecan-refractory metastatic colorectal cancer. *N Engl J Med* 2004; 351: 337–345.
- Saltz LB, Meropol NJ, Loehrer PJ Sr, Needle MN, Kopit J, Mayer RJ. Phase II trial of cetuximab in patients with refractory colorectal cancer that expresses the epidermal growth factor receptor. *J Clin Oncol* 2004; 22: 1201–1208.
- Busam KJ, Capodiec P, Motzer R, Kiehn T, Phelan D, Halpern A. Cutaneous side-effects in cancer patients treated with the antiepidermal growth factor receptor antibody C225. *Br J Dermatol* 2001; 144: 1169–1176.
- Jacot W, Bessis D, Jorda E, Ychou M, Fabbro M, Pujol JL, et al. Acneiform eruption induced by epidermal growth factor receptor inhibitors in patients with solid tumours. *Br J Dermatol* 2004; 151: 238–241.
- Luetteke NC, Qiu TH, Peiffer RL, Oliver P, Smithies O, Lee DC. TGF alpha deficiency results in hair follicle and eye abnormalities in targeted and waved-1 mice. *Cell* 1993; 73: 263–278.
- Hu JC, Sadeghi P, Pinter-Brown LC, Yashar S, Chiu MW. Cutaneous side effects of epidermal growth factor receptor inhibitors: clinical presentation, pathogenesis and management. *J Am Acad Dermatol* 2007; 56: 317–326.
- Murillas R, Larcher F, Conti CJ, Santos M, Ullrich A, Jorcano JL. Expression of a dominant negative mutant of epidermal growth factor receptor in the epidermis of transgenic mice elicits striking alterations in hair follicle development and skin structure. *EMBO J* 1995; 14: 5216–5223.
- Molinari E, De Quatrebarbes J, André T, Aractingi S. Cetuximab-induced acne. *Dermatology* 2005; 211: 330–333.
- Pérez-Soler R, Delord JP, Halpern A, Kelly K, Krueger J, Sureda BM et al. HER1/EGFR inhibitor-associated rash: future directions for management and investigation outcomes from the HER1/EGFR inhibitor rash management forum. *Oncologist* 2005; 10: 345–356.
- Micantonio T, Fagnoli MC, Ricevuto E, Ficorella C, Marchetti P, Peris K. Efficacy of treatment with tetracyclines to prevent acneiform eruption secondary to cetuximab therapy. *Arch Dermatol* 2005; 141: 1173–1174.
- Gutzmer R, Werfel T, Mao R, Kapp A, Elsner J. Successful treatment with oral isotretinoin of acneiform skin lesions associated with cetuximab therapy. *Br J Dermatol* 2005; 153: 849–851.
- De Witt CA, Siroy AE, Stone SP. Acneiform eruptions associated with epidermal growth factor receptor-targeted chemotherapy. *J Am Acad Dermatol* 2007; 56: 500–505.