

Wegener's Granulomatosis Mimicking Facial Granulomatous Rosacea: A Separate Subset?

Olivier Dereure¹, Didier Bessis¹, Luc Durand² and Bernard Guillot¹

¹Department of Dermatology, University of Montpellier 1, University Hospital, Hôpital Saint-Eloi, FR-34000 Montpellier; and ²Laboratory of Pathology, University of Montpellier 1, University Hospital, Hôpital Gui de Chauliac, Montpellier, France. E-mail: o-dereure@chu-montpellier.fr
Accepted March 20, 2007.

Sir,

Wegener's granulomatosis (WG) is an aggressive vasculitis that can affect the skin, among other targets such as the kidneys and upper respiratory tract. Recently, Steinhoff et al. (1) reported an unusual and potentially deceitful subset of WG in a 70-year-old patient, featuring initial cutaneous inflammatory centro-facial lesions that closely mimicked papulo-pustular rosacea, but which eventually proved to correspond to WG. We report here a new observation of this atypical presentation, raising the possibility that this clinical pattern is perhaps not exceptional and should be brought to the attention of physicians dealing with red facial lesions.

CASE REPORT

A 63-year-old woman with a history of Klippel-Trenaunay syndrome of the left upper limb and hypothyroidism treated with Levothyrox[®] (Merck Liph Santé, Lyon, France) first presented in July 2005 for evaluation of shiny erythematous plaques of large folds of some months duration. A possible diagnosis of morphea was not supported by biopsies, which mainly displayed non-specific inflammation, although one biopsy on the right thigh showed histiocyte-rich granulomas surrounding necrotic and micro-abscessed areas. Biological investigation revealed a low-level monoclonal IgG kappa paraprotein (total IgG dosage: 8.5 g/l with no significant evolution during the follow-up period) without any suggestion of myeloma according to morphological and biological investigations. Over the next 3 months, the cutaneous lesions of the folds faded spontaneously, but papular and pustular elements highly suggestive of rosacea developed on her nose and cheeks, along with chronic dry cough, and eye and mouth dryness. Topical metronidazole yielded little clinical result, and the facial lesions spread progressively to infiltrated, sometimes ulcerated and necrotic plaques of both cheeks and the right outer edge of the nostril (Fig. 1), while the fold lesions recurred; in the meantime, she had received amoxicillin and clavulanic acid for a left lower lobe pneumonia, but treatment was interrupted after a few days because of cutaneous rash. A second evaluation revealed extravascular necrotizing granuloma on facial biopsies (Winkelmann's granuloma) (Fig. 2), histologically non-specific extensive haemorrhagic crusts and necrosis on nasal endoscopy together with thickening of right maxillary sinus

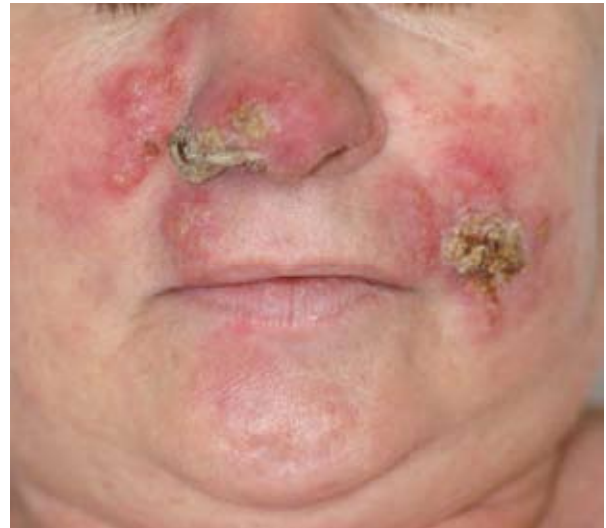

Fig. 1. Infiltrated and ulcerated nodules of the face with necrosis of the outer edge of the nostril.

mucosa and non-specific multiple pleural micronodules on computerized tomography (CT) scan. Tests for auto-antibodies, including anti-cANCA, and for infectious agents (mainly mycobacteria) in lesions and in sputum were repeatedly negative (the last negative cANCA auto-antibodies test was performed in January 2007) apart from the nasal carriage of *S. aureus* identified at initial evaluation. Morphological (CT scan and abdominal ultrasound) and biological (renal function, urine analysis) renal investigations were normal and

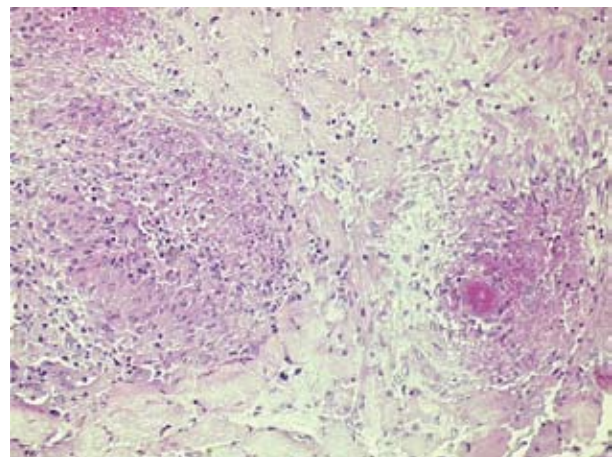


Fig. 2. Histological pattern of ulcerated facial lesions: extravascular necrotizing granuloma.

significant renal involvement was therefore excluded. Despite the absence of anti-cANCA antibodies, already reported in localized subsets of the disease, a diagnosis of WG was considered on the presence of 3 criteria out of 4 and a tentative treatment with trimethoprim-sulphamethoxazole was implemented for a few weeks with poor results. Systemic steroids were then started due to the extension of facial lesions and degradation of general status, at an initial dosage of 1 mg/kg/day. After 6 weeks of full-dosage treatment, the patient experienced marked improvement of infiltration and of nasal erosions, although focal skin ulcerations were still present. The dosage of steroids was then tapered rapidly due to the occurrence of steroid-induced diabetes mellitus requiring treatment with biguanides, but the lesions continued to improve, with complete disappearance of infiltration and ulcerations after 3 months and no relapse when steroids were eventually stopped.

DISCUSSION

WG is a systemic, and usually aggressive, granulomatous vasculitis, mainly involving the lower and upper respiratory tract including the nose, the sinuses and lungs, the kidneys, the joints and the eyes. Skin may also be a target, with various clinical patterns, including papular, vesicular, necrotic, ulcerated or, less characteristically, erythematous lesions (2). Skin lesions may lead to an initial diagnosis of WG on histological grounds, with the presence of a severe leukocytoclastic granulomatous vasculitis or of an extravascular necrotizing granuloma usually considered to be a late consequence of specific vasculitis lesions. Initially, localized forms have been reported on skin, nose and kidney, but progression toward a more aggressive and systemic disease is usual, requiring systemic treatment with steroids and sometimes immunosuppressive agents (3, 4). The presence of cANCA, which is nearly specific for WG, is lacking in about 50% of these localized subsets. The case reported by Steinhoff et al. (1) and the patient described here both fit this pattern perfectly and define a remarkably homogeneous condition featuring cutaneous lesions mainly involving the central facial area and initially highly suggestive of a banal papular and pustular rosacea associated with inflammatory elements of the proximal parts of the limbs (thighs). Additionally, initial biopsies are usually poorly informative with ill-defined granulomatous infiltrates, c-ANCA are absent and these patients display a progressive evolution toward a more specific pattern of extensive nasal ulcerations along with severe

necrotic and ulcerated facial skin lesions and presence of either a granulomatous vasculitis or an histological equivalent, such as extravascular necrotizing granuloma, thus fulfilling relevant criteria of WG as defined by the American College of Rheumatology (5). It can be pointed out that kidney involvement was absent and a haematological background was present in both of these cases (B-cell chronic lymphocytic leukaemia in Steinhoff's report and monoclonal paraprotein of undetermined significance in our patient), but coincidental data cannot be ruled out with so few cases.

Accordingly, we believe that rosacea-like facial lesions must be added to the clinical spectrum of skin lesions occurring during WG, and that this particular pattern might define a specific subset of localized, c-ANCA negative disease at risk of short-term evolution towards a more aggressive form mainly targeting central facial skin, with potentially disfiguring ulcerative and necrotic lesions, rather than internal organs such as the kidney. Clinicians should be aware of this possibility and carefully observe patients with facial lesions suggestive of rosacea when some clinical atypias are present, such as erythematous or nodular lesions on the limbs or limited nasal erosions, the presence of which should be more systematically checked. A systematic swab of the outer edges of nostrils might be advocated in this setting to search for a carriage of *S. aureus*, since there is evidence that chronic nasal presence of *S. aureus* is significantly more frequent in patients with WG than in controls (6).

REFERENCES

1. Steinhoff M, Steinhoff-Georgieva J, Geilen CC, Assaf C. Wegener's granulomatosis presenting with granulomatous facial erythematous papules and plaques mimicking granulomatous rosacea. *Br J Dermatol* 2006; 155: 221–222.
2. Daoud MS, Gibson LE, DeRemee RA, Specks U, el-Azhary RA, Su WP. Cutaneous Wegener's granulomatosis: clinical, histopathologic, and immunopathologic features of thirty patients. *J Am Acad Dermatol* 1994; 31: 605–612.
3. DeRemee RA. Wegener's granulomatosis. *Curr Opin Pulm Med* 1995; 1: 363–367.
4. Pinede L, Ninet J, Duhaut P, Coppere B, Demolombe-Rague S, Girard-Madoux MH, et al. Wegener granulomatosis. Anatomoclinical study. Review of the literature. *Ann Med Interne (Paris)* 1995; 146: 339–364.
5. Leavitt RY, Fauci AS, Bloch DA, Michel BA, Hunder GG, Arend WP, et al. The American College of Rheumatology 1990 criteria for the classification of Wegener's granulomatosis. *Arthritis Rheum* 1990; 33: 1101–1107.
6. Popa ER, Stegeman CA, Kallenberg CG, Tervaert JW. Staphylococcus aureus and Wegener's granulomatosis. *Arthritis Res* 2002; 4: 77–79.