

Grover's Disease in a Patient Undergoing Peritoneal Dialysis with Resolution After Renal Transplant

Beatriz González-Sixto, Elena Rosón, Carlos De la Torre, Ignacio García-Doval and Manuel Cruces

Department of Dermatology, Complejo Hospitalario de Pontevedra, C/ Loureiro Crespo 2, ES-36001 Pontevedra, Spain. E-mail: bgonsix@aedv.es

Accepted March 23, 2007.

Sir,

Cutaneous manifestations are frequently found in patients with chronic renal failure. They can be classified as specific disorders (e.g. perforating disorders, metastatic calcification, bullous dermatosis) or non-specific disorders (e.g. skin colour changes, pruritus, elastosis, equimosis, xerosis, uraemic frost, half and half nails).

We report here an unusual association between an acantholytic disorder and renal failure.

CASE REPORT

A 62-year-old man with chronic renal failure secondary to chronic glomerulonephritis and on maintenance peritoneal dialysis for the past 3 years was referred to our department for evaluation of a pruritic eruption on the back that had appeared 3–4 months prior to consultation.

His medical history disclosed childhood tuberculosis, hypercholesterolaemia and arterial hypertension. He had been treated with lovastatin, doxazosin and omeprazole. He did not report any febrile status or bed-rest in the preceding months.

Physical examination revealed erythematous and excoriated papules located on the back (Fig. 1). A skin biopsy punch was made. Microscopic examination showed epidermal acanthosis, suprabasal clefts and focal acantholysis with dyskeratosis (Fig. 2). In the dermis there was a lymphocytic infiltrate. The histological findings resembled Darier's disease. Two months after consultation the patient underwent renal transplantation, with resolution of lesions one month later. After one year of follow-up, the patient had not developed any new lesions.

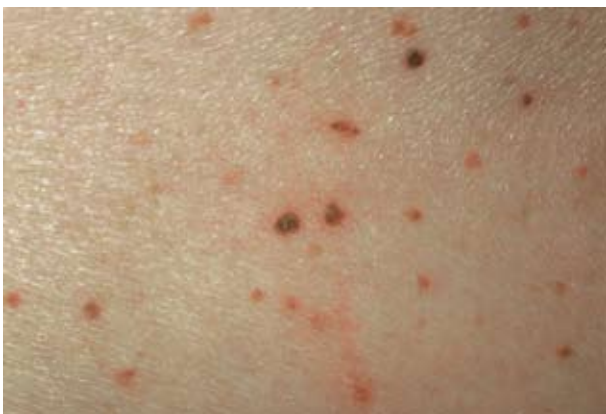

Fig. 1. Multiple erythematous papules on the back.

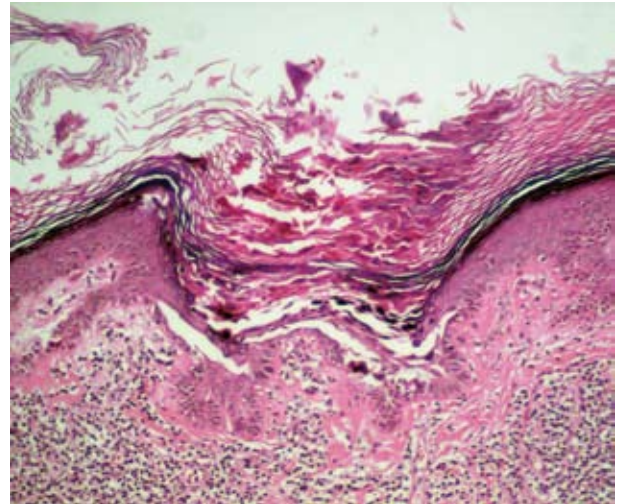


Fig. 2. Suprabasal clefts, focal acantholysis and dyskeratosis with lymphocytic infiltrate in the dermis (H&E $\times 200$).

DISCUSSION

Transient acantholytic dermatosis (TAD) was first described in 1970 by Grover as a transient papulovesicular eruption that appears commonly on the chest, back and thighs (1). Generally the dermatosis is self-limited and resolves within weeks or months, but in some cases may be persistent or recurrent. Microscopically, 4 different patterns can be observed: Darier-like, Hailey-Hailey-like, pemphigus vulgaris-like and spongiotic-acantholytic pattern.

The cause of TAD is unknown. TAD has been associated with excessive sun exposure, heat, fever and sweating, drugs, immunodeficiency conditions, neoplasms (haematological, renal, genitourinary and others) and with several dermatosis (asteatotic eczema, allergic contact dermatitis, atopic dermatitis) (1).

The association of persistent acantholytic dermatosis with chronic renal failure and haemodialysis has been reported in at least 6 cases (2–4). To our knowledge TAD associated with peritoneal dialysis has not been reported previously. Lesions in dialysis patients were persistent, except for one case that resolved after renal transplantation (3) as in our case. Decreased sweating, xerosis, obstruction of sweat ducts and unknown factors related to dialysis might play a role in the development of TAD in patients with chronic renal failure. Three of the 6 previously reported patients had received a renal

allograft without development of Grover's disease until they resumed haemodialysis due to graft failure. Although Boutli et al. (5) described a case of TAD in a patient who had received a renal transplant several years before, in most reports TAD seems to be associated with dialysis, and not with renal transplant. It is likely that, in this case, renal failure, the transplant, or immunosuppressive treatment could be triggers for development of TAD.

We conclude that Grover's disease should be considered in the differential diagnosis of skin diseases appearing in patients with chronic renal failure and receiving haemodialysis or peritoneal dialysis.

REFERENCES

1. Parsons JM. Transient acantholytic dermatosis (Grover's disease): a global perspective. *J Am Acad Dermatol* 1996; 35: 653–666.
2. Chua SH, Yiam YC. Acantholytic dermatosis in chronic renal failure. *Int J Dermatol* 1997; 36: 200–202.
3. Casanova JM, Pujol RM, Taberner R, Egado R, Fernández E, Alomar AI. Grover's disease in patients with chronic renal failure receiving hemodialysis: clinicopathologic review of 4 cases. *J Am Acad Dermatol* 1999; 41: 1029–1033.
4. Moderer M, Korting HC, Yazdi A. Grover's disease following hemodialysis in patient with renal failure. *J Dtsch Dermatol Ges* 2004; 2: 203–205.
5. Boutli F, Voyatzi M, Lefaki I, Chaidemenos G, Kanitakis J. Transient acantholytic dermatosis (Grover's disease) in a renal transplant patient. *J Dermatol* 2006; 3: 178–181.