

## Periorbital Ecchymoses Are Not Pathognomonic of the Light-chain Type of Amyloidosis

Olivier Outteryck<sup>1</sup>, Tanya Stojkovic<sup>1</sup>, David Launay<sup>2</sup>, Brigitte Meignie-Ramon<sup>1</sup> and Patrick Vermersch<sup>1</sup>

Departments of <sup>1</sup>Neurology and <sup>2</sup>Internal Medicine, University Hospital of Lille, FR-59037 Lille, France. E-mail: olivier\_outteryck@hotmail.com

Accepted March 23, 2007.

Sir,

Up to now, periorbital ecchymoses have been considered virtually pathognomonic of acquired monoclonal immunoglobulin (Ig) light-chain (AL) amyloidosis. (1) We report here a case of transthyretin (TTR) familial amyloid polyneuropathy that disproves the absolute specificity of this clinical sign.

### CASE REPORT

A 52-year-old man presented with a progressive 16-month course of severe sensorimotor polyneuropathy. He had no personal or familial medical past history. Clinical manifestations appeared in July 2003 and were characterized by decreased sensation and painful paraesthesia of the upper extremities, followed 4 months later by distal weakness. Then, decreased sensation, painful paraesthesia and distal weakness of the lower limbs progressively appeared. Alternating diarrhoea and constipation, Raynaud's syndrome and erectile dysfunction were noted at the same time. The patient also complained of effort dyspnoea and orthopnoea. Electromyography demonstrated a severe axonal sensorimotor polyneuropathy involving all 4 limbs. Investigations revealed a normal blood count and serum glucose, creatinine, and urea, electrolytes and liver function test. There were no inflammatory biological markers. Classical causes of axonal polyneuropathy, such as alcoholism, vitamin deficiency, diabetes mellitus, dysthyroidea and auto-immune diseases, were ruled out. The suspected dysautonomia was confirmed by an abnormal heart-rate variability on electrophysiological tests. Echocardiography showed thickened ventricular walls with a granular sparkling appearance and impaired diastolic dysfunction. The patient developed periorbital and scleral ecchymoses after vomiting (Fig. 1). Since periorbital ecchymoses are classically considered as pathognomonic of AL amyloidosis, we performed a salivary gland biopsy and a sural nerve biopsy. Amyloid deposits were observed in both figures, but immunofluorescence with anti-light-chain (lambda or kappa) antibodies did not reveal any immunoreactivity. There was no evidence of monoclonal gammopathy in spite of an exhaustive work-up comprising blood and urinary immunoelectrophoresis, nephelometric assay of light chain in serum and an osteomedullary biopsy. Since the AL type of amyloidosis was not confirmed, a molecular analysis of the TTR gene was performed and revealed a heterozygous Ser77Tyr mutation, re-

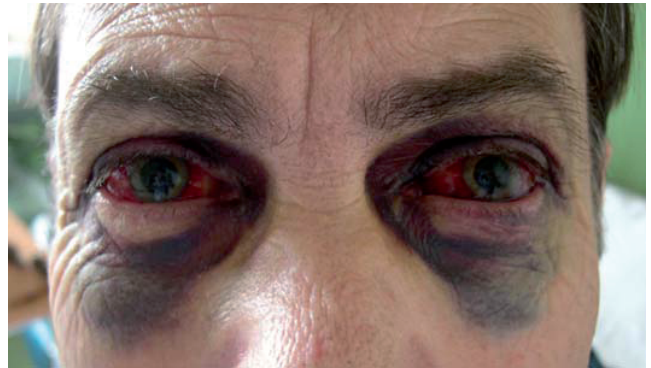

Fig. 1. Periorbital and scleral ecchymoses in a patient with transthyretin (TTR) familial amyloid polyneuropathy.

sulting in a diagnosis of familial TTR type amyloid polyneuropathy. Immunohistochemistry confirmed the transthyretin nature of the amyloid deposits (Fig. 2).

### DISCUSSION

We describe here a 52-year-old patient who, over a period of 16 months, developed an axonal sensorimotor polyneuropathy with autonomic dysfunction, hypertrophic and concentric cardiomyopathy and periorbital ecchymoses. Gene analysis revealed a heterozygous Ser77Tyr substitution in the TTR gene and immunostaining confirmed the TTR nature of the amyloid deposits in the tissue, whereas the clinical presentation strongly suggested AL type of amyloidosis. Indeed, periorbital ecchymoses are usually considered as virtually pathognomonic of AL amyloidosis (1). Periorbital ecchymoses are due to the fragility of capillary blood vessels induced by amyloid deposits. It may be a spontaneous phenomenon, but most often occurs after physical activity or trivial trauma (2) such as coughing or vomiting. They have already been described in different circumstances: in skull trauma; in a patient who died after attempted cardiopulmonary resuscitation (3); in cerebral vein thrombosis (4); and in migraine. (5) Various cutaneous manifestations may occur during AL amyloidosis, including purpura (frequently periorbital), nail dystrophy, skin thickening and pruritus (2). In 1998, Dubrey et al. (2) reviewed the clinical features of 232 patients with AL cardiac amyloidosis. Ecchymoses were present in 40.9% of patients and periorbital purpura in 12.5%. Ocular manifestations in AL amyloidosis include sicca syndrome (2) and ophthalmoplegia associated with biopsy-proven amy-

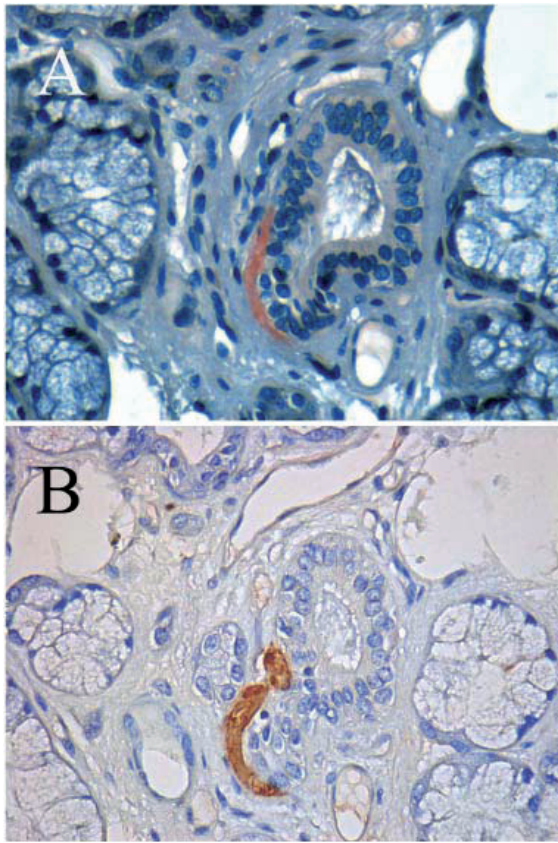


Fig. 2. (A) Periductal amyloid deposits stained by Congo red in labial salivary glands biopsy, and (B) positive immunohistochemical staining for transthyretin protein of the same deposit; bar=50  $\mu$ m. Polyclonal rabbit anti-human transthyretin antibody (Dakocytomation, Glostrup, Denmark) used at 1:500 dilution.

loid infiltration of extra-ocular muscles. (6) In 2002, Lachmann et al. (1) studied 350 patients with systemic amyloidosis and concluded that a genetic cause should be sought in patients with systemic amyloidosis in whom confirmation of the AL type cannot be obtained, as in our case. In the same study, amyloidogenic mutations were present in 34 of the 350 patients with systemic amyloidosis in whom the clinical and laboratory findings had suggested a diagnosis of AL type of the disorder. In our patient, the only argument in favour of AL amyloidosis was the presence of periorbital ecchymoses. However, no circulating paraproteins, urinary light chains or immunohistochemical staining of amyloid deposits with anti-light-chain (lambda or kappa) antibodies were detected.

Cutaneous manifestations occurring during TTR amyloidosis, such as xerosis, ulcers, trauma or burn lesions

(7), seem to be the consequence of the involvement of small fibres and are not specific of TTR amyloidosis. Ocular manifestations in hereditary TTR amyloid polyneuropathy include vitreous opacities, glaucoma, papillary disorders, keratoconjunctivitis sicca (8) and conjunctival and retinal microangiopathy (9).

As far as we are aware, periorbital ecchymoses have previously been reported only once in TTR familial amyloid polyneuropathy. In 2005, Kim et al. (10) described an aggressive form of familial amyloid polyneuropathy, caused by a heterozygous Glu54Gly mutation in the TTR gene, in which a spontaneous bruise arose on both periorbital areas at onset. However, the author did not emphasize the interest of this sign as a feature of TTR familial amyloid polyneuropathy.

#### ACKNOWLEDGEMENT

We thank Dr G. Bassez (départment de Pathologie, Hôpital Henri Mondor, Créteil, France) for immunohistochemistry and fruitful comments on the manuscript.

#### REFERENCES

1. Lachmann HJ, Booth DR, Booth SE, Bybee A, Gilbertson JA, Gillmore JD, et al. Misdiagnosis of hereditary amyloidosis as AL (primary) amyloidosis. *N Engl J Med* 2002; 346: 1786–1791.
2. Dubrey SW, Cha K, Anderson J, Chamathi B, Reisinger J, Skinner M, Falk RH. The clinical features of immunoglobulin light-chain (AL) amyloidosis with heart involvement. *Q J Med* 1998; 91: 141–157.
3. Hood I, Ryan D, Spitz WU. Resuscitation and petechiae. *Am J Forensic Med Pathol* 1988; 9: 35–37.
4. Hadjikitoutis S, Carroll C, Plant GT. *J Neurol Neurosurg Psychiatry* 2004; 75: 1192–1193.
5. DeBroff BM, Sprierings EL. Migraine associated with periorbital ecchymosis. *Headache* 1990; 30: 260–263.
6. Raflo GT, Farrell TA, Sioussat RS. Complete ophthalmoplegia secondary to amyloidosis associated with multiple myeloma. *Am J Ophthalmol* 1981; 92: 221–224.
7. Rocha N, Velho G, Horta M, Martins A, Massa A. Cutaneous manifestations of familial amyloidotic polyneuropathy. *J Eur Acad Dermatol Venereol* 2005; 19: 605–607.
8. Ando Y, Nakamura M, Araki S. Transthyretin-related familial amyloidotic polyneuropathy. *Arch Neurol* 2005; 62: 1057–1062.
9. Ando E, Ando Y, Maruoka S, Sakai Y, Watanabe S, Yamashita R, et al. Ocular microangiopathy in familial amyloidotic polyneuropathy, type I. *Graefes Arch Clin Exp Ophthalmol* 1992; 230: 1–5.
10. Kim HS, Kim SM, Kang SW, Jung SC, Lee KS, Kim TS, Choi YC. An aggressive form of familial amyloid polyneuropathy caused by a Glu54Gly mutation in the transthyretin gene. *Eur J Neurol* 2005; 12: 657–659.