

## CLINICAL REPORT

# Ulcerous Lesions Disclosing Cutaneous Infection with *Fusarium solani*

Lidia PÉREZ-PÉREZ, Manuel PEREIRO Jr, Dolores SÁNCHEZ-AGUILAR and Jaime TORIBIO  
Department of Dermatology, Complejo Hospitalario Universitario, Faculty of Medicine, Santiago de Compostela, Spain

***Fusarium spp.* are emergent opportunistic moulds capable of producing life-threatening diseases, usually in immunocompromised hosts. When they infect immunocompetent patients, they usually cause localized diseases. We describe here a case of cutaneous fusariosis in a patient with a medical history of diabetes mellitus and non-Hodgkin's lymphoma who presented with two painful lesions on her left leg. The diagnosis was made on the basis of histopathological findings and skin biopsy culture. The lesions resolved after treatment with oral itraconazole. Cutaneous fusariosis manifests clinically as lesions that can be grouped into a few clinical patterns, and should always be considered in the differential diagnosis of necrotic cutaneous lesions. Key words: *Fusarium*; hyalohyphomycoses; cutaneous fusariosis; immunocompromised host.**

(Accepted February 20, 2007.)

Acta Derm Venereol 2007; 87: 422–424.

Lidia-Comba Pérez-Pérez, Department of Dermatology, Faculty of Medicine, C/ San Francisco s/n, ES-15782, Santiago de Compostela, Spain. E-mail: mejaime@usc.es

Hyalohyphomycoses are infections caused by fungus that invade a variety of tissues and form branched hyaline hyphae. The genus *Fusarium* and *Penicillium spp.*, *Scedosporium spp.*, *Acremonium spp.*, *Paecilomyces spp.*, *Aspergillus spp.* and *Scopulariopsis spp.* are included in this group (1–3). They are considered emerging opportunistic pathogens capable of producing severe and disseminated infections with a high mortality rate, mainly in immunocompromised hosts. Although the skin is the organ most frequently affected and it is also one of the most common portals of entry, *Fusarium spp.* has also been reported to infect many other tissues (1, 2). Due to both their potential aggressiveness and their unpredictable response to antifungal therapy, an early diagnosis substantially modifies the patient's prognosis. We report here a rare case of cutaneous infection with *F. solani*.

## CASE REPORT

A 68-year-old woman with a medical history of hypertension, diabetes mellitus and non-Hodgkin's lym-

phoma (at that time in clinical remission) presented with two painful, ulcerous, well-delimited, rounded lesions, measuring 2.5×2.5 cm and 2×2 cm, respectively, that had developed over the previous month on the anterior and external aspects of her left leg. Both lesions had a black, necrotic centre and erythematous-violaceous borders with an inflammatory halo (Fig. 1). Neither interdigital intertrigo nor signs of onychomycosis were observed. The patient did not present fever or any other systemic symptoms. She denied any injury to the affected limb. Physical examination was normal and no lymphadenopathies were noted.

Laboratory investigations revealed glucose 400 mg/dl and a slight elevation of glutamic oxalacetic transaminase and glutamic pyruvic transaminase levels. A blood count was within normal ranges. Tests for anti-nuclear and anti-neutrophil cytoplasmic antibodies, cryoglobulins and cryoagglutinins were negative. Serological tests for HIV, hepatitis C and hepatitis B viruses, and Paul-Bunnell test were negative.

Histological study of a skin sample revealed a marked epidermal and dermal necrosis with an intense inflammatory infiltrate mainly comprised of neutrophils. Many hyaline-branched septated hyphae were seen on the surface of the lesion and extending deeply into the dermis, with both haematoxylin-eosin (H&E) and periodic acid-Schiff (PAS) staining (Fig. 2).

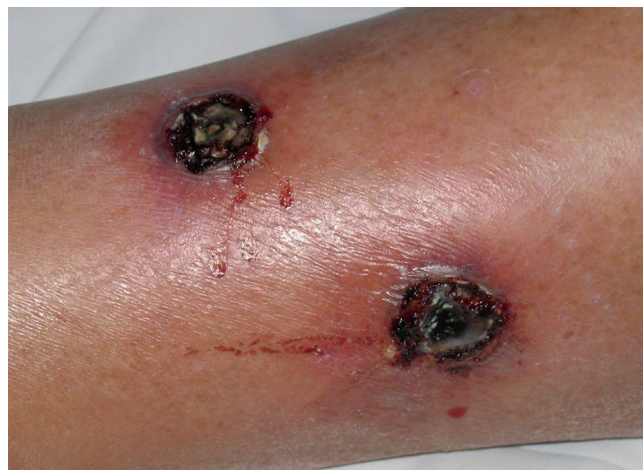

Fig. 1. Two well-delimited, rounded, ulcerous lesions with necrotic centres and erythematous borders on the anterior aspect of the left leg.

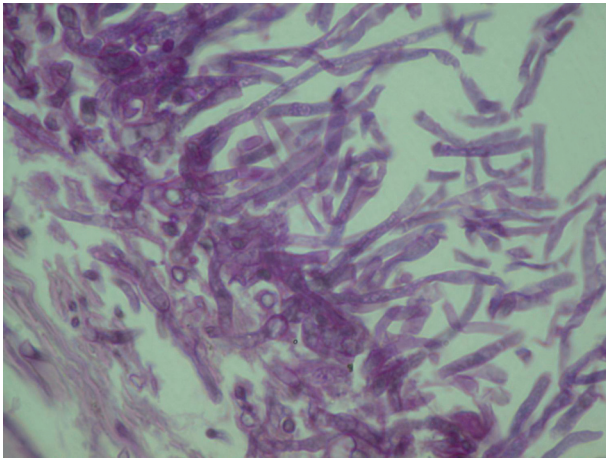


Fig. 2. Hyaline branched septated hyphae extending deeply in the dermis (periodic acid-Schiff (PAS) stain  $\times 400$ ).

A biopsy sample was cultured on Sabouraud's agar and subsequently incubated at 25°C and 37°C for 14 and 21 days, respectively. The cultures yielded colonies that were white to cream in colour with a floccose aerial mycelium. Slide cultures on Sabouraud's agar revealed single- or two-celled, oval microconidia, 8–9 $\times$ 2–3  $\mu$ m in size, sometimes grouped in verticilliums produced from elongated lateral phialides. We observed a few intercalary, rough-walled, 6–9  $\mu$ m chlamydospores. On the basis of these findings, the strain was identified as *F. solani* (Mart.) Sacc. (4).

After stopping cloxacillin, which the patient had been prescribed empirically, she started oral itraconazole 200 mg daily, with a progressive good clinical response. No new lesions have been observed since antifungal therapy was started.

## DISCUSSION

The genus *Fusarium* comprises saprophytic microorganisms that are widely distributed in the soil, water and vegetables (5–7). In human hosts *Fusarium spp.* can cause localized and disseminated infections, principally in immunocompromised patients (8–11). The species most commonly isolated are: *F. solani*, *F. moniliforme* (*F. verticilloides*), *F. anthophilum*, *F. oxysporum* and *F. proliferatum* (1). *F. semitecum*, *F. napiforme*, *F. dimerum*, *F. equiseti*, *F. anthophilum*, *F. chlamydosporum* and *F. lichenicola* have been rarely isolated (1, 8). *F. solani* accounts for up to 65% of all the infections with *Fusarium spp.* (12).

The clinical picture in patients infected with *Fusarium spp.* depends primarily on the integrity of their immune system. Thus, patients with some degree of immunosuppression are at risk of developing severe disseminated infections with high morbidity and mortality, while immunocompetent hosts usually develop localized infections.

Haematological and solid organ malignancies, organ transplantations, graft-versus-host disease, immunosuppressive drugs, AIDS and Epstein-Barr virus infection are all risk factors for developing a disseminated infection with *Fusarium spp.* (2, 13). Other conditions, such as chronic renal failure and burns, might determine a high mortality rate (14). Diabetes mellitus and corticosteroids (13) are not definitely recognized as true risk factors for fusariosis. Pereiro et al. (15) suggested that cryotherapy might have promoted cutaneous lesions by *F. oxysporum* in a diabetic patient.

The portals of entry are usually the skin, the respiratory tract and the gastrointestinal tract. Some prosthetic materials, such as intravenous catheters, peritoneal catheters for dialysis (5, 8, 10, 16), nasogastric tubes (16) and contact lenses (2) can be reservoirs for *Fusarium spp.*

A few authors have attempted to classify cutaneous fusarioses (11, 13). However, the descriptions available in the literature are bizarre and obscure. Bodey et al. (12) divided cutaneous lesions according to their morphology into red/grey macules, red/grey papules, red/grey macules or papules with central eschar/necrosis, purpuric papules, pustules and subcutaneous nodules. Sampathkumar et al. (11) suggested classifying the cutaneous lesions by *Fusarium spp.* into three groups: violaceous nodules with central necrosis, ecthyma gangrenosum-like lesions and target lesions. Venneward & Wollina (13) described three forms of fusariosis: an exogenous superficial form, including interdigital intertrigo and paronychia, an exogenous unilocular form of traumatic origin and an endogenous multilocular form.

We consider that the wide variety of cutaneous lesions described in the literature may be the result of using different terms to describe similar lesions, such as purpuric papules instead of palpable purpura, and that the spectrum of cutaneous lesions caused by *Fusarium spp.* includes only a few main clinical patterns; tubercles (isolated, forming plaques or distributed in a sporotrichoid pattern), ulcers (including "ecthyma gangrenosum-like" lesions), and purpuric or necrotic lesions (localized and disseminated, including palpable purpura).

*Fusarium spp.* can also infect the nails, causing melanonychia and onychomycosis (1, 17) and rarely causes interdigital intertrigo, abscesses and mycetoma (2, 18).

Differential diagnosis should be made with other fungal infections, such as mucormycosis and aspergillosis (12), drug reactions, vasculitis, ecthyma simplex, ecthyma gangrenosum, pyoderma gangrenosum, anthrax and septic emboli.

Due to the increasing number of immunosuppressed patients, infection with *Fusarium spp.* will probably become an important medical problem. In immunosuppressed hosts, especially, an accurate and prompt diagnosis is of relevance for the patient's prognosis.

and is needed before a specific and effective treatment can be started.

Given the fact that the skin is the organ most frequently affected, this fungus is of special interest to dermatologists, as in most cases the cutaneous lesions constitute an important physical clue to the clinical diagnosis.

## REFERENCES

1. Dignani MC, Anaissie E. Human fusariosis. *Clin Microbiol Infect* 2004; 10: 67–75.
2. Gupta AK, Baran R, Summerbell RC. Fusarium infections of the skin. *Curr Opin Infect Dis* 2000; 13: 121–128.
3. Melcher GP, McGough DA, Fothergill AW, Norris C, Rinaldi M. Disseminated hyalohyphomycosis caused by a novel human pathogen, *Fusarium napiforme*. *J Clin Microbiol* 1993; 31: 1461–1467.
4. De Hoog GS, Guarro J, Gené J, Figueras MJ, editors. Atlas of clinical fungi. 2nd edn. Centraalbureau voor Schimmeltcultures/Universitat Rovira i Virgili, Reus, Spain, 2000: 681–705.
5. Pereiro M Jr, Labandeira J, Toribio J. Plantar hyperkeratosis due to *Fusarium verticilloides* in a patient with malignancy. *Clin Exp Dermatol* 1999; 24: 175–178.
6. Chade ME, Mereles BE, Medvedeff MG, Vedoya MC. Micosis subcutánea postraumática por *Fusarium solani*. *Rev Iberoam Micol* 2003; 20: 29–30.
7. Nelson PE, Dignani MC, Anaissie EJ. Taxonomy, biology and clinical aspects of *Fusarium* species. *Clin Microbiol Rev* 1994; 7: 479–504.
8. Boutati EI, Anaissie EJ. *Fusarium*, a significant emerging pathogen in patients with hematologic malignancy: ten years' experience at a cancer center and implications for management. *Blood* 1997; 90: 999–1008.
9. Nucci M, Anaissie E. Cutaneous infection by *Fusarium* species in healthy and immunocompromised hosts: implications for diagnosis and management. *Clin Infect Dis* 2002; 35: 909–920.
10. Cocuroccia B, Gaido J, Gubinelli E, Annessi G, Giromoloni G. Localized cutaneous hyalohyphomycosis caused by a *Fusarium* species infection in a renal transplant patient. *J Clin Microbiol* 2003; 41: 905–907.
11. Sampathkumar P, Paya CV. *Fusarium* infection after solid-organ transplantation. *Clin Infect Dis* 2001; 32: 1237–1240.
12. Bodey GP, Boktour M, Mays S, Duvic M, Kontoyiannis D, Hachem R, Raad J. Skin lesions associated with *Fusarium* infection. *J Am Acad Dermatol* 2002; 47: 659–666.
13. Vennwald I, Wollina U. Cutaneous infections due to opportunistic molds: uncommon presentations. *Clin Dermatol* 2005; 23: 565–571.
14. Nir-Paz R, Strahilevitz J, Shapiro M, Goldschmied-Reouven A, Yarden O, Block C, Polacheck I. Clinical and epidemiological aspects of infections caused by *Fusarium* species: a collaborative study from Israel. *J Clin Microbiol* 2004; 42: 3456–3461.
15. Pereiro M Jr, Abalde MT, Zulaica A, Caeiro JL, Flórez A, Peteiro C, Toribio J. Chronic infection due to *Fusarium oxysporum* mimicking lupus vulgaris: case report and review of cutaneous involvement in fusariosis. *Acta Derm Venereol* 2001; 81: 51–53.
16. Albiseti M, Lauener RP, Gungor T, Schär G, Niggli FK, Nadal D. Disseminated *Fusarium oxysporum* infection in hemophagocytic lymphohistiocytosis. *Infection* 2004; 32: 364–366.
17. Pereiro Jr M, Pereiro E, Toribio J, Pereiro-Miguens M. Superficial white toenail onychomycosis due to *Fusarium oxysporum*. A case report and review of the literature. *J Mycol Med* 1997; 7: 219–212.
18. Yera H, Bougnoux ME, Jeanrot C, Baixench MT, De Pinieux G, Dupuoy-Camet J. Mycetoma of the foot caused by *Fusarium solani*: identification of the etiologic agent by DNA sequencing. *J Clin Microbiol* 2003; 41: 1805–1808.