

## Bullous Lesions at Polyethylene Glycol Interferon- $\alpha$ -2a Inoculation Site in a Hepatitis C Virus-infected Subject

M. Antonietta Montesu, Valentina Siddi, Rosanna Satta, Caterina Pirodda and Francesca Cottoni

Department of Dermatology, University of Sassari, IT-07100 Sassari, Italy. E-mail: fcottoni@uniss.it

Accepted February 5, 2007.

Sir,

The recent introduction of polyethylene glycol interferon (PEG-IFN) for treatment of hepatitis C virus (HCV) has led to reports of both widespread and localized dermatological manifestations as side-effects. Widespread manifestations comprise hair loss, pruritus, generalized eczema, hyperpigmentation tongue, vitiligo and cutaneous sarcoidosis (1–4). Localized manifestations include cutaneous ulcerations and cutaneous local necrosis at the inoculation site, with both non-pegylated IFN (5) and PEG-IFN- $\alpha$ -2b (6, 7).

We report here a case of bullous lesion at the inoculation site of PEG-IFN- $\alpha$ -2a in a patient with chronic HCV-correlated hepatopathy.

### CASE REPORT

The patient, a 53-year-old woman, was diagnosed with chronic HCV in February 1998. From April 2004, she had undergone PEG-IFN- $\alpha$ -2a treatment by injection with weekly doses of 180  $\mu$ g. The patient was also given ribavirin orally at 1200 mg daily. In July of the same year, the patient presented with rounded, slightly infiltrated erythematous patches, approximately 3 cm in diameter, at the PEG-IFN- $\alpha$ -2a inoculation site, at the subdeltoid level on both arms. After a few days these manifested bullous detachment (Fig. 1). The lesions were asymptomatic and the patient presented no other skin manifestations. Skin biopsy showed a subepidermal bulla with fibrinous content, oedema and lymphocytic

and neutrophilic infiltrates in the papillar derma (Fig. 2). PEG-IFN- $\alpha$ -2a treatment was suspended and topical mometasone furoate treatment initiated. Clinical improvement was achieved after a few weeks and complete regression of the erythematous-bullous manifestations occurred after approximately one month.

### DISCUSSION

Combination therapy with interferon and ribavirin for chronic hepatitis C has become increasingly effective, and the introduction of PEG-IFN- $\alpha$  in the treatment of chronic HCV has determined an increase in the pharmacokinetic properties of IFN and, consequently, in its antiviral activity.

There are two forms of PEG-IFN- $\alpha$ : PEG-IFN- $\alpha$ -2a and PEG-IFN- $\alpha$ -2b. Peg-IFN- $\alpha$ -2a is a bulky branched molecule with a molecular mass of 40kD as compared with Peg-IFN- $\alpha$ -2b which is a linear molecule with a molecular mass of 12kD. As a consequence, PEG-IFN- $\alpha$ -2a possesses a greater hemilife and sustains therapeutic levels in the plasma for prolonged periods. This means that PEG-IFN- $\alpha$ -2a alone, or in combination with ribavirin, improves sustained virological responses. Furthermore, therapy with PEG-IFN- $\alpha$ -2a plus ribavirin is associated with better health-related quality of life, because it is associated with significantly less bodily pain, more energy, less disabling fatigue, and fewer limitations in social functioning during the treatment (8).

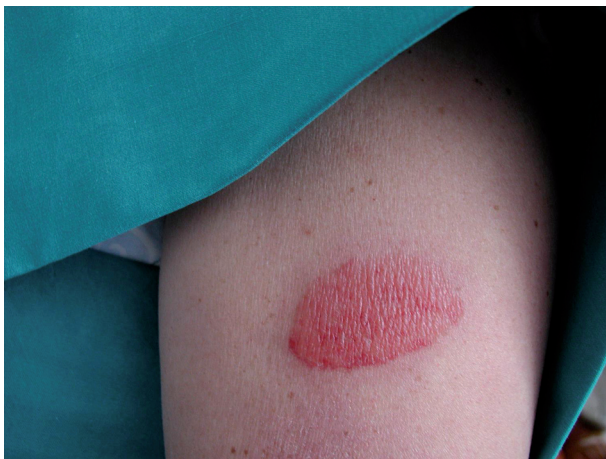

Fig. 1. Intensely erythematous lesion with an appreciable violet peripheral border and bullous detachment.

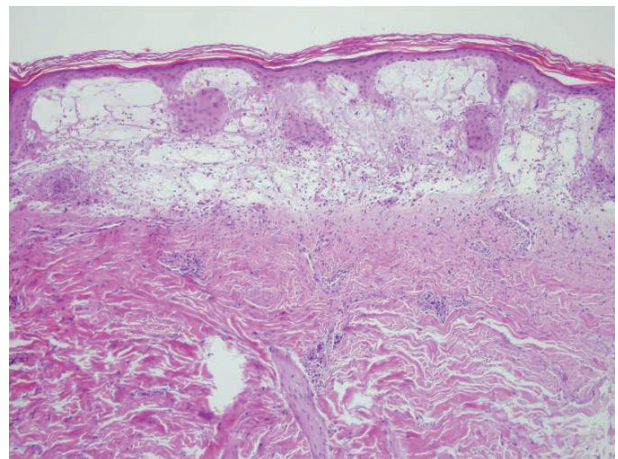


Fig. 2. Subepidermal bulla with fibrin accumulation and lymphocytic and neutrophilic granulocytic inflammatory infiltrate.

Dermatological side-effects of PEG-IFN- $\alpha$ -2a reported in the literature comprise only 2 cases of widespread cutaneous manifestation, associated with a localized reaction, and characterized by oedematous erythematous plaques, which were highly exudative, at the injection site (9, 10).

Our case, on the other hand, presented erythematous infiltrated lesions at the injection site, with successive bullous evolution and no other cutaneous manifestations elsewhere on the body. These clinical characteristics, associated with the histology, which revealed a subepidermic bulla and dermopapillary lymphogranulocytic infiltrate without necrosis, vasculitis or vascular microthrombi, leads us to suggest direct toxic action as the cause of the manifestation.

This case is of interest because it is the first to be reported of solely localized cutaneous manifestation with PEG-IFN- $\alpha$ -2a. Its histological characteristics differ from those reported for PEG-IFN- $\alpha$ -2b, in that no vasculitic or necrotic aspects were present. To conclude, it would seem that pegylated IFN determines a wide range of clinical and histological manifestations, which, as yet, are not fully characterized.

## REFERENCES

1. Cottoni F, Bolognini S, Deplano A, Garrucciu G, Manzoni NM, Careddu GF, et al. Skin reaction in antiviral therapy for chronic hepatitis C: a role for polyethylene glycol Interferon. *Acta Derm Venereol* 2004; 84: 120–123.
2. Chang LW, Liranzo M, Bergfeld WF. Cutaneous side effects associated with interferon-alpha therapy: a review. *Cutis* 1995; 56: 144.
3. Gurguta C, Kauer C, Bergholz U, Formann E, Steindl-Munda P, Ferenci P. Tongue and skin hyperpigmentation during PEG-interferon-alpha/ribavirin therapy in dark-skinned non Caucasian patients with chronic hepatitis C. *Am J Gastroenterol* 2006; 101: 197–198.
4. Tomasiewicz K, Modrzewska R, Semczuk G. Vitiligo associated with pegylated interferon and ribavirin treatment of patients with chronic hepatitis C: a case report. *Adv Ther* 2006; 23: 139–142.
5. Weinberg JM, Wolfe JT, Sood S, Saruk M, Rook AH, Spiers EM. Cutaneous necrosis associated with recombinant interferon. *Acta Derm Venereol* 1997; 77: 146–148.
6. Sparsa A, Loustaud-Ratti V, Alain S, Liozou E, Bedane C, Vidal E. Skin necrosis after injection of PEG-Interferon  $\alpha$ 2b in an HCV-infected patient. *Acta Derm Venereol* 2004; 84: 415–416.
7. Dalmau J, Pimentel CL, Puig L, Peramiquet L, Roé E, Alomar AL. Cutaneous necrosis after injection of polyethylene glycol-modified interferon alfa. *J Am Acad Dermatol* 2005; 53: 62–66.
8. Hassanein T, Cooksley G, Sulkowski M, Smith C, Marinos G, Lai MY, et al. The impact of peginterferon alfa-2a plus ribavirin combination therapy on health-related quality of life in chronic hepatitis C. *J Hepatol*. 2004; 40: 675–681.
9. Kawada K, Maeda N, Kobayashi S, Sowa J, Tsuruta D, Kawada N. Injection site with generalized rash caused by pegylated interferon alpha 2a injection. *Dermatology* 2006; 212: 82–83.
10. Ruiz de Casas A, Garcia-Bravo B, Camacho F. Generalized eczema secondary to combined treatment with peginterferon alfa-2a and ribavirin in a patient with chronic hepatitis from the hepatitis C virus. *Actas Dermosifiliogr* 2005; 96: 122–123.