

Chronic Urticaria and Mild Arthritis Associated with Autoimmune Thyroid Disease: Successful Treatment with L-Thyroxine

Marcin Milchert, Jacek Fliciński, Lidia Ostanek and Marek Brzosko*

Department of Rheumatology, Pomeranian Medical University, Ul. Unii Lubelskiej 1, PL-71 – 252 Szczecin, Poland. *E-mail: brzoskom@pam.szczecin.pl
Accepted December 21, 2006.

Sir,

Some cases of chronic urticaria, regarded so far as idiopathic, are in fact of autoimmune origin (1). Autoimmune thyroid disease (ATD) is characterized by the presence of anti-thyroid antibodies. Association of chronic urticaria and ATD is well known. Most studies have found a 15–30% prevalence of anti-thyroid antibodies in patients with chronic urticaria (2, 3). There have been some reports of successful treatment with L-thyroxine of either arthritis (4, 5) or autoimmune urticaria (1, 3) associated with ATD, as well as in euthyroid patients (3–5).

CASE REPORT

A 33-year-old man with chronic urticaria without angioedema was admitted to our department complaining of severe urticaria, with large confluent areas of wheals (Fig. 1), lasting for 5 years, intense pruritus, intermittent fever over 38°C, and joint pain involving mainly the knees and wrist joints. Previous treatment with different elimination diets, and H1-antihistamines in standard and increased dosage had been unsuccessful.

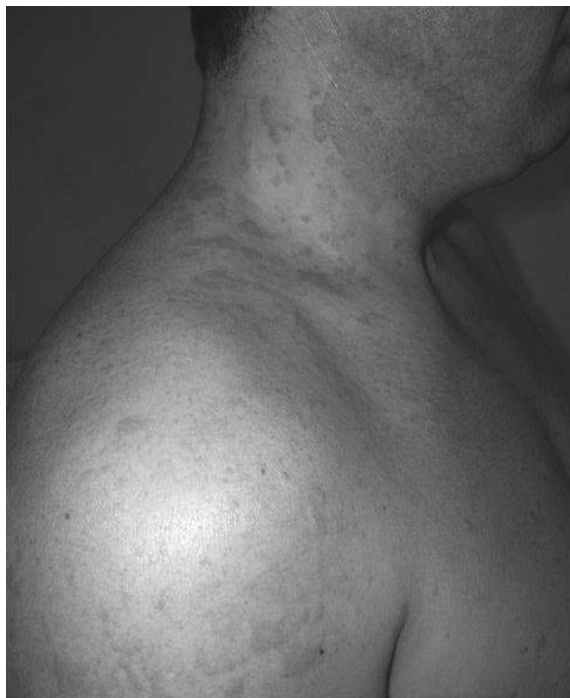

Fig. 1. Urticarial rash.

He was also treated unsuccessfully with the following combination of different H1 and H2 blockers:

- fexofenadine 0.18 g/day, ranitidine 0.3 g/day and hydroxyzine 25 mg/day;
- ketotifen 4 mg/day, ranitidine 0.3 g/day;
- dimethindene 4 mg/day, levocetirizine 5 mg/day.

Administration of prednisone 30 mg/day resulted in a short-term anti-pruritic effect.

On physical examination, swelling of the finger joints, generalized lymphadenopathy and typical urticarial rash were found. C-reactive protein (6.78 mg/dl, normal <5) and immunoglobulin E (564 IU/ml, normal <100) levels were elevated. A high level of anti-peroxidase antibodies (aTPO) was found (31.7 IU/ml, normal range <12 IU/ml). Serum levels of complement components C3 and C4, thyroid-stimulating hormone (TSH), free thyroxine (FT3), free triiodothyronine (FT4), anti-neutrophil cytoplasm antibodies (ANCA), anti-nuclear antibodies (ANA) and anti-thyroglobulin antibodies (aTG) were normal. Thyroid ultrasonography and scintigraphy were normal. A skin autologous serum test was negative. Histological examination of a lymph node revealed reactive lymphadenopathy. Skin biopsy showed no evidence of urticarial vasculitis (Fig. 2). We excluded connective tissue diseases, infectious diseases, *Helicobacter pylori* colonization and haematological disorders. We made the diagnosis of chronic continuous urticaria without angi-

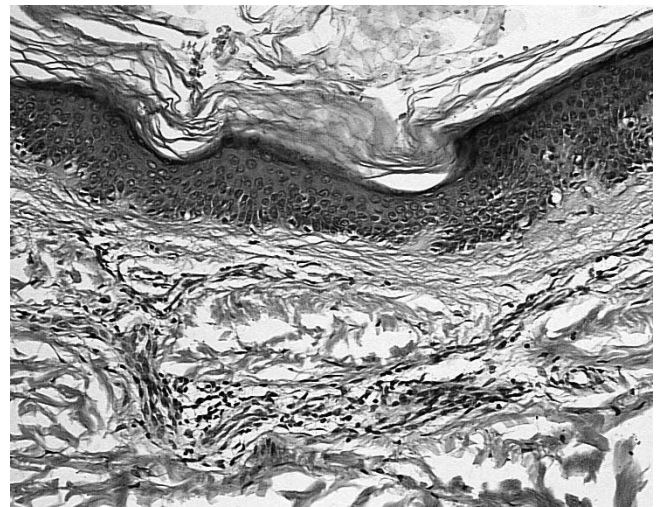


Fig. 2. Histology of lesions reveals perivascular lymphocytic infiltrates – a pattern normally found in urticaria.

oedema, associated with ATD according to the current consensus on classification of urticaria (6).

Treatment with L-thyroxine 50 µg/day was started. This dose was escalated by 25 µg every month, up to 125 µg/day. TSH was measured every 1–2 months and remained within 0.4–0.6 µIU/ml. After 6 weeks of therapy, while taking L-thyroxine 75 µg/day, the patient reported significant improvement, complete withdrawal of pruritus, lymphadenopathy and joint pain. Urticarial rash was still present; however, it was less frequent, with smaller still-confluent areas of wheals, and was not disturbing for the patient. Further escalation of the dose of L-thyroxine over 75 µg/day did not result in complete disappearance of the rash. All of these effects have lasted 12 months after follow-up.

DISCUSSION

The decision to apply a non-standard therapy was made due to the disturbing symptoms and lack of response to the previous treatment. It is planned to withdraw L-thyroxine substitution gradually over 2 years. Some authors suggest discontinuing treatment with L-thyroxine gradually within 2 years (3). Others recommend withdrawal of L-thyroxine after improvement is achieved, advising reintroduction of the treatment with recurrence of symptoms (7).

As its mechanism of action is unknown, L-thyroxine treatment in euthyroid patients with ATD associated with systemic symptoms is based on empirical observations and requires further research. The remission of urticaria with such treatment is usually achieved within 2 months, therefore Heymann (1) suggested that a trial of 8 weeks administration of L-thyroxine should be performed in patients with chronic idiopathic urticaria. Other therapeutic options in unresponsive chronic idiopathic urticaria are: plasmapheresis, intravenous immunoglobulin and cyclosporine (8).

Only a few cases of successful treatment with L-thyroxine of either urticaria (3) or polyarthritis (4) associated with ATD have been published. However, to our knowledge, there are no well-documented cases

of successful treatment with L-thyroxine of multiple symptoms (joint, skin and other) in one and the same patient. Urticaria may be one of many organ manifestations of a systemic auto-immunological disease with a similar mechanism.

Current opinion is that the presence of thyroid auto-antibodies does not cause urticaria directly (9). The presence of a co-existing, but unknown, auto-immunological disorder is possible. Gaig *et al.* (3) suggested that keeping the TSH level at the lower range of normal may help to control urticaria. It is speculated that thyroid stimulation with TSH may take part in the pathogenesis of autoimmune urticaria (7). We suggest careful observation of the TSH level during therapy to monitor the effects of treatment and to avoid exogenous hyperthyroidism.

REFERENCES

1. Heymann WR. Chronic urticaria and angioedema associated with thyroid autoimmunity: Review and therapeutic implications. *J Am Acad Dermatol* 1999; 40: 229–232.
2. Lenzoff A, Sussman GL. Syndrome of idiopathic chronic urticaria and angioedema with thyroid autoimmunity: a study of 90 patients. *J Allergy Clin Immunol* 1989; 84: 66–71.
3. Gaig P, Garcia-Ortega P, Enrique E, Richart C. Successful treatment of chronic idiopathic urticaria associated with thyroid autoimmunity. *J Investig Allergol Clin Immunol* 2000; 10: 342–345.
4. LeRiche NG, Bell DA. Hashimoto's thyroiditis and polyarthritis: a possible subset of seronegative polyarthritis. *Ann Rheum Dis* 1984; 43: 594–598.
5. Punzi L, Betterle C. Chronic autoimmune thyroiditis and rheumatic manifestations. *Joint Bone Spine* 2004; 71: 275–283.
6. Zuberbier T, Greaves MW, Juhlin L, Kobza-Black A, Maurer D, Stingl G, et al. Definition, classification, and routine diagnosis of urticaria: a consensus report. *J Investig Dermatol Symp Proc* 2001; 6: 123–127.
7. Rumbly JS, Katz JL, Schocket AL. Resolution of chronic urticaria in patients with thyroid autoimmunity. *J Allergy Clin Immunol* 1995; 96: 901–905.
8. Napoli DC, Freeman TM. Autoimmunity in chronic urticaria and urticarial vasculitis. *Curr Allergy Asthma Rep* 2001; 1: 329–336.
9. Rottem M. Chronic urticaria and autoimmune thyroid disease: is there a link? *Autoimmun Rev* 2003; 2: 69–72.