

INVESTIGATIVE REPORT

Spectrophotometric Analysis of Melanocytic Naevi During Pregnancy

Yvonne WYON¹, Ingrid SYNNERSTAD², Mats FREDRIKSON³ and Inger ROSDAHL²

¹Division of Dermatology, University Hospital, ²Department of Biomedicine and Surgery, and ³Department of Molecular and Clinical Medicine, Faculty of Health Sciences, University of Linköping, Linköping, Sweden

Malignant melanoma is the most common cancer during pregnancy, but it is unknown whether melanocytic naevi in general are activated. A total of 381 melanocytic naevi in 34 Caucasian primigravidae were examined using spectrophotometric intracutaneous analysis (SIAscopy) technology in early pregnancy and prior to delivery. The Siagraphs of each naevus were then compared in order to evaluate changes over time. A total of 163 melanocytic naevi in 21 nulliparous women served as an additional control group. At the first visit none of the Siagraphs examined for the case or control groups aroused suspicion of dysplastic naevus or melanoma and no significant structural changes were noted during the observation period. However, 2.1% of the melanocytic naevi in the pregnant group increased and 1.3% decreased in size. Corresponding figures in the non-pregnant group were 1.8% and 0%, respectively. Only one naevus in a pregnant woman increased slightly in epidermal pigmentation, and a decrease in pigmentation was noted in 3.7% of the melanocytic naevi in the cases and 1.8% in the controls. None of the differences within or between the groups was statistically significant. We conclude that pregnancy does not influence the appearance of pigmented naevi. A changing naevus during pregnancy should be examined carefully and considered for excision and histopathology. Key words: melanocytic naevi; pregnancy; SIAscopy.

(Accepted November 17, 2006.)

Acta Derm Venereol 2007; 87: 231–237.

Yvonne Wyon, Division of Dermatology, University Hospital, SE-581 85 Linköping, Sweden. E-mail: Yvonne.wyon@lio.se

Malignant melanoma (MM) is the most common malignancy during pregnancy, with an estimated incidence of 2.8–5 cases/100,000 pregnancies (1, 2). There has been some concern that hormonal and immunological alterations occurring during pregnancy might activate melanocytic naevi (MN) and favour the development and progression of melanoma (3, 4). However, a recent large population-based study of the effect of pregnancy on survival demonstrates that the prognosis for pregnant women with melanoma is not worse than for non-pregnant women (5). On the other hand, some reports have

shown an increase in the thickness of melanoma diagnosed in pregnant women compared with controls, implying either a more aggressive tumour or a delay in melanoma diagnosis during pregnancy (6–8). In our recent study no statistical difference in Breslow thickness was found in melanoma diagnosed in the pregnant, as compared with the non-pregnant, group (5). It has, however, been assumed that women in general interpret a change in MN as a normal phenomenon during pregnancy and do not seek early medical advice.

It is not known whether MN are activated or undergo changes during pregnancy. In two previous studies 10% and 33% of the pregnant women interviewed reported some change in size or colour of their MN (9, 10). When these self-reported alterations were analysed in more detail it was obvious that most lesions referred to were other skin lesions and not MN. Furthermore, Pennoyer et al. (11) were not able to demonstrate any significant changes in the size of MN when comparing photographs of MN in women during the first and third trimester. No significant histological changes were found in MN excised during pregnancy, compared with MN from non-pregnant women (9, 10). Nevertheless, there is a general opinion in the population and among healthcare personnel that MN grow and become darker during pregnancy. This view might be reinforced by increased body awareness and a change in body size or by the notable hormone-induced hyperpigmentation of certain skin areas during pregnancy. Against this background it is obvious that a more certain scientific basis for the management of changing MN in pregnant women is required.

The overall aim of this investigation was to study objectively whether any change in MN over time is associated with pregnancy in a group of healthy Caucasian primigravidae by clinical examination and by using the non-invasive spectrophotometric intracutaneous analysis (SIAscopy) technique to depict the *in vivo* micro-architecture of melanin, collagen pattern and blood perfusion in MN.

MATERIALS AND METHODS

This study was approved by the Regional Ethics Committee and follows the Helsinki declaration (<http://www.wma.net/e/policy/b3.htm>) and following amendments by the World Medical

Association. Patient consent was obtained following provision of oral and written information.

Study population

Caucasian primigravidae aged 18–40 years in their first trimester were recruited from the Maternity Health Care Centre in the City of Linköping, Sweden, between October 1, 2004 and January 31, 2005. At the first contact with the Centre, the midwife asked 58 consecutive primigravidae to participate. All of the women except 3 accepted and were contacted by a dermatologist (YW). At this point 7 women decided not to take part (4 due to lack of time, 3 because they had very few MN) and 7 could not be reached in time. The remaining 41 women were given an appointment within a few days and had the first skin examination before the 11th week of gestation. A second skin examination was planned for the 37th gestational week. 5/41 women had a miscarriage and 2 were excluded from the study due to very early delivery. In total, 34 women were examined twice during pregnancy (Fig. 1).

An additional control group in the same age range comprised Caucasian female medical students and hospital personnel. Exclusion criteria were previous or present pregnancy or current use of contraceptives (Fig. 1).

SIAscopy

SIAscopy is a unique skin imaging technology that uses visible and infrared light combined with a sophisticated model of the physics of light transport within the skin to create sub-surface skin maps of different skin chromophores, including haemoglobin, melanin and collagen (12).

Spectrophotometric analysis of pigmented MN was performed using SIAscopy technology in its current DERMETRICS® product suite (Astron Clinica, Cambridge, UK). The contact SIAscopy system operates by probing the skin with a hand-set using a solution (20% ethanol in distilled water) to image an area 12 × 12 mm, with radiation ranging from 400–1000 nm. A detailed technical specification is available at www.astronclinica.com. The spectrophotometric images describe the *in vivo* micro-architecture of pigmented lesions to a depth of 2 mm below the skin surface (13–16). These “optical biopsies” are then stored in a protected computerized database, from which it is easy to retrieve images, then rotate and compare them side by side or superimposed on the computer screen. Two diameters of the lesions were measured in mm with a ruler device integral to the system: the maximum diameter and 90° towards this diameter.

The device is factory calibrated and is automatically calibrated against the locked-in algorithms for calibration when the hand-set is put in the docking station.

The dermatoscopic Siagraph depicts the melanin structures and distribution pattern in the epidermis and papillary dermis. Information is given in the other four Siagraphs regarding dermal melanin, total melanin, collagen pattern and blood perfusion. The colours, structures and distribution pattern of melanin presented in the dermatoscopic Siagraph of common naevi, dysplastic naevi and melanoma are similar to what is put on view with the commonly used dermatoscopic technique. The diagnosis reached by clinical examination in combination with the dermatoscopic Siagraph can be supported further by information in the additional four Siagraphs. Supplementary to the known dermatoscopic structures, a typical common naevus shows various degrees of total pigment homogeneously distributed in the lesion, no blood displacement and a regular collagen network. Malignant melanoma presents the characteristic dermatoscopic pattern in the first Siagraph and the image for total melanin highlights the irregularities in pigmentation also commonly seen in the dermatoscopic picture of a melanoma. In addition, blood perfusion usually demonstrates a blood displacement, with a decrease in blood concentration inside the area of the lesion surrounded by an erythematous blush as a sign of an increased blood concentration around the periphery of a lesion. In the collagen Siagraph collagen holes are shown depicting areas of low papillary collagen concentration. The existence of dermal melanin, especially deep in the dermis, in combination with an erythematous blush and collagen holes are by themselves signs with high sensitivity and specificity for melanoma (17). Dermal melanin by itself is not an indicator of malignancy, but together with the rest of the Siagraphs dermal melanin is discriminating. A dysplastic naevus has no collagen holes, but may show signs of irregular vascularity as well as pigmentation.

A minor degree of variation in the pressure against the skin from the hand-set between the two exposures is to be expected. We were concerned initially that this would have an effect on blood distribution and size of the lesion. However, when tested the pressure was in part self-regulating, since a greater pressure produced unfocused images on the screen. The pressure is the same in the whole contact area. The general blood perfusion declined, but the blood distribution pattern persists unless a greater pressure was applied intentionally. Additionally, a reduced blood supply in the whole contact area by itself does not signify malignancy.

First appointment

Questionnaire. The women in both groups filled out a structured questionnaire concerning current and previous medical conditions, use of contraceptives, medical treatment, pregnancy status, date of last period and estimated date of delivery. A family and personal history of MM and information about pigmented MN was obtained (previously excised, new or changing MN). Sunburns before and after the age of 15 years (0, 1–5 or ≥ 6 times) and the use of sun-beds (number of occasions during previous year and estimated number during lifetime) were recorded. In addition pigment phenotype was registered; eye colour (blue/green or mixed/brown), hair-colour (blond, brown, black, or red) and skin-type (I–II or III–IV).

Skin examination. Initially a total body skin examination was performed by a dermatologist clinically to identify melanoma or dysplastic naevi. In each individual a maximum of 15 MN (≥ 2 mm) on the back and 10 MN on the lower legs were examined in detail and scanned spectrophotometrically. The back

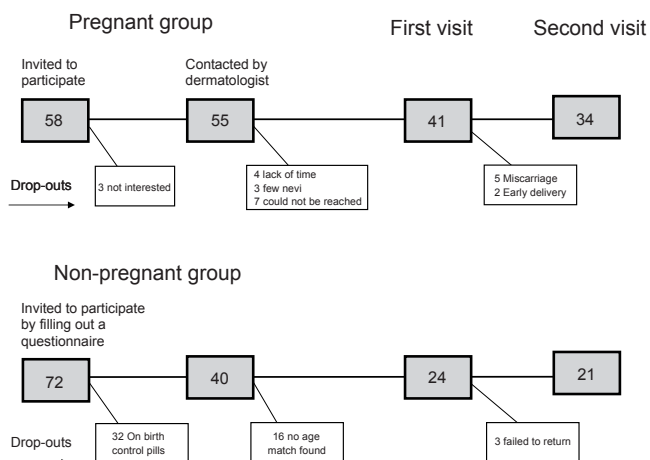


Fig. 1. Study design.

was chosen as study area, since this skin area was less likely to expand during pregnancy. Examination of MN on the lower legs was performed, since this is the most common location of MN in women. All Siagraphs were examined immediately after the appointments, and if they deviated in any respect from what was considered normal the lesion was excised or re-examined.

At the first visit bodyweight was registered and oedema of the lower legs was graded (grade 1–3). To eliminate known influences of sun exposure on appearance of naevi (18–20), all cases and control subjects were asked to avoid sun bathing and use of sun-beds during the study period.

Second appointment

The second appointment was planned for the 37th gestational week. The women were asked about occasional sun exposure and if they had noted any new lesions or changes in their MN. Bodyweight and degree of oedema were again registered. Skin examination and a second spectrophotometric scanning of the MN were once more performed. Each Siagraph was again reviewed directly after the visit for prompt excision if suspicious in any respect.

Siagraph analyses

All MN recorded at first and second appointment were compared independently by two investigators (YW and IS). Each MN was analysed according to the following parameters: size, asymmetry/symmetry, border, colour/pigmentation and structural pattern, (network, globules, black dots, radial streaming), total melanin, dermal melanin, blood perfusion and collagen pattern.

Statistics

Statistical analyses of the data were performed with Stata v9.1 (StataCorp LP, College Station, TX, USA). For continuous variables we used *t*-test and for categorical variables the χ^2 -test or Fisher's exact test when the expected numbers were small. A *p*-value of 0.05 was considered significant.

RESULTS

We studied spectrophotometric alterations in MN over time in 34 primigravidae (mean age 29.2 years, 95% confidence interval (CI) 27.9–30.6). These findings were compared with alterations in MN in 21 non-pregnant women (mean age 27.3 years, 95% CI 25.2–29.3). Seven pregnant women and two in the non-pregnant group had a family history of MM. None of the women in this study was previously diagnosed with a MM or had dysplastic naevus syndrome. At inclusion there were no significant differences between the pregnant and non-pregnant women concerning age, hair and eye-colour, skin type, previous sunburns or use of sun-beds (Tables I–II).

First appointment

At the first examination no clinically suspicious melanoma were found in either of the two groups. In all, 381 MN in the pregnant group (mean 11.2 MN/person, range 2–21, CI 9.3–13.1) and 163 MN in the non-pregnant group (mean 7.8 MN/person, range 4–21, CI 5.8–9.7) were examined at both the first and second appointment.

Table I. Phenotypic characteristics in the pregnant and non-pregnant group

	Pregnant <i>n</i> = 34	Non-pregnant <i>n</i> = 21	<i>p</i> -value
Age (mean)	29.2	27.3	0.09
Weight	64.4	59.0	0.01
Skin type			
I–II	30	15	
III–IV	4	6	0.12
Eye colour			
Blue/grey/green	32	20	
Brown/speckled	2	1	0.86
Hair colour in childhood			
Blond	25	14	
Brown	6	4	
Black	1	0	
Red	2	3	0.63

A maximum of 15 MN (≥ 2 mm) in each individual on the back and 10 on the lower legs were included in the study. In the pregnant group the mean number of MN on the back was 7.9 (95% CI 6.2–9.9) and in the non-pregnant group 5.4 MN (95% CI 4.1–6.7), (*p* = 0.03). The corresponding number on the lower legs was 3.4 (95% CI 2.7–4.0) and 2.4 (95% CI 1.4–3.4) respectively, (NS) (Table III). Most of the lesions were clinically easy to diagnose as benign MN and none of them fulfilled the clinical criteria for a dysplastic naevus. The majority of the Siagraphs did not deviate from what would be expected in a benign MN and showed a regular pattern of epidermal pigmentation and an even and symmetrical melanin distribution, some with brown globules, but none with black dots. No blood displacement or collagen holes were documented spectrophotometrically in any of the MN examined. However, out of the 544 lesions examined, in 15 clinically benign lesions the

Table II. History of sun-related behaviour in pregnant and non-pregnant group

	Pregnant <i>n</i> = 34	Non-pregnant <i>n</i> = 21	<i>p</i> -value
Sunburn before age 15 years			
Never	6	3	
1–5 times	9	5	
5 times	19	13	0.90
Sunburn after age 15 years			
0	2	0	
1–5 times	10	8	
> 5 times	22	13	0.46
Use of sun-beds			
0	0	4	
1–10	10	7	
11–50	15	5	
51–100	6	2	
>100	3	3	0.06
Use of sun-beds in previous year			
Yes	6	0	
No	28	21	0.10
"Sun seeker"			
Yes	17	9	
No	17	12	0.61

Table III. Number of melanocytic naevi examined on the back and lower legs in pregnant and non-pregnant women

	Pregnant <i>n</i> = 34	Non-pregnant <i>n</i> = 21	<i>p</i> -value
Total number of naevi examined	381	163	0.02
Mean number of:			
Naevi on back and lower legs/ person	11.2	7.8	0.09
Naevi on back/person	7.9	5.4	0.02
Naevi on lower legs/person	3.4	2.4	0.13

spectrophotometric findings were difficult to interpret and to disregard. None of these lesions was suspected to be a MM and there was no need for a prompt excision. However, four of them, all located on the back in three non-pregnant women, were excised to document degree of melanocytic activity. One of the MN had irregular pigmentation and a fairly abrupt edge of the pigmented network (Fig. 2), two had brown globules distributed in the periphery of the lesion as a sign of activity (Fig. 3) and all four displayed various degrees of dermal melanin. Histopathologically, however, all four lesions were benign MN (two junctional, one compound, and one intradermal MN). The other 11 MN in seven pregnant women were examined again after 3 months with the aim of following the stability of the lesions. No

change over time was discovered, and therefore these lesions were not excised. No systematic differences were found clinically or spectrophotometrically at the first visit between the MN observed in the pregnant and non-pregnant groups.

Second appointment

The mean time of observation (time between first and second examination) was 204 days (95% CI 199–209) in the pregnant group and 176 days (95% CI 161–191) in the non-pregnant group ($p < 0.01$). The majority of the women had avoided sun exposure, 7/34 in the pregnant group and 6/21 in the non-pregnant group had had some unintentional sun exposure on the face and arms, but not on the back or lower legs. None of the participants had suffered sunburn. No difference in any of the sun exposure parameters was noted during the observation time between the two groups. There were no self-reported new MN or changes in MN on the back and lower legs, since the first examination. At the second appointment one MN clinically diagnosed as a junctional naevus at the first visit was excised from a pregnant woman. The second Siagraphs showed a slight increase in size and change in form, fading brown globules and a slightly more manifest network




Fig. 2. Siagraphs of a melanocytic naevus in a non-pregnant woman, scanned at the first appointment. Note the presence of dermal melanin and the fairly abrupt edge of the pigmented network. The first Siagraph depicts melanin distribution pattern in epidermis and papillary dermis; the second shows the total amount of melanin in the lesion; the third shows dermal melanin; the fourth distribution and blood perfusion, and the fifth Siagraph gives an image of the collagen distribution in the lesion.

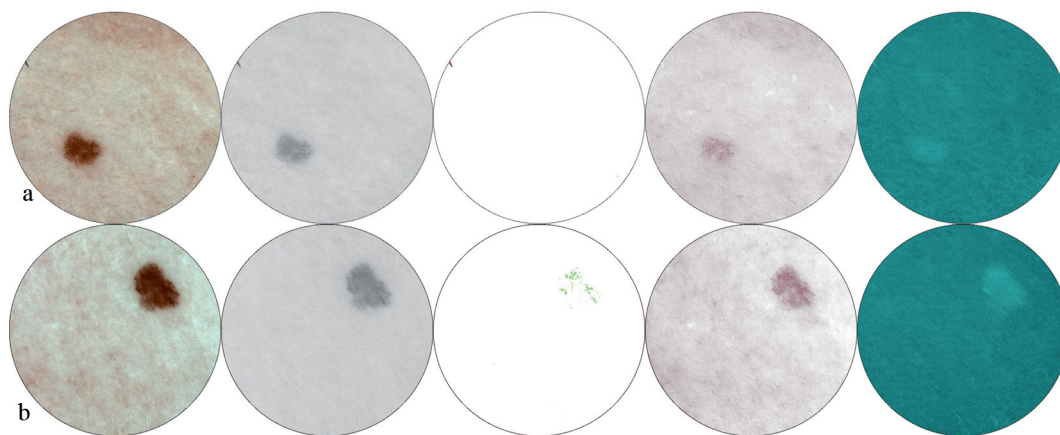


Fig. 3. Siagraphs of a melanocytic naevi in a pregnant woman. (a) At the first appointment in gestational week 7. (b) At the second appointment in gestational week 37. Notice a slight increase in size and change in form, fading brown globules and a slightly more manifest network in part of the naevus (Siagraph 1), together with a discrete increase in dermal melanin (Siagraph 3). For explanation of the Siagraphs see Fig. 2.

in part of the naevus, together with a discrete increase in dermal melanin compared with the first visits (Fig. 3). Histology indicated a benign junction naevus.

In the remaining 543 MN the clinical appearance or Si-agraphs in the case or control group did not deviate from what would be expected in a benign MN (Fig. 4). However, 2.1% of the MN in the pregnant group increased and 1.3% decreased in size. Corresponding figures in the non-pregnant group were 1.8% and 0%, respectively. No correlation was found between increased size of MN and skin type, age, eye- or hair-colour, total number of MN in the two study areas, or oedema. Only one naevus in a pregnant woman increased slightly in epidermal pigmentation and a decrease in pigmentation was noted in 3.7% of the MN in the cases and 1.8% in the controls. None of the differences within or between the two groups was statistically significant (Table IV). In the dermatoscopic Siagraph the majority of the MN with decreased pigmentation showed an image in line with an intradermal naevus and a slight decrease in total melanin. No collagen holes or deviating pattern of blood perfusion were noted. Insignificant changes in the number of brown globules and total melanin were

also noticed occasionally. No change in blood perfusion, such as blood displacement or blushes, or change in the collagen pattern were noticed in any of the 544 MN examined. When the two images of the same MN were evaluated side by side on the screen no statistical difference in score between the two investigators (YW and IS) was noted when the following naevus parameters were compared, size, asymmetry/symmetry, border, colour/pigmentation and structural pattern, (network, globules, black dots, radial streaming), total melanin, dermal melanin, blood perfusion and collagen pattern.

DISCUSSION

In this study MN on the back and lower legs were examined clinically and with spectrophotometric technology in 34 Caucasian primigravidae in early pregnancy and prior to delivery. No MM developed during the observation time and none of the women had any MN that fulfilled the clinical criteria for dysplastic naevi at the start or end of the study. In patients with the dysplastic naevus syndrome it has been demonstrated that pregnancy and hormone supplements are associated

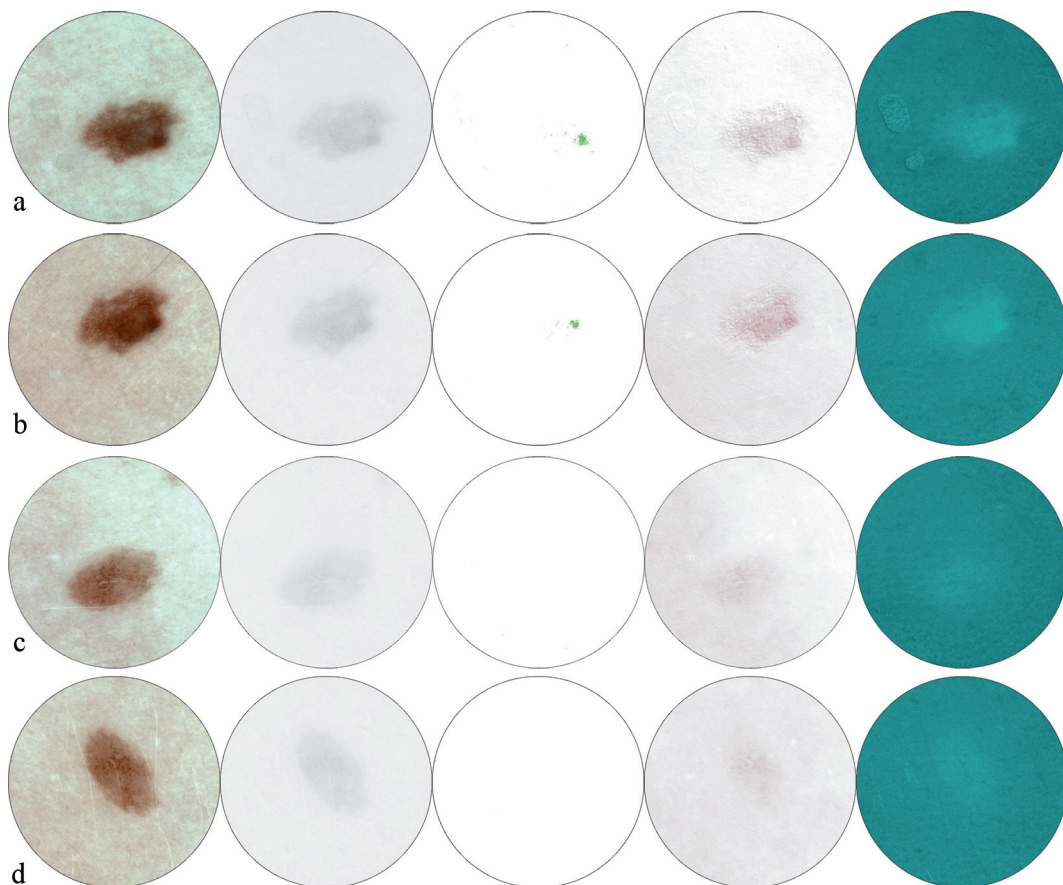


Fig. 4. Two representative examples of images. (a) A compound naevus with brown globules in the centre of the lesion and a pigment network towards the periphery early in pregnancy, and (b) the same lesion late in pregnancy. (c) A junctional naevus with a slightly irregular pigment network and a minimal amount of dermal melanin early in pregnancy, and (d) the same lesion late in pregnancy. No change was noted in any of the lesions between the two examinations. For explanation of the Siagraphs see Fig. 2.

Table IV. Change over time in melanocytic naevi in pregnant and non-pregnant women

	Pregnant n (%) MN = 380	Non-pregnant n (%) MN = 163	p-value
Decrease in epidermal melanin	14 (3.7)	3 (1.8)	0.43
Increase in epidermal melanin	1 (0)	0 (0)	
Increase in size	8 (2.1)	3 (1.8)	0.33
Decrease in size	5 (1.3%)	0 (0)	
Increase of dermal melanin	18 (4.7)	8 (4.9)	0.36
Decrease of dermal melanin	4 (1.0)	0 (0)	

MN: melanocytic naevi.

with an increased rate of clinical changes in the dysplastic naevi (21). The lack of dysplastic naevi on the back and legs in our subjects was unexpected, as the prevalence of dysplastic naevi in the Linköping region is 18% (22). Our finding that there was no significant clinical or spectrophotometric alteration in MN during pregnancy does not exclude that an unstable melanocyte system in individuals with the dysplastic naevus syndrome reacts differently, and this melanoma high-risk group has to be investigated separately.

SIAscopy is a new non-invasive skin imaging technique describing melanin distribution pattern in the epidermis and papillary dermis, total and dermal melanin, collagen pattern and blood perfusion (17, 23). When the two images of the same MN from early and late pregnancy were compared, no significant change was noted, but occasional MN displayed a slight increase or decrease in size or pigmentation. Similar minor changes were also noted in the MN in the non-pregnant group, which was examined according to the same procedure. Similar changes would be expected in both groups due to the life cycle of MN. The excision of a few MN was not motivated by a suspicion of MM, but rather to increase our knowledge of the significance of presence of dermal melanin in the Siagraphs. However, all excised MN were clinically and histopathologically diagnosed as benign MN.

There were more women in the pregnant group with a family history of MM than in the non-pregnant group and the pregnant women also had more MN per individual on the back and legs. This, however, did not result in less stable MN during pregnancy than in the non-pregnant controls. Neither did a somewhat longer observation time for the pregnant group compared with the controls lead to more prominent structural changes in MN.

Previous studies indicating a change in MN during pregnancy, are based mainly on self-reports, which are unreliable (10). Histology of MN during pregnancy has not been performed in a systematic way and obviously provides only an instantaneous picture, i.e. it does not document a change over time. Furthermore, the seasonal variation in naevus activity has been disregarded. In a histopathological study of naevus activity during

pregnancy MN from pregnant women were obtained during the summer period and MN from the "control group" were collected from histology records obtained all year around (10). To minimize the influence of sun-exposure, this study was performed during the winter season, and no difference in previous or present sun-related behaviour between the two groups was found. In a previous study using repeated clinical photographs it was not possible to verify any alterations in MN during pregnancy (11). Analysing "optic biopsies" of MN based on SIAscopy describing the *in vivo* micro-architecture of pigmented lesion has been shown to be a sensitive method to document changes in MN (17, 23). We have found this method useful to objectively and systematically retrieve images and register potential changes in MN over time. In this study Siagraphs of a few lesions were difficult to diagnose. Pending further experience of this new technology, it is recommended that excision should be performed in order to completely exclude activity in MN.

MM is the most common malignancy during pregnancy. We have not been able spectrophotometrically to document any significant changes in MN due to pregnancy, and we conclude that any change in a MN during pregnancy, except for those obviously due to distension of certain body areas, should be evaluated carefully and treated as any MN would be in a non-pregnant woman.

ACKNOWLEDGEMENTS

This study was supported by grants from the Welander Finsen foundation, Carl and Albert Molin's Foundation and Cancer and Allergy Foundation.

Conflict of interest: None to declare.

REFERENCES

1. Matthiesen L, Berg G. Malignant melanoma is the most common type of cancer occurring in pregnancy. *Läkartidningen* 1989; 35: 2845–2848 (in Swedish).
2. Dillman RO, Vandermolen LA, Barth NM, Bransford KJ. Malignant melanoma and pregnancy ten questions. *West J Med* 1996; 164: 156–161.
3. Mittelman A, Chen ZJ, Liu CC, Hirai S, Ferrone S. Kinetics of the immune response and regression of metastatic lesions following development of humoral anti-high molecular weight-melanoma associated antigen immunity in three patients with advanced malignant melanoma immunized with mouse antiidiotypic monoclonal antibody MK2-23. *Cancer Research* 1994; 54: 415–421.
4. Duhra P, Ilchysyn A. Prolonged survival in metastatic malignant melanoma associated with vitiligo. *Clin Exp Dermatol* 1991; 16: 303–305.
5. Lens MB, Rosdahl I, Ahlbom A, Farahmand BY, Synnerstad I, Boeryd B, et al. Effect of pregnancy on survival in women with cutaneous malignant melanoma. *J Clin Oncol* 2004; 22: 4369–4375.
6. Slingluff CL Jr, Reintgen DS, Volmer RT, Seigler HF. Malignant melanoma arising during pregnancy: a study of

- 100 patients. *Ann Surg* 1990; 211: 552–559.
7. MacKie RM, Bufalino R, Morabito A, Sutherland C, Cascinelli N. Lack of effect of pregnancy on outcome of melanoma: the World Health Organisation Melanoma Programme. *Lancet* 1991; 337: 653–655.
 8. Duncan LM, Travers RL, Koerner FC, Mihm MC Jr, Sober AJ. Estrogen and progesterone receptor analysis in pregnancy-associated melanoma: absence of immunohistochemically detectable hormone receptors. *Human Pathol* 1994; 25: 36–41.
 9. Sanchez JL. Behavior of melanocytic naevi during pregnancy. *Am J Dermatopathol* 1984; (suppl 6): 89–91.
 10. Foucar E, Bentley TJ, Laube DW, Rosai J. A histopathologic evaluation of nevocellular naevi in pregnancy. *Arch Dermatol* 1985; 121: 350–354.
 11. Pennoyer JW, Grin CM, Driscoll MS, Dry SM, Walsh SJ, Gelineau JP, et al. Changes in size of melanocytic naevi during pregnancy. *J Am Acad Dermatol* 1997; 36: 378–382.
 12. Cotton SD. A non-invasive imaging system for assisting in diagnosis of malignant melanoma. Ph D thesis, School of Computer Science, The University of Birmingham, Birmingham, UK, 1998.
 13. Cotton SD, Claridge E. Developing a predictive model of human skin colouring. In: Vanmetter RL, Beutel J, editors. *Proceedings of the SPIE medical imaging 1996*; 2708: p. 814–825.
 14. Marchesini R, Bono A, Bartoli C, Lualdi M, Tomatis S, Cascinelli N. Optical imaging and automated melanoma detection: questions and answers. *Melanoma Res* 2002; 12: 279–286.
 15. Wallace VP, Crawford DC, Mortimer PS, Ott RJ, Bamber JC. Spectrophotometric assessment of pigmented skin lesions: methods and feature selection for evaluation of diagnostic performance. *Phys Med Biol* 2000; 45: 735–751.
 16. Claridge E, Cotton S, Hall P, Moncrieff M. From colour to tissue histology: physics-based interpretation of images of pigmented skin lesions. *Med Image Anal* 2003; 7: 489–502.
 17. Moncrieff M, Cotton SD, Claridge E, Hall P. Spectrophotometric intracutaneous analysis: a new technique for imaging pigmented skin lesions. *Br J Dermatol* 2002; 146: 448–457.
 18. Larsen TE, Mogensen SB, Holme I. Seasonal variation of pigmented naevi. Intercorrelations of clinical and histological variables with special reference to seasonal variation. *Acta Derm Venerol* 1990; 70: 115–120.
 19. Flink AM, Fialla R, Steiner A. Seasonal pattern of the excision rate of melanoma and naevi. *Melanoma Res* 2001; 11: 531–534.
 20. Tronnier M, Smolle J, Wolff HH. Ultraviolet irradiation induces acute changes in melanocytic nevi. *J Invest Dermatol* 1995; 104: 475–478.
 21. Ellis DL. Pregnancy and sex steroid hormone effects on naevi of patients with the dysplastic nevus syndrome. *J Am Acad Dermatol* 1991; 25: 467–482.
 22. Newton-Bishop J, Bergman W, Österlind A, Scerri L, Weichenthal M, Rosdahl I. To assess the feasibility to screening for the atypical mole syndrome phenotype in primary health care. *Br J Dermatol* 2000; 142: 331–337.
 23. Cotton SD, Claridge E, Hall P. Noninvasive skin imaging. In: Duncan J, Gindi G, editors. *Information processing in medical imaging*. Berlin: Springer-Verlag, 1997: 501–506.