

Spiny Keratoderma of the Palms Successfully Treated with Topical Tacalcitol

Mami Yukawa, Takahiro Satoh*, Tetsuya Higuchi and Hiroo Yokozeki

Department of Dermatology, Graduate School, Tokyo Medical and Dental University, 1-5-45 Yushima, Bunkyo-ku, Tokyo, Japan.

*E-mail: tasa-1688.derm@tmd.ac.jp

Accepted November 17, 2006.

Sir,

Spiny keratoderma is a rare disease characterized by keratotic spicules resembling a “music box spine” located on the palms and soles (1). This entity has been reported under several different names, such as punctate keratoderma (2), punctate porokeratotic keratoderma (3), palmar filiform hyperkeratosis (4), and spiny keratoderma of the palms and soles (1). We present here a case of spiny keratoderma of the palms treated with topical tacalcitol.

CASE REPORT

A 64-year-old man had a 3-year history of spiny keratotic lesions on the palms. The patient noticed spicules during radiation therapy given for his gingival squamous cell carcinoma. His medical history also included diabetes mellitus, hypertension, and hyperlipidaemia, none of which had been treated. On physical examination, numerous firm, 0.5–1 mm, keratotic spicules were seen on the volar surface of the palms and fingers (Fig. 1a). There were no similar lesions at other sites, including the soles. On histology, a parakeratotic

column with a diminished granular layer was noted (Fig. 2a). Neither dyskeratosis nor vacuolar change was found in the epidermis. Initially, the patient was treated with 10% urea cream with no improvement. However, the topical application of 0.002% tacalcitol ointment (Bonalfa High®, Teijin Pharma Ltd, Japan) dramatically improved the keratotic spicule lesions within 3 months (Fig. 2a), and a diminished keratotic column with normal appearance of the granular layer was seen at that time (Fig. 1b).

DISCUSSION

Spiny keratoderma has a heterogeneous aetiology (4); there are hereditary variants and idiopathic forms. Malignant disease has also been implicated as being related to spiny keratoderma (4). Consistent with this, our case developed skin lesions during radiotherapy for squamous cell carcinoma of the gingival mucosa. However, the link between spiny keratoderma and gingival carcinoma is uncertain.

The treatment of spiny keratoderma has not been established; 5% 5-fluorouracil cream (1) and 12% am-

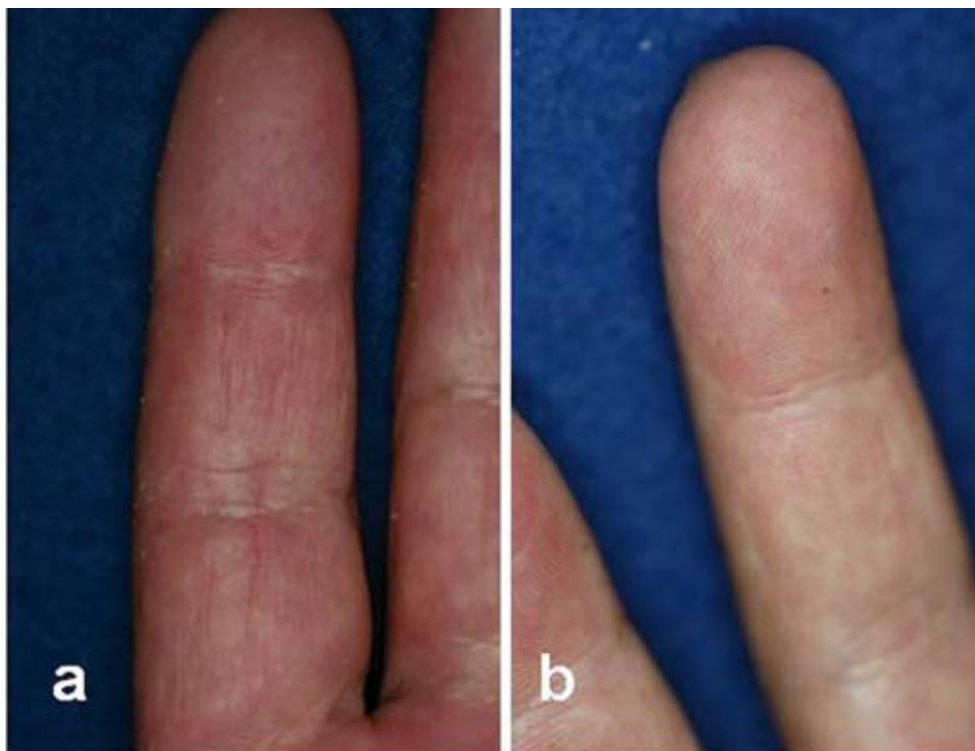

Fig. 1. Spiny keratotic projections on the palmar surfaces (a) before treatment and (b) after treatment with 0.002% tacalcitol.

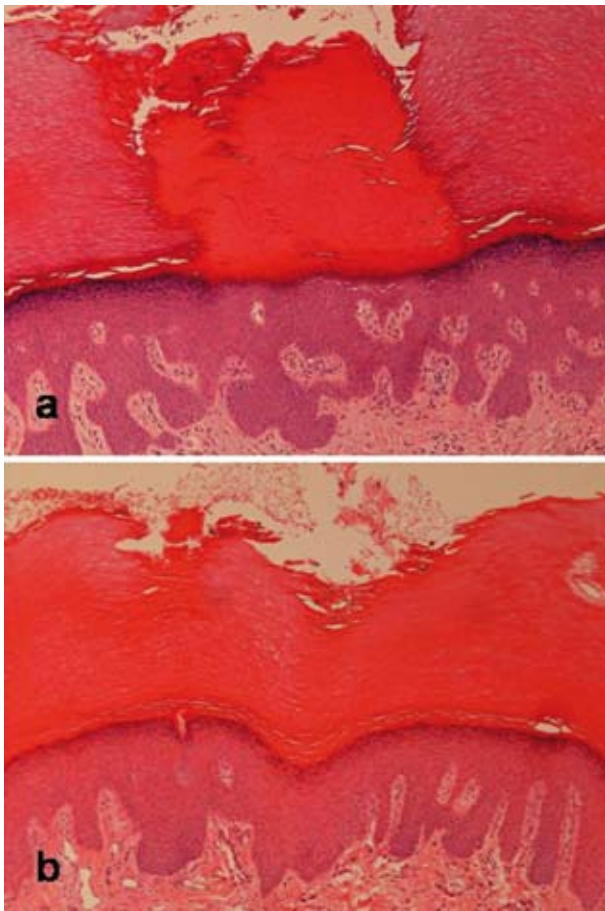


Fig. 2. Discrete parakeratotic column with a thinned granular layer. (a) Before treatment. (b) The keratotic column is no longer visible, and the granular layer now has a normal thickness.

monium lactate (5) have been reported to provide a relatively good response. Here we report for the first time that 0.002% tacalcitol ointment remarkably improved spiny keratoderma skin lesions. Tacalcitol is an active form of vitamin D3 and has been reported to suppress proliferation, or induce terminal differentiation of keratinocytes (6). These pharmacological activities might be the result of improved keratinization processes in the present case. Although there was a partial recurrence approximately 3 months after the cessation of therapy, 0.002% tacalcitol appears to be a useful treatment for spiny keratoderma.

Conflict of interest: None to declare.

REFERENCES

1. Osman Y, Daly TJ, Don PC. Spiny keratoderma of the palms and soles. *J Am Acad Dermatol* 1992; 26: 879–881.
2. Brown FC. Punctate keratoderma. *Arch Dermatol* 1971; 104: 682–683.
3. Herman PS. Punctate porokeratotic keratoderma. *Dermatologica* 1973; 147: 206–213.
4. Kaddu S, Soyer HP, Kerl H. Palmar filiform hyperkeratosis: a new paraneoplastic syndrome? *J Am Acad Dermatol* 1995; 33: 337–340.
5. Horton SL, Hashimoto K, Toi Y, Miner JE, Mehregan D, Fligel A, et al. Spiny keratoderma: a common under-reported dermatosis. *J Dermatol* 1998; 25: 353–361.
6. Matsumoto T, Yamamoto M, Mimura H, Ohta T, Kiyoki M, Ohba T, et al. 1, 24 (R)-dihydroxyvitamin D3, a novel active form of vitamin D3 with high activity for inducing epidermal differentiation but decreased hypercalcemic activity. *J Dermatol* 1990; 17: 135–142.