

Infliximab: A Novel Treatment Option for Refractory Orofacial Granulomatosis

Wiebke K. Peitsch, Nicole Kemmler, Sergij Goerdts and Matthias Goebeler*

Department of Dermatology, University Medical Center Mannheim, University of Heidelberg, Theodor-Kutzer-Ufer 1–3, DE-68135 Mannheim, Germany.

*E-mail: matthias.goebeler@haut.ma.uni-heidelberg.de

Accepted October 12, 2006.

Sir,

Orofacial granulomatosis (OFG) encompasses conditions characterized by non-necrotizing granulomatous inflammation of the oral and maxillofacial region that present clinically as labial enlargement, perioral and/or mucosal swelling, oral ulcerations and gingivitis. The tongue may be fissured and, rarely, facial nerve palsy can arise. The unifying term “OFG” has been introduced to integrate the spectrum of various disorders, including Melkersson-Rosenthal syndrome, granulomatous cheilitis (which is sometimes considered to be a monosymptomatic form of Melkersson-Rosenthal syndrome), Crohn’s disease, sarcoidosis and infectious diseases, such as tuberculosis (1). Certainly, similar clinical and histopathological presentations of these disorders encompassed as OFG do not necessarily reflect a common underlying aetiological mechanism. Although multiple treatment options have been reported for OFG, results are often disappointing and, occasionally, cannot prevent impaired functional complications and psychological problems arising (2–4).

CASE REPORT

We describe here a 23-year-old man who presented with painless swelling of the lower lip, the cheeks and oral aphthosis, which first occurred 6 weeks earlier and did not respond to oral cefuroxime prescribed by his general practitioner. The patient’s medical history was unremarkable with respect to fever, lymphadenopathy, genital ulcers, arthralgia, ocular symptoms or dyspnoea; however, he reported repeatedly experiencing an ileus which had required partial colectomy. On clinical examination, pronounced swelling of the lower lip and cheeks was seen (Fig. 1a), accompanied by cheilitis mediana and angularis and superficial aphthous ulcers of the oral mucosa. A laboratory workup including serum chemistry profile, differential blood count, C-reactive protein, angiotensin-converting enzyme, C1

esterase inhibitor, complement C3 and C4 as well as microbiological tests including bacterial and fungal cultures and polymerase chain reaction (PCR) for Herpes simplex virus did not reveal pathological results. A chest X-ray was unremarkable, showing no signs of sarcoidosis. A biopsy was obtained from the lower lip and revealed multiple non-necrotizing epitheloid granulomas with multinucleate giant cells accompanied by a dense inflammatory infiltrate composed of lymphocytes and plasma cells (Fig. 2). With respect to the patient’s history of ileus, colonoscopy was performed which, however, was neither endoscopically nor histologically indicative for Crohn’s disease or colitis. Based on these findings, OFG was diagnosed.

Therapy with oral methylprednisolone (25 mg per day) was initiated, but did not control the disease either alone or in combination with dapsone (100 mg per day). The patient subsequently received metronidazole and ibuprofen for another 2 months; again, without improvement in clinical symptoms. Later, hydroxychloroquine (400 mg per day for 2 months) and sulphasalazine (3 g per day for 2 months) were successively added to low-dose oral prednisolone, but did not resolve the lesions. Despite all these treatments, the swelling was deteriorating, and the patient, severely distressed because of his condition, was desperate for a more effective alternative. Reductive cheiloplasty was discussed, but did not seem promising, as for acceptable long-term results a quiescent state of the disease is required. Intralesional application of triamcinolone did not appear suitable since not only the lower lip but also the cheeks were involved. Another treatment option described in the literature, clofazimine, could not be initiated because of an interruption in the supply. In this situation it was decided to administer the chimeric monoclonal antibody infliximab (Remicade®), which neutralizes the pro-inflammatory cytokine tumour necrosis factor- α (TNF- α). Infliximab was applied intravenously at a dose of 5 mg per kg body-weight; additional courses were given after 2, 6 and 10 weeks. After only the first infusion, a remarkable reduction in swelling was noted. The 3 subsequent infusions resulted in further improvement in orofacial swelling (Fig. 1b) and in complete healing of the oral aphthae. As there was persistent mild swelling of the lower lip, it was decided to continue infliximab at 8-week intervals as maintenance therapy.

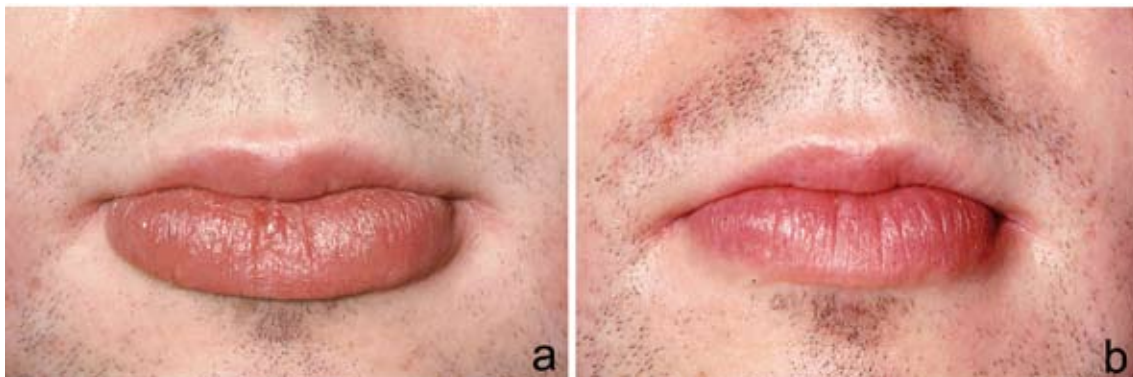


Fig. 1. (a) Swelling of the lower lip and cheeks prior to infliximab therapy. (b) Almost complete remission of lip swelling at 8 weeks after initiation of infliximab.

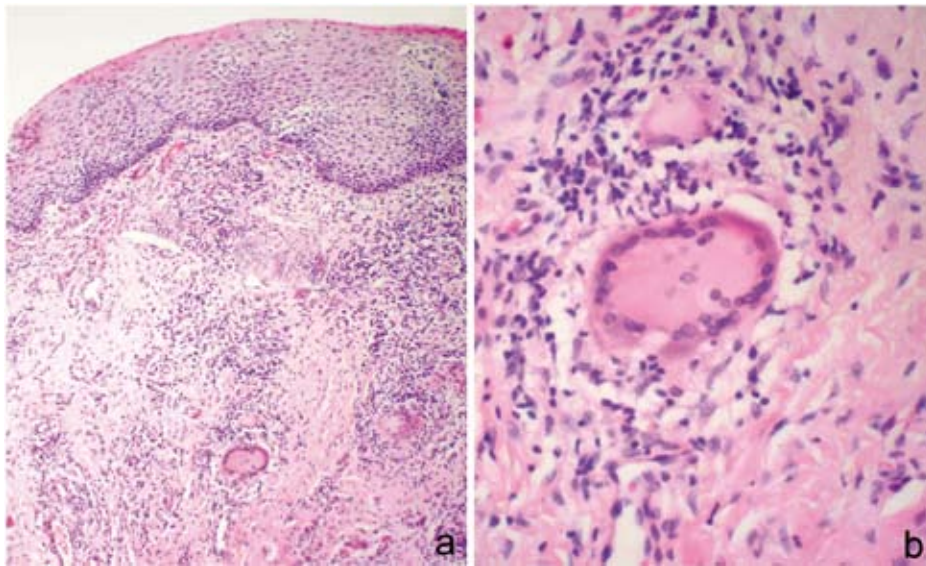


Fig. 2. (a) Presence of multiple non-necrotizing epithelioid granulomas with multinucleate giant cells accompanied by a dense inflammatory infiltrate. Biopsy was obtained from the lower lip (haematoxylin and eosin (H&E) $\times 100$). (b) Higher magnification of (a) showing multinucleate giant cells ($\times 400$).

DISCUSSION

Infliximab is approved for use in severe and refractory rheumatoid arthritis, Bechterew's disease, psoriasis and psoriatic arthritis, as well as for recalcitrant Crohn's disease (5). Interestingly, in the latter condition, it appears to work as well in cases of orofacial involvement (6). With respect to the relationship between Crohn's disease and OFG, infliximab has recently been used successfully for treatment of granulomatous cheilitis (7), suggesting that TNF- α plays a central role in the pathogenesis of OFG. This assumption is further substantiated by the observation that thalidomide, an effective inhibitor of TNF- α , was successfully applied in granulomatous cheilitis (8). It is important to note that granulomatous cheilitis may precede Crohn's disease (9). It therefore seems advisable to provide a careful follow-up, especially in our patient who had a history of gastrointestinal complaints.

Moreover, it should be noted that infliximab may under no circumstances be used in cases of OFG where mycobacteria are the aetiological agent. TNF- α is required for granuloma formation, which in, for example, tuberculosis or leprosy, represents the effort of the host to control mycobacterial infection efficiently (10). Screening for mycobacterial infections is therefore mandatory prior to the use of TNF- α -blocking agents (11). After exclusion of such conditions, infliximab may be a valuable treatment option for recalcitrant OFG when other therapeutic approaches have failed.

ACKNOWLEDGEMENT

The authors thank Drs. Bertling, Schmidt and Wendler, Speyer, Germany, for providing the biopsy samples.

Conflicts of interest: There are no conflicts of interest.

REFERENCES

1. Wiesenfeld D, Ferguson MM, Mitchell DN, MacDonald DG, Scully C, Cochran K, et al. Oro-facial granulomatosis – a clinical and pathological analysis. *Q J Med* 1985; 54: 101–113.
2. Ziem PE, Pfrommer C, Goerdt S, Orfanos CE, Blume-Peytavi U. Melkersson-Rosenthal syndrome in childhood: a challenge in differential diagnosis and treatment. *Br J Dermatol* 2000; 143: 860–863.
3. van der Waal RI, Schulten EA, van der Meij EH, van de Scheur MR, Starink TM, van der Waal I. Cheilitis granulomatosa: overview of 13 patients with long-term follow-up – results of management. *Int J Dermatol* 2002; 41: 225–229.
4. Sciubba JJ, Said-Al-Naief N. Orofacial granulomatosis: presentation, pathology and management of 13 cases. *J Oral Pathol Med* 2003; 32: 576–585.
5. Chang JT, Lichtenstein GR. Drug insight: antagonists of tumor-necrosis factor-alpha in the treatment of inflammatory bowel disease. *Nat Clin Pract Gastroenterol Hepatol* 2006; 3: 220–228.
6. Mahadevan U, Sandborn WJ. Infliximab for the treatment of orofacial Crohn's disease. *Inflamm Bowel Dis* 2001; 7: 38–42.
7. Barry O, Barry J, Langan S, Murphy M, Fitzgibbon J, Lyons JF. Treatment of granulomatous cheilitis with infliximab. *Arch Dermatol* 2005; 141: 1080–1082.
8. Thomas P, Walchner M, Ghoreschi K, Röcken M. Successful treatment of granulomatous cheilitis with thalidomide. *Arch Dermatol* 2003; 139: 136–138.
9. Kano Y, Shiohara T, Yagita A, Nagashima M. Association between cheilitis granulomatosa and Crohn's disease. *J Am Acad Dermatol* 1993; 28: 801.
10. Ehlers S. Why does tumor necrosis factor targeted therapy reactivate tuberculosis? *J Rheumatol Suppl* 2005; 74: 35–39.
11. British Thoracic Society Standards of Care Committee. BTS recommendations for assessing risk and for managing Mycobacterium tuberculosis infection and disease in patients due to start anti-TNF-alpha treatment. *Thorax* 2005; 60: 800–805.