

Non-Hodgkin's Lymphoma Associated with Leiomyomatosis Presenting with Intense Pruritus

Ülker Gül¹, Arzu Kılıç^{1*}, Özlem Demirel¹, Müzeyyen Gönül¹, Seray Külcü Çakmak¹ and Murat Demiriz²

¹2nd Dermatology Clinic, Ankara Numune Education and Research Hospital, Onur Sok. No. 47/11, TR-06570 Anittepe Ankara, and ²Department of Pathology, Gulhane Military School of Medicine, Ankara, Turkey. *E-mail: kilicarzu@gmail.com

Accepted October 12, 2006.

Sir,

Generalized pruritus may be a presenting and/or the only symptom of malignancy. Pruritus related to non-Hodgkin's lymphoma (NHL) has been reported in 1–3% of patients with NHL (1). We report here a patient with intractable pruritus who was diagnosed with NHL.

CASE REPORT

A 41-year-old woman presented with intense itching, which had been present for 6 months. The itching was continuous and occurred at the same intensity at all times. She had used various treatments, including oral antihistamines, emollients and anti-scabies therapy, to no effect. She reported that she had night sweats accompanying the pruritus. She did not describe any weight loss and denied using any drugs.

Dermatological examination revealed erythematous papules with crusts and multiple excoriations due to severe itching localized on both the trunk and the extremities (Fig. 1). Physical examination showed multiple enlarged lymph nodes in both her axillary and inguinal regions.

A detailed laboratory examination was carried out. The results were: haemoglobin level 8.3 g/dl (normal 12–14 g/dl), lactate dehydrogenase 678 U/l (normal 125–243 U/l), carcinoma antigen 125 > 600 (normal 0–35). The following values were normal: peripheral

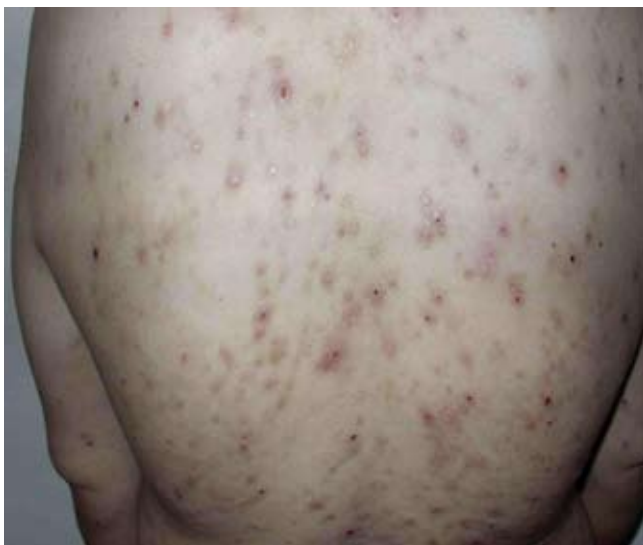

Fig. 1. Skin eruption on the back.

blood smear, immunoglobulin A, M and G levels, protein electrophoresis, complement levels, liver and kidney function tests, urinalysis, and other tumour and hepatitis markers.

Abdominal ultrasonography revealed an enlarged liver and spleen with hypoechoic solid lesions. Multiple enlarged lymph nodes were detected in both the parailiacal and pelvic regions. Abdominal tomography revealed a mass in the right iliopsoas muscle in addition to the findings mentioned above.

Histopathological examination of the skin lesions revealed non-specific findings.

Aspiration biopsy of the bone marrow showed an erythropoiesis, but no atypical cells were observed. Excisional biopsy of the inguinal lymph node revealed a tumour characterized by interlacing bundles of fusiform mesenchymal cells separated by vascularized connective tissue. No other nuclear pleomorphism and mitotic activity was detected in the neoplastic cells (Fig. 2). These findings were consistent with leiomyomatosis.

An aspiration biopsy of the liver was performed and histopathological examination revealed the large cell aggressive type of NHL (Fig. 3).

The patient was referred to the haematology clinic and was given chemotherapy. Unfortunately, she died soon after the diagnosis.

DISCUSSION

Pruritus may be one of the most troublesome symptoms of internal diseases. Among patients seeking medical attention for pruritus, the prevalence of underlying sys-

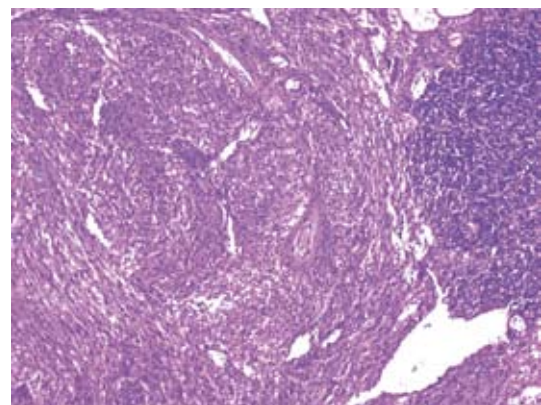


Fig. 2. The tumour in the lymph node formed by interlacing bundles of fusiform mesenchymal cells (haematoxylin and eosin (H&E) ×50).

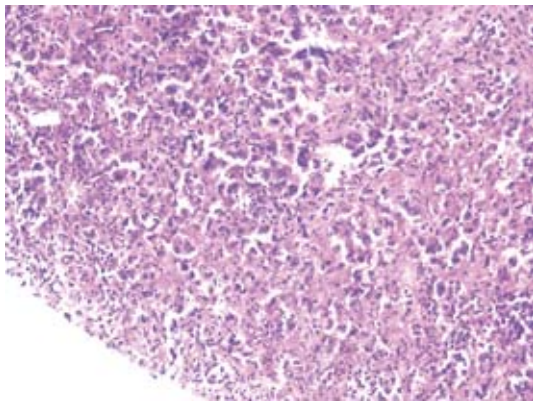


Fig. 3. Atypical cells in the liver (haematoxylin and eosin (H&E) $\times 100$).

temic disease including malignancy has been estimated to be 10–50% (2, 3).

Generalized pruritus may be the presenting and/or only symptom of an occult malignancy (1). Among malignant diseases, pruritus has been related most often to Hodgkin's disease (4–6). It is seen in about 30% of patients with Hodgkin's disease. However, the prevalence of skin findings in NHL has been reported as 1–3% (3).

Leiomyomatosis of lymph nodes is an extremely rare disease (7). It is related, in particular, to gynaecological malignancies, such as benign uterine leiomyoma, a metastasizing uterine leiomyoma, an endometrial adenocarcinoma, or an ovarian endometrioid carcinoma (8). Lee et al. (8) reported a case of leiomyomatosis associated with a duodenal adenocarcinoma.

It is therefore important to consider malignancy in patients with long-term pruritus and/or non-specific skin eruption. In conclusion, our report consists of 2 rare conditions in one patient. One is the coexistence of pruritus and NHL, a relatively rare association. The second is the presence of leiomyomatosis, again a rare condition, which is most often seen with benign gynaecological diseases, here accompanying NHL.

REFERENCES

1. Lober CW. Should the patient with generalized pruritus be evaluated for malignancy? *J Am Acad Dermatol* 1988; 19: 350–352.
2. Krajnik M, Zylichz Z. Pruritus in advanced internal diseases, pathogenesis and treatment. *Neth J Med* 2001; 58: 27–40.
3. Krajnik M, Zylichz Z. Understanding pruritus in systemic disease. *J Pain Symptom Manage* 2001; 21: 151–168.
4. Kapilin U, Thestrup-Pedersen K, Steniche T, Lomholt H. Skin markers for Hodgkin's disease. *Acta Derm Venereol* 2005; 85: 345–381.
5. Stadie V, Marsch WCH. Itching attacks with generalized hyperhidrosis as initial symptoms of Hodgkin's disease. *J Eur Acad Dermatol Venereol* 2003; 17: 559–561.
6. Omidvari SH, Khojasteh HN, Mohammadianpanch M, Monabati A, Mosalaes A, Atimadloo N. Long-term pruritus as the initial and sole clinical manifestation of occult Hodgkin's disease. *Indian J Med Sci* 2004; 58: 250–252.
7. Mazzoleni G, Salerno A, Santini D, Marabini A, Martinelli G. Leiomyomatosis in pelvic lymph nodes. *Histopathology* 1992; 21: 588–589.
8. Lee KF, Lin PY, Cheung YC. Leiomyomatosis of mesenteric lymph nodes associated with duodenal adenocarcinoma. *Chang Gung Med J* 2002; 25: 271–274.