

Keratosis Lichenoides Chronica: Treatment with Bath-PUVA

Christian Kunte¹, Karin Kerschenlohr¹, Martin Röcken^{1,2} and Carl Georg Schirren^{1,3}

Department of Dermatology, ¹Ludwig-Maximilians University of Munich, Frauenlobstraße 9–11, DE-80337 München, ²Eberhard Karls University of Tübingen, and ³Dermatohistopathology Institute, Darmstadt, Germany. E-mail: C.Kunte@lrz.uni-muenchen.de
Accepted October 26, 2006.

Sir,

Keratosis lichenoides chronica (KLC) is a rare and chronic skin disease characterized by erythemas, keratotic and lichenoid papules, arranged in a linear pattern (1) and seborrhoeic-like scaling lesions on the trunk and limbs (1, 2). The lesions are slowly progressive with no tendency to heal and are resistant to most therapeutic modalities. Typical locations are the limbs, face, nails, palms, soles and mucous membranes (2, 3). No preference has been described for sex or age. Since 1972 the term “keratosis lichenoides chronica”, suggested by Margolis, has been generally accepted for this condition, except in France, where it is named “lichenoid tri-keratosis” (1). KLC is commonly considered either as a distinct entity or as a rare manifestation of lichen planus.

Here we describe 2 young adults with typical clinical features of KLC and propose bath-psoralen plus ultraviolet light A (bath-PUVA) therapy as a potentially useful treatment for this rare disease, which is resistant to most classical anti-inflammatory therapies.

CASE REPORTS

Patient 1

A 27-year-old, otherwise healthy man suffered for 5 years from slightly itchy papules of the limbs and genital area. The patient had not received any tuberculostatic therapy.

The flexural areas of the limbs showed violaceous, papular and partially keratotic lesions arranged in a linear pattern (Fig. 1). The pubic region was affected by densely aggregated erythematous lichenoid and partially keratotic papules and plaque-like keratosis. Scattered papules were also found on the trunk. The face, palms, soles and nails were unaffected.

A skin biopsy revealed irregular acanthosis with loss of the granular layer and compact parakeratosis, overlying a band-like infiltrate of lymphocytes and histiocytes in the upper dermis. The basal layer showed vacuolar alteration, colloid bodies and dyskeratotic cells (Fig. 2).

Direct immunofluorescence investigations showed depositions of fibrinogen in a diffuse pattern along the dermo-epidermal junction and evidence of hyaline bodies.

Complete blood count, hepatitis and HIV serology, *Treponema pallidum* haemagglutination assay (TPHA) and Venereal Diseases Research Laboratory (VDRL) test and antinuclear antibodies were normal. IgG antibodies against toxoplasmosis were positive.

Keratolytic agents in combination with glucocorticoids showed no therapeutic benefit, even when applied for prolonged periods in an occlusive manner. During 3 years of follow-up, numerous new papules developed in a characteristic linear or reticular pattern.

Treatment with balneo-photo-therapy with 8-methoxy-psoralen and UVA irradiation (body: 57 treatments for 12 months with a total dose of 150.9 J/cm²; feet: 36 treatments for 4 months with a total dose of 117 J/cm²; knees and elbows: 25 treatments for 4 months with a total dose of 79.5 J/cm²) did not improve the disease.

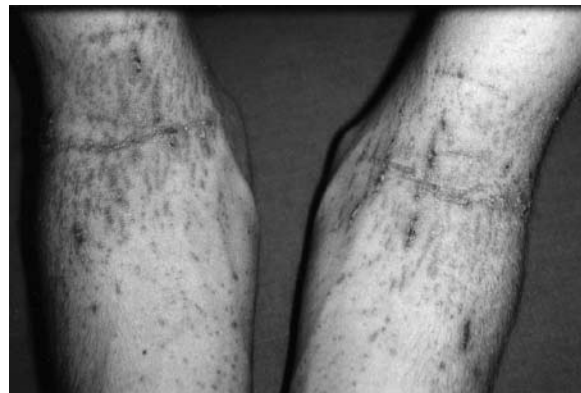

Fig. 1. Keratotic papules in a linear pattern at flexures of the upper extremities (patient 1).

Patient 2

A 27-year-old man presented with a 1-year history of extremely itchy keratotic papules, initially only on the flexure sides of the limbs, which later extended to the trunk. He had no history of taking anti-tuberculous drugs.

Physical examination revealed scaly erythema in the seborrhoeic areas of the face. The penile root and trunk had widely distributed lichenoid and keratotic papules. Linear formation of keratotic and lichenoid papules was seen along the cubital and genicular fossae in particular (Fig. 3A). The palms, soles and nails were unaffected.

Skin biopsy showed an irregular acanthosis and papillomatosis of epidermis without granular layer and a compact parakeratosis. In the upper dermis there was a band-like infiltrate consisting of lymphocytes, histiocytes, plasma cells and pigmented macrophages. The basal layer of epidermis showed vacuolar alteration, colloid bodies and dyskeratotic cells. Direct immunofluorescence showed fibrinogen in a diffuse pattern along the dermo-epidermal junction.

The patient's complete blood count was normal. HIV serology, TPHA and VDRL test, antinuclear antibodies and a test for toxoplasmosis were all negative. Hbs-antigen was positive after active immunization. Allergological tests were all negative.

Systemic treatment with glucocorticoids and external keratolytic agents lead to a temporary improvement and keratolysis. During therapy with topical glucocorticoids and tacalcitol the pre-existing papules extended in a linear pattern.

During bath-PUVA therapy (body: 75 treatments for 14 months with a total dose of 285.8 J/cm²; elbows: 55 treatments for 15 months with a total dose of 117.0 J/cm²) the disease improved: the papules partially regressed (Fig. 3) and the severe itching resolved.

DISCUSSION

Histological examination of KLC reveals lichenoid dermatitis with hyper- and parakeratosis, loss of the granular layer, a band-like inflammatory subepidermal infiltrate and colloid bodies (4). Although the aetiology

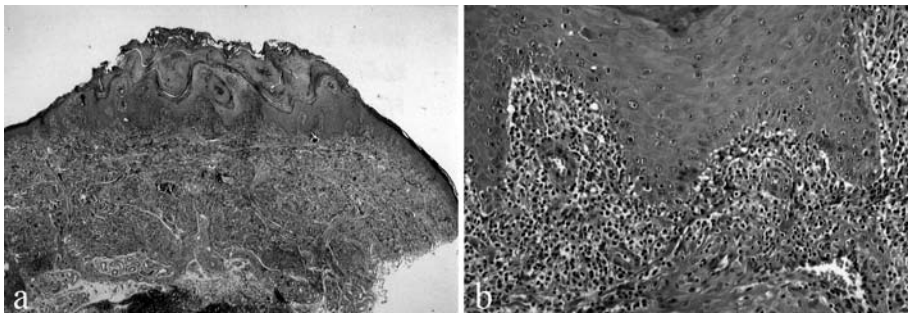


Fig. 2. (A) Lichenoid dermatitis with parakeratosis (haematoxylin-eosin (H&E), magnification $\times 2$). (B) Higher magnification shows the dyskeratotic cells and the vacuolar alteration at the junction (H&E, magnification $\times 200$).

and pathogenesis of KLC are unknown, its close similarity to lichenoid drug eruption induced by tuberculostatic and anti-malarial drugs suggest that KLC is a variant of lichenoid drug eruptions (1). Menter & Morrison (5) described 3 cases of KLC, suggesting that it might be a cutaneous manifestation of toxoplasmosis.

Therapy with keratolytic agents, tar or glucocorticoids is usually ineffective. Successful treatment has been reported with oral PUVA, bath-PUVA, aromatic retinoids and topical calcipotriol (6–14).

Since lichen planus responds favourable to bath-PUVA therapy, and since bath-PUVA therapy also seems to be superior to oral PUVA in the treatment of lichen planus, we initiated bath-PUVA therapy in the 2 patients with KLC. Beneficial effects of oral photochemotherapy were reported in 2 patients with KLC (11, 14), and a partial response in a third case (12). One patient cleared completely with bath-PUVA alone.

It is well known that UVA irradiation, especially in combination with 8-methoxy-psoralen, has profound immunomodulatory effects. One possible mechanism may be the inactivation of dendritic cells caused by suppressing the interaction between specialized antigen-presenting cells and lymphocytes. This may lead to reduced production of cytokines, such as IL2 and γ -interferon, upregulation of IL4, and induction of IL3, IL6 and tumour necrosis factor. However, the exact mode of action of bath-PUVA therapy remains unknown.

REFERENCES

- Piñol Aguadé J, De Asprer J, Ferrando J. Lichenoid trikeratosis (Kaposi-Bureau-Barrière-Grupper). *Dermatologica* 1974; 148: 179–188.
- Taberner R, Puig L, Fernandez-Figueras T, Alomar A. Keratosis lichenoides chronica. *J Eur Acad Dermatol Venereol* 2001; 15: 84–85.
- Baran R, Panizzon R, Goldberg L. The nails in keratosis lichenoides chronica. *Arch Dermatol* 1984; 120: 1471–1474.
- Kersey P, Ive FA. Keratosis lichenoides chronica is synonymous with lichen planus. *Clin Exp Dermatol* 1982; 7: 49–54.
- Menter MA, Morrison JGL. Lichen verrucosus et reticularis of Kaposi (porokeratosis striata of Nékam): a manifestation of acquired adult toxoplasmosis. *Br J Dermatol* 1976; 94: 645–654.
- David M, Filhaber A, Rotem A, Katzenelson-Weissman V, Sandbank M. Keratosis lichenoides chronica with prominent telangiectasia: Response to etretinate. *J Am Acad Dermatol* 1989; 21: 1112–1114.
- Schnitzler L, Bouteiller G, Bechetoille A, Verret JL. Kératose lichénoïde chronique avec atteinte muqueuse synéchiante sévère. Étude évolutive sur 18 ans. Thérapeutique per le rétinol aromatique. *Ann Dermatol Venereol* 1981; 108: 371–379.
- Grunwald MH, Hallel-Halevy D, Amichai B. Keratosis lichenoides chronica: response to topical calcipotriol. *J Am Acad Dermatol* 1997; 37: 263–264.
- Chang SE, Jung EC, Hong SM, Choi JH, Sung KJ, Moon KC, Koh JK. Keratosis lichenoides chronica: marked response to calcipotriol ointment. *J Dermatol* 2000; 27: 123–126.
- Wozniacka A, Schwartz RA, Omulecki A, Lesiak A, Sysa-Jedrzejowska A. Keratosis lichenoides chronica: a diagnostic and therapeutic challenge. *Clin Exp Dermatol* 2005; 31: 48–50.
- Ghislain PD, De Beir A, Creusy C, Modiano P. Keratosis lichenoides chronica: report of a new case, with success of PUVA therapy. *Dermatol Online* 2001; 7: 4.
- Douri T, Shawaf AZ. Keratosis lichenoides chronica: Report of a new case with partial response to PUVA therapy. *Dermatol Online* 2005; 11: 28.
- Demirci E, Boyvat A, Arica IE, Kocyigit P, Ozdemir E, Heper AO. Keratosis lichenoides chronica: marked response to PUVA in combination with acitretin. *Acta Derm Venereol* 2005; 85: 552–553.
- Duschet P, Schwarz T, Gschnait F. Chronic lichenoid keratosis. *Hautarzt* 1987; 38: 678–682.

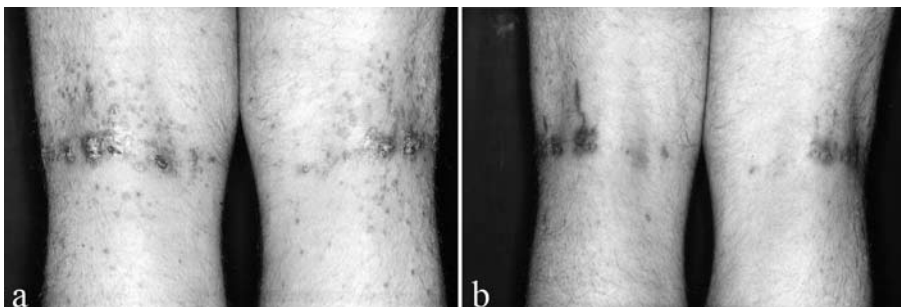


Fig. 3. Genicular fossa with keratotic papules and nodules in patient 2: (a) before and (b) during therapy.