

Extranodal NK/T-Cell Lymphoma Nasal Type Mimicking Pyoderma Gangrenosum

Yolanda Delgado-Jimenez¹, Silvia Perez-Gala¹, Syonghyun Nam-Cha², Maria Jones-Caballero¹, Javier Fraga², Amaro Garcia-Diez¹ and Jesús Fernandez-Herrera¹

Departments of ¹Dermatology and ²Pathology, Hospital de La Princesa, Diego de Leon 62, ES-28006 Madrid, Spain. E-mail: ydelgado@aedv.es
Accepted September 26, 2006.

Sir,

The new World Health Organization/European Organization for Research and Treatment of Cancer (WHO-EORTC) consensus classification for cutaneous lymphomas recognizes two main groups of CD56+ lymphomas: extranodal natural killer (NK)/T-cell lymphoma nasal type, and CD56+ haematodermic neoplasm (formerly known as blastic NK cell lymphoma (1).

NK/T-cell lymphoma nasal type is the most common lymphoma type among primary lymphomas of the nasal cavity (2). It presents clinically as a nasal mass and may involve the skin secondarily, where it often presents as a mid-facial destructive tumour or as multiple distant erythematous nodules, which can evolve to ulceration (3). There is a strong association with Epstein-Barr virus (4).

We report here a patient with an extranodal NK/T-cell lymphoma nasal type with cutaneous involvement, in which the clinical presentation mimicked pyoderma gangrenosum.

CASE REPORT

A 73-year-old Caucasian man was admitted due to a 3-week history of malaise, fever, swelling of the left eyelids and proptosis of the left eye. Laboratory tests revealed a white cell count of 16,000 with 70% of neutrophils, haemoglobin 10.1 g/dl, MCV-83 fl, platelets 59,000/mm³. A facial computed tomography (CT)-scan showed inflammation of the left maxillary sinus and a mass on the medial wall of the left orbit. A diagnosis of sinusitis and left orbital abscess was made. The patient received several courses of intravenous antibiotics without improving.

Ten days after admission, a dermatology referral was made due to a cutaneous lesion localized on the anterior abdominal wall, presenting since the beginning of the clinical picture. Examination revealed a 6 × 3 cm indurate purplish plaque, with several haemorrhagic bulla on the periphery and a necrotic crust on the centre, localized on the upper abdominal wall (Fig. 1a). On the upper chest and back multiple erythematous circinate

lesions, slightly infiltrated, were found (Fig. 1b). Clinically, he was thought to have a neutrophilic dermatosis coexisting with pyoderma gangrenosum and Sweet's syndrome. Two skin biopsies were taken from morphologically different lesions, one on the upper abdominal wall (purplish plaque with bullae) and the other on the upper thoracic wall (erythematous infiltrated plaque). Histology of the first biopsy showed a prominent necrotic epidermal necrosis, the epidermis appeared detached from the dermis at some points; the second biopsy evidenced marked basal cell vacuolar changes with necrotic keratinocytes. Both biopsies showed the dermis diffusely infiltrated by a mixture of small- to medium-sized, pleomorphic atypical lymphoid cells with prominent dermal necrosis, acquiring occasionally an angiocentric disposition (Fig. 2). Frequent mitoses were observed as well as some apoptotic cells. Immunophenotypically cells were CD56+, CD3 epsilon+, (Fig. 3a and b), granzyme B+, CD20- and myeloperoxidase-. *In situ* hybridization for Epstein-Barr virus (EBV) using the probe EBER was positive (Fig. 3c). No clonal rearrangement of the T-cell receptor was detected by polymerase chain reaction (PCR), performed according to standard procedures described previously (5). Bone marrow biopsy and CT examination of the neck, chest and abdomen showed no abnormalities except for alveolo-interstitial pulmonary infiltrates, interpreted as heart failure, and left cervical pathological lymph nodes.

With the diagnosis of NK/T-cell lymphoma nasal type, chemotherapy with cyclophosphamide, doxorubicin, vincristine and prednisone (CHOP) was started, but the patient died 24 h later due to multiple organ failure.

DISCUSSION

Cutaneous lymphomas expressing a NK-cell phenotype represent a rare type of lymphoproliferative disorder.

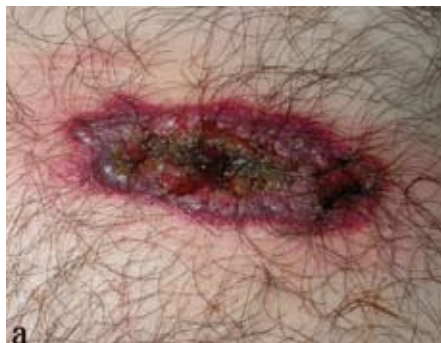
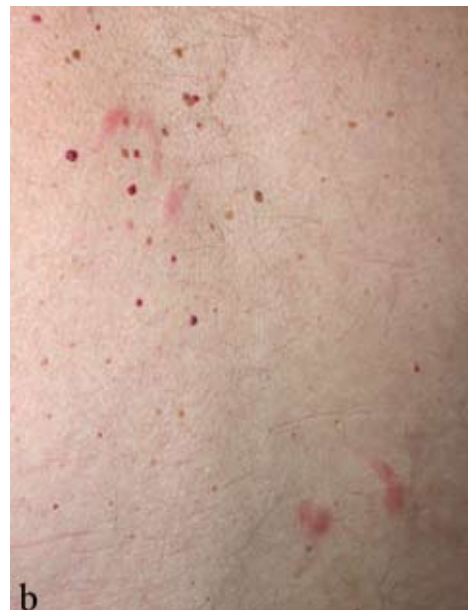
Fig. 1. (a) Purplish plaque on the abdominal wall, showing several bullae on the periphery and an adherent crust on the centre. (b) Erythematous infiltrated circinate lesions on the back.



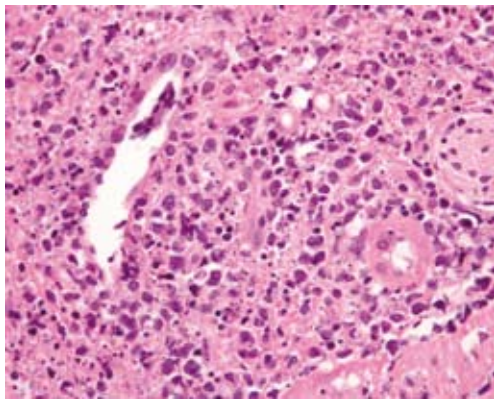


Fig. 2. Atypical lymphoid cells with an angiocentric disposition.

ders, especially in Western countries. This extreme rarity represents a major limitation to a complete understanding and a comprehensive classification of these entities (6). NK/T-cell lymphoma nasal type is recognized as distinct disorder with characteristic clinical presentation, histopathology, immunophenotype and relation with EBV (4, 7).

Clinical presentation of cutaneous lymphomas is non-specific. Usually present as a single or multiple nodules or tumours that persist and progress over time. There are reports in which, as in our case, the clinical onset was as ulcer-necrotic lesions, with bulla formation that clinically resembled pyoderma gangrenosum. These cases include different types of lymphomas: mycosis fungoides (8, 9), primary cutaneous B-cell lymphoma (10) and CD8+ cutaneous T-cell lymphoma (11). In our case, the histological findings could explain that the lesions were misdiagnosed as neutrophilic dermatoses. The ulcer-necrotic lesions showed a prominent epidermal necrosis with dermal-epidermal detachment, similar to that found in ulcerative lesions of pyoderma gangrenosum, and the circinated plaques did not show distinctive clinical characteristics.

NK/T-cell lymphoma nasal type is associated with an aggressive clinical course and a poor prognosis (1), with a median survival of approximately 1 year after diagnosis despite chemotherapy and radiation therapy.

However, we have some anecdotal reports of an unusually prolonged survival of up to 38 years (12).

REFERENCES

1. Willemze R, Jaffe ES, Burg G, Cerroni L, Berti E, Swerdlow SH, et al. WHO-EORTC classification for cutaneous lymphomas. *Blood* 2005; 105: 3768–3785.
2. Siu LLP, Chan JKC, Kwong YL. Natural killer cells malignancies: clinicopathologic and molecular features. *Histol Histopathol* 2002; 17: 539–554.
3. Cho KH, Choi WW, Youn CS, Kim CW, Heo DS. Skin is the frequent site for involvement of peripheral T-cell and natural killer cell lymphomas in Korea. *J Dermatol* 2000; 27: 500–507.
4. Ng BS, Lai KW, Murugaya S, Lee KM, Loong SL, Fook-Chong S, et al. Nasal-type extranodal natural killer/T cell lymphomas: a clinicopathologic and genotypic study of 42 cases in Singapore. *Modern Pathology* 2004; 17: 1097–1107.
5. Trainor KJ, Brisco MJ, Wan JH, Neoh S, Grist S, Morley AA. Gene rearrangement in B- and T-lymphoproliferative disease detected by the polymerase chain reaction. *Blood* 1991; 78: 192–196.
6. Santucci M, Pimpinelli N, Massi D, Kadin ME, Meijer CJ, Muller-Hermelink HK, et al. Cytotoxic/natural killer cell cutaneous lymphomas. Report of the EORTC cutaneous lymphoma task force workshop. *Cancer* 2003; 97: 610–627.
7. Gniadecki R, Rossen K, Ralfkier E, Thomsen K, Skovgaard GL, Jonsson V. CD56 lymphoma with skin involvement. Clinicopathologic features and classification. *Arch Dermatol* 2004; 140: 427–436.
8. Ho KK-L, Browne A, Fitzgibbons J, Carney D, Powell FC. Mycosis fungoides bullosa simulating pyoderma gangrenosum. *Br J Dermatol* 2000; 142: 124–127.
9. Carbia SG, Hochman A, Chain M, Dei-Cas I, Lagodin C, Deves A, et al. Mycosis fungoides presenting with extensive pyoderma gangrenosum-like ulcers. *J Eur Acad Derm Venereol* 2002; 16: 401–404.
10. Lami MC, Vabres P, Dreyfus B, Germain T, Guillet G. Primary cutaneous B-cell lymphoma mimicking pyoderma gangrenosum: first-line treatment with rituximab. *Br J Dermatol* 2004; 151: 250–252.
11. Farrar CW, Jack AS, Lyon C, Cowan RA, Griffiths CE, Ashworth J. A 62-year-old man presenting with widespread nodulo-ulcerative cutaneous lesions. *Clin Exp Dermatol* 2001; 26: 115–119.
12. Schrader C, Janssen D, Kneba M, Lennert K. A 38-year history of natural-killer-cell lymphoma. *N Engl J Med* 2004; 350: 418–419.

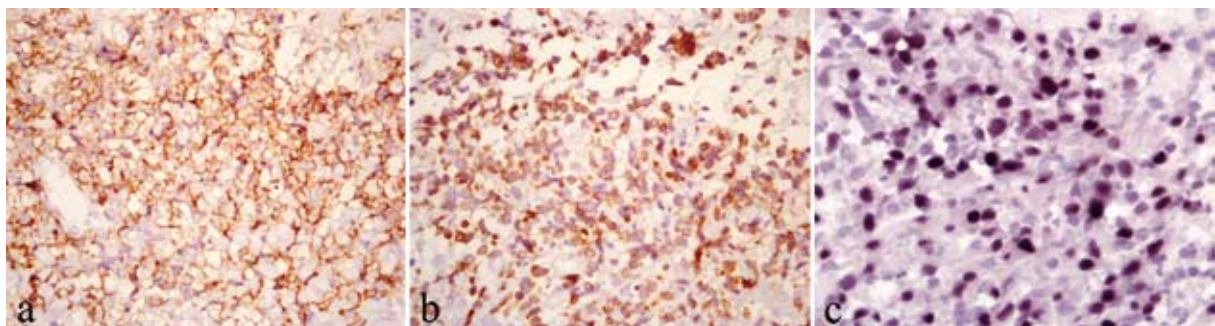


Fig. 3. Immunohistochemically the cells were positive for (a) CD56 and (b) CD3 epsilon using brown chromogen diaminobenzidine. (c) *In situ* hybridization for Epstein-Barr virus (EBV) using the probe EBER was positive.