

## Gianotti-Crosti Syndrome after Hepatitis A Vaccination

Alexandra Monastirli<sup>1</sup>, Anastassia Varvarigou<sup>2</sup>, Efi Pasmatzli<sup>1</sup>, George Badavanis<sup>1</sup>, Sophia Georgiou<sup>1</sup>, Stefanos Mantagos<sup>2</sup> and Dionysios Tsambaos<sup>1</sup>

Departments of <sup>1</sup>Dermatology and <sup>2</sup>Pediatrics, School of Medicine, University of Patras, PO Box 1413, Rio-Patras GR-26504, Greece.

E-mail: almonast@med.upatras.gr

Accepted July 27, 2006.

Sir,

Gianotti-Crosti syndrome (GCS) is a relatively common skin disorder characterized by a distinctive, self-limiting, non-recurrent erythematous or skin-coloured papulovesicular eruption symmetrically distributed mainly on the extremities, buttocks and face of infants and young children and, infrequently, of adults. A wide spectrum of infectious agents, mostly viruses [hepatitis A, B and C, cytomegalovirus (CMV), Epstein-Barr, HIV, human herpes virus 6, Coxsackie, rota-, echo- and parvovirus, parainfluenza, mumps, *Molluscum contagiosum*, respiratory syncytial virus] and bacteria (*Borrelia burgdorferi*, *Bartonella henselae*,  $\beta$ -haemolytic streptococci, *Mycoplasma pneumoniae*), as well as preceding immunizations, have been associated with this syndrome (1). We report here a case of GCS that occurred in a 3-year-old boy 3 days after hepatitis A vaccination.

### CASE REPORT

A previously healthy 3-year-old boy was referred to the Department of Dermatology for a pruritic cutaneous eruption that had developed 3 days after vaccination against hepatitis A (Havrix Vaccine<sup>®</sup>, 0.5 ml/720 IU; GlaxoSmithKline Biologicals, Rixensart, Belgium) performed 4 weeks prior to his presentation. Eighteen to 24 months prior to admission the patient had been vaccinated against polio, diphtheria, tetanus, measles, mumps, rubella and Haemophilus influenzae B without any cutaneous complications. He had taken no medication and had no evidence or family history of atopy. On physical examination he appeared healthy, with normal growth and development. There was no fever, malaise or signs of infection from the respiratory and the genitourinary tract. The patient revealed a symmetrical eruption consisting of flesh-coloured firm 2–4 mm papules and papulovesicles on the extremities (Fig. 1), the buttocks and, to a lesser extent, on the trunk. Over the elbows, the buttocks and the knees, several lesions coalesced into plaques. There was a concomitant cervical, axillary and inguinal lymphadenopathy in the shape of small (< 1 cm), painless and mobile nodes. No target- or iris-like lesions, swelling, palmoplantar desquamation, erythema, conjunctival infection, mucosal or perianal involvement or hepatosplenomegaly were present. Routine blood tests including full blood count and biochemical profile were normal. Micro-

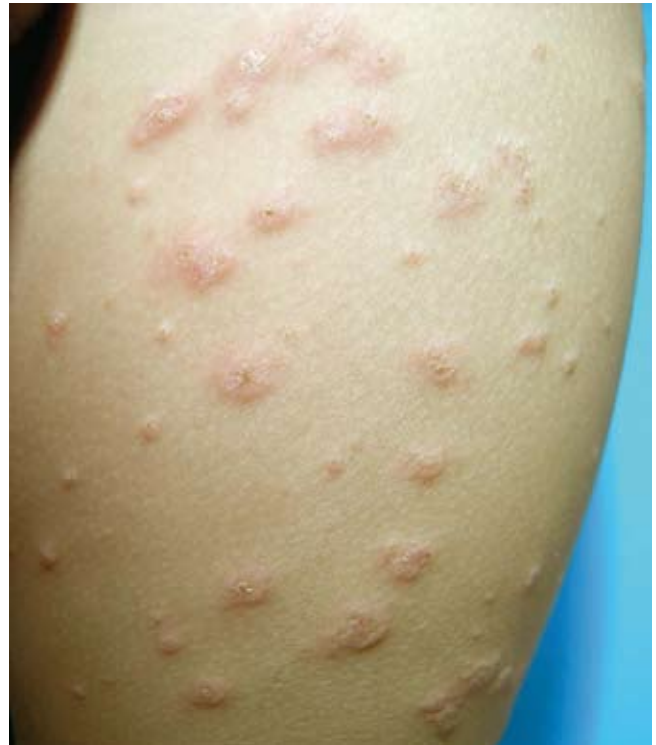

Fig. 1. Clinical aspect of the patient's eruption.

biological investigations of throat swabs and stool samples were negative. Serological tests for hepatitis B and C, Epstein-Barr virus, HIV, CMV, parvovirus-B19, Coxsackie A and B, parainfluenza virus, herpes simplex and zoster virus, respiratory syncytial virus, *Borrelia burgdorferi*, *Mycoplasma pneumoniae* and beta-haemolytic streptococci were negative. A clinical diagnosis of GCS was made. Histopathological examination of a biopsy from lesional skin revealed the features of a lichenoid dermatitis characterized by hyperkeratosis, focal parakeratosis and spongiosis, several dyskeratotic/apoptotic keratinocytes, focal vacuolization of basal keratinocytes and a moderate lichenoid lymphohistiocytic infiltrate (Fig. 2). On immunohistochemistry, large numbers of CD1-positive Langerhans' cells were found within the epidermis and in the papillary dermis; the vast majority of the other mononuclear cell components of the inflammatory infiltrate were CD3- and CD8-positive. The patient was treated with oral antihistamines and his eruption cleared within 3 weeks.

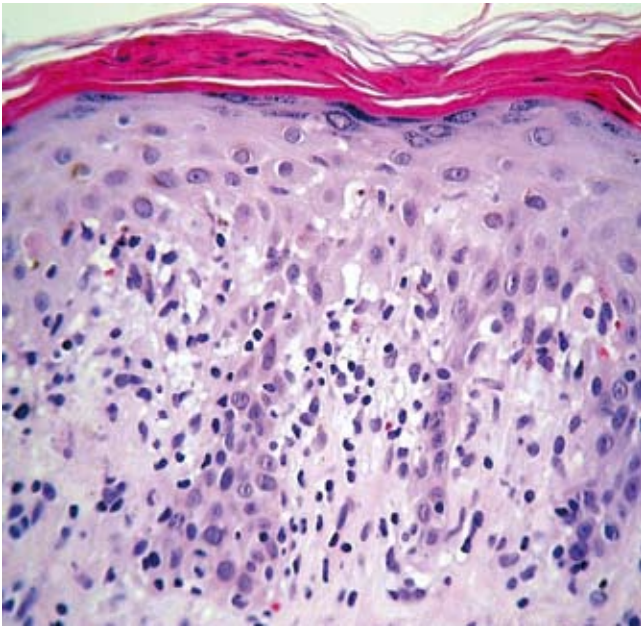


Fig. 2. Focal parakeratosis and spongiosis, vacuolization of basal keratinocytes, papillary oedema and lymphohistiocytic infiltrate (H&E  $\times 400$ ).

## DISCUSSION

This case fulfils all positive clinical criteria proposed by Chuh (2) for the diagnosis of GCS, whereas the involvement of the patient's trunk at a clearly lesser extent cannot be regarded as a negative clinical feature (3). Moreover, although the histopathological findings in GCS are non-specific, the histological pattern of a lichenoid dermatitis found in our case has been described in GCS previously (4). Additionally, the combination of the lichenoid pattern and the intra-epidermal and dermal clusters of Langerhans' cells observed in our study reveals a striking similarity to that of the case reported

by Stefanato et al. (5) and suggests that a type IV hypersensitivity response to viral or bacterial antigens may be involved in the pathogenesis of this disorder.

Apart from local erythematous reactions, the cutaneous side-effects of hepatitis A vaccine Havrix<sup>®</sup> are rare and include pruritus, urticaria, angioedema, erythema multiforme and hyperhidrosis. A considerable number of vaccines or combinations of vaccines have been linked to GCS. Among them a combined hepatitis A/hepatitis B has been documented as preceding GCS in two cases (6, 7). However, to the best of our knowledge, GCS has not previously been associated with the hepatitis A vaccine alone. Although a coincidence between the vaccination and the patient's eruption cannot be definitely ruled out, it seems reasonable to suggest that hepatitis A vaccine alone probably represents the causally relevant factor of GCS in our patient, in view of the temporal sequence of events and the absence of any other precipitants.

## REFERENCES

1. Tilly JJ, Drolet BA, Esterly NB. Lichenoid eruptions in children. *J Am Acad Dermatol* 2004; 51: 606–624.
2. Chuh AAT. Diagnostic criteria for Gianotti-Crosti syndrome - a prospective case control study for validity assessment. *Cutis* 2001; 68: 207–213.
3. Chuh AAT. Truncal lesions do not exclude a diagnosis of Gianotti-Crosti syndrome. *Australas J Dermatol* 2003; 44: 215–216.
4. Winkelmann RK, Bourlond A. Infantile lichenoid acrodermatitis: report of a case of Gianotti-Crosti syndrome. *Arch Dermatol* 1965; 92: 398–401.
5. Stefanato CM, Goldberg LJ, Andersen WK, Bhawan J. Gianotti-Crosti syndrome presenting as lichenoid dermatitis. *Am J Dermatopathol* 2000; 22: 162–165.
6. Haug S, Schnopp C, Ring J, Folster-Holst R, Abeck D. Gianotti-Crosti syndrome following immunization. *Hautarzt* 2002; 53: 683–685.
7. Brandt O, Abeck D, Gianotti R, Burgdorf W. Gianotti-Crosti syndrome. *J Am Acad Dermatol* 2006; 54: 136–145.