

## Long-lasting Scrofuloderma of Hands and Foot

Özlem Karabudak, Bilal Dogan and Yavuz Harmanyeri

GATA Haydarpaşa Teaching Hospital, Department of Dermatology and Venereology, Istanbul, Turkey. E-mail: okarabudak@yahoo.com

Accepted June 8, 2006.

Sir,

Cutaneous tuberculosis is a part of the small percentage of extrapulmonary forms of tuberculosis (TB). It is caused by *Mycobacterium tuberculosis* and *M. Bovis*, and under certain conditions, bacillus Calmette-Guerin (BCG), an attenuated form of *M. bovis* (1, 2). Scrofuloderma is one of the most common form of cutaneous TB. It results from an underlying focus, such as lymph node, bone, joint and/or the subcutaneous tissues with formation of cold abscess and a secondary breakdown of the overlying skin (3, 4). Here we present an unusual case of scrofuloderma in both hands and the left foot.

### CASE REPORT

A 20-year-old man presented to our clinic with multiple, long-standing, painless erythematous plaques on the hands and left foot, which had resulted in atrophic scarring. There was some oozing areas on the lesions. The patient's history revealed that a purulent skin lesion had developed on the back of his right hand following a mole bite 6 years ago, and this was followed by the development of many plaques on the back of the other hand and left foot over a period of 5 years. The lesions persisted despite the use of various antibiotics. He described similar lesions on the hands of his sister, but examination was not possible because she was living in another city.

On dermatological examination, he had multiple infiltrated erythematous plaques covered by thin scales on his hands (Fig. 1a) and on the medial aspect of his left foot. He was afebrile, and there was no lymphadenopathy. Sputum, stool, and urine cultures were negative. Tuberculin skin test was positive with erythema and induration of 20 mm after 48 h. A complete blood count, hepatic and renal function analyses results were within normal limits. Results of acid-fast staining, atypical mycobacterial and routine fungal cultures, polymerase chain reaction were all negative. Venereal disease research laboratory (VDRL), Treponema pallidum haemagglutination assay (TPHA), anti-human immunodeficiency virus (HIV), anti-hepatitis C virus, HBsAg, IgG, IgA, IgM, C-reactive protein, rheumatoid factor and antistreptolysin O tests were all negative. The patient was immunocompetent. A non-homogenous infiltration was detected on chest X-ray. Thorax computerized tomography (CT) showed interseptal thickening, infiltration in the right upper and mid-zones and bronchiectasia, suggestive of pneumonia.

No improvement was observed in control thorax CT after the dual antibiotic treatment (cefuroxime axetyl 500 mg 2×1 and clarithromycin 500 mg 2×1 /10 days). Articular bone deformities (first metacarpophalangeal (MCP) of the right hand, first and fifth MCP of the left hand, and first metatarsophalangeal of the left foot) as a result of osteomyelitis were detected by X-ray (Figs 1c and e).

Histopathology of a skin biopsy showed a normal epidermis overlying non-caseating granuloma, composed of centrally located epithelioid cells surrounded by lymphocytes and Langerhan's giant cells in the papillary and upper reticular dermis. Ziehl-Nielsen and periodic acid-Schiff stains did not demonstrate acid-fast bacilli.

The diagnosis of scrofuloderma was established in our patient mainly on clinical findings and, partly by histopathology and result of the Mantoux test. Laboratory findings also allowed us to rule out a deep mycotic infection (negative cultures of fungi), tertiary syphilis (negative serologic titres) and atypical mycobacteriosis.

The patient was treated with pyrazinamide 2500 mg/day, isoniazid 300 mg/day, rifampin 600 mg/day, and ethambutol 1500 mg/day daily for 2 months, followed by dual therapy with isoniazid and rifampin in the same dosages for additional 4 months. Great improvement was obtained within 4 months of starting treatment. The lesions were healed almost completely by the sixth month of treatment with scar formation (Fig. 1b and d). The diagnosis was also supported by this rapid response to anti-tuberculous therapy. Post-treatment thorax CT showed multiple fibrosis as a sequelae, instead of the bronchiectasia observed before. No relapse was detected in the post-treatment follow-up period in the next 6 months.

### DISCUSSION

TB is one of the top six infectious diseases declared to be dangerous by the World Health Organization. It is a serious public health problem in developing countries (5). Along with the increased frequency of pulmonary TB, there is also disproportionately increased rate of extrapulmonary TB, and among the cases of extrapulmonary TB, the incidence of osteoarticular TB has also increased. TB arthritis occurs primarily in weight-bearing joints such as hips. Among non-weight-bearing joints, the most commonly involved, in descending order, are: elbows, wrists, joints in the hands (dactylitis), and shoulders. Osteoarticular TB primarily spread from

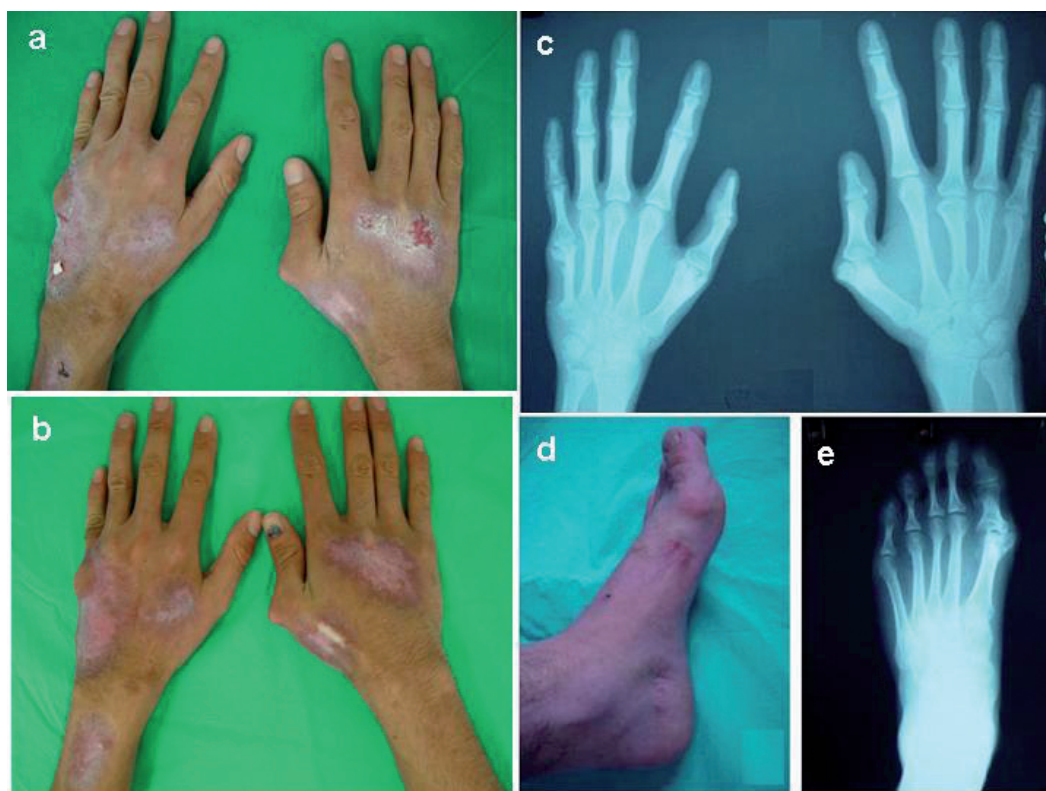


Fig. 1. (a) Pre-treatment hands; (b) post-treatment hands; (c) X-ray of hands; (d) post-treatment left foot; (e) X-ray of left foot.

a primary focus lympho-hematogeneously. It can also occur, infrequently, by contiguous spread from adjacent tissues or direct inoculation (6).

Although the progression of the disease in our patient is not clear, it can be speculated that these lesions of the skin were acquired either exogenously, by direct inoculation of bacilli secondary to injuries from a mole bite, or endogenously, by haematogeneous or lymphatic spread from an underlying pulmonary focus. Normally tubercle bacilli do not penetrate intact skin, but the inoculation with injury is well known. We think that the TB possibly spread into the bone by direct inoculation of bacilli following a mole bite. But it could also represent autoinoculation by infected sputum from an underlying asymptomatic pulmonary TB in the family because of the history of similar lesions on the hands of his sister. As another possibility, because his pneumonia recovered with the anti-TB therapy, there could be a lympho-haematogeneous spread from a pulmonary focus.

Some cases of TB cutis verrucosa and metastatic abscess localized on the hand have been reported (7–9). However, only one case of scrofuloderma localized on one hand has been reported previously, by Aliagaoglu et al. (10).

## REFERENCES

1. Tappeiner G, Wolff K. Tuberculosis and other mycobacterial infections. In: Freedberg IM, Austen Patrick TB, Eisen AZ, Wolff K, Austen KF, Goldsmith LA, et al., eds. *Dermatology in general medicine*. 5th edn. New York: Mc Graw-Hill, 1999: p. 2274–2292.
2. Atasoy M, Aliagaoglu C, Erdem E, Ozdemir S, Aktas A. Scrofuloderma after BCG vaccination. *Pediatr Dermatol* 2005; 22: 179–180.
3. Tan H, Karakuzu A, Arik A. Scrofuloderma after BCG vaccination. *Pediatr Dermatol* 2002; 19: 323–325.
4. Burgin S, Pomeranz MK, Orbuch P, Shupack LJ, Brand RS. Mycobacteria and the skin. In: Rom WN, Garay SM eds. *Tuberculosis*. 2nd edn. Philadelphia: Lippincott Williams & Wilkins, 2004: p. 593–608.
5. Bhutto AM, Solangi A, Khaskhely NM, Arakaki H, Nonaka S. Clinical and epidemiological observations of cutaneous tuberculosis in Larnaka, Pakistan. *Int J Dermatol* 1999; 41: 159–165.
6. Kramer BS, Lee SHS, Abramson BS. Nonvertebral infections of musculoskeletal system by mycobacterium tuberculosis. In: Rom WN, Garay SM eds. *Tuberculosis*. 2nd edn. Philadelphia: Lippincott Williams & Wilkins, 2004: p. 577–591.
7. Petit A, Maslo C, Herschkovitch D, Perrin P, Janier M, Civatte J. Multiple subcutaneous abscesses due to *Mycobacterium tuberculosis* in an immunocompetent host. *Dermatologica* 1989; 179: 207–210.
8. Tosti G, Bettoli V, Virgili A, Rossi MR, Altieri E. A long lasting verrucous plaque on the hand revealed as tuberculosis cutis. *Acta Derm Venereol* 2002; 81: 448–449.
9. Hernandez-Martin A, Fernandez-Lopez E, Roman C, Unamuno P, Armijo M. Verrucous plaque on the back of a hand. *Cutis* 1997; 60: 235–236.
10. Aliagaoglu C, Atasoy M, Sahin O, Onbas O, Kaynar H, Balik O, Kabalar E. A long lasting scrofuloderma on the back of the right hand. *J Dermatol* 2005; 32: 227–229.